

Case Report

“Sacrificing a tooth not always an option”; instrument retrieval from calcified central incisor – A case report.

¹Dr Deepyanti, ²Dr Rajdeep Mitra, ³Dr Surekha Puri, ⁴Dr Deepak Kurup, ⁵Dr Tapan Kumar Mandal, ⁶Dr Juhi Anand

¹Post graduate, Hazaribag College of Dental Sciences and Hospital;

²Post graduate, Hazaribag College of Dental Sciences and Hospital;

³Professor & HOD, Hazaribag College of Dental Sciences and Hospital;

⁴Associate Professor, Hazaribag College of Dental Sciences and Hospital;

^{5,6}MDS, Hazaribag College of Dental Sciences and Hospital

ABSTRACT:

A 25-year-old male patient was referred to our Hazaribag College of Dental Sciences and Hospital in the Department of Conservative Dentistry and Endodontics with a chief complaint of pain in maxillary left central incisor. Mild pain was seen with respect to 21. The patient was referred for the management of separated endodontic file from a calcified canal. The referring dentist gave a history of separation of 15 no k file in the central incisor 2 days ago. IOPA radiographs were taken to confirm the fractured fragment in the canal.

Key words: Instrument retrieval, Instrument separation, NITI Files, ultrasonic tips

Received: 8 April, 2021

Accepted: 2 May, 2021

Corresponding Author: Dr Deepyanti, Post graduate, Hazaribag College of Dental Sciences and Hospital

This article may be cited as: Deepyanti, Mitra R, Puri S, Kurup D, Mandal TK, Anand J. “Sacrificing a tooth not always an option”; instrument retrieval from calcified central incisor – A case report. J Adv Med Dent Scie Res 2021;9(5):32-34.

INTRODUCTION

A clinician can face a variety of procedural problems during endodontic treatments. These include formation of ledges, strip perforations, or separation of instruments in the canals.^[1] The introduction of nickel–titanium (NiTi) instruments has revolutionized the way we shape the canal system. Despite the various advantages and increased use of NiTi instruments, the chances of procedural mishaps are much greater (1.3% and 10.0%, respectively) than that those of stainless steel instruments (0.25% and 6%, respectively).^[2] Improper use, inadequately extended access cavities, unpredictable root canal anatomy, and very rarely manufacturing defects are the most common causes of instrument separation.^[3] The separated fragment hinders through cleaning and shaping of canals beyond the separated fragment and adversely affect the prognosis of the case. Over

the past decade, there has been a significant rise in the use of rotary endodontic files and with this the abstract instrument separation is a very common mishap in routine endodontic practice. Although fractured fragment does not affect the prognosis of the case, it may affect the subsequent steps in endodontic therapy, such as chemo mechanical preparation, obturating root canals. In case of separated instrument, attempts should be made to retrieve the instrument where possible or one should try to bypass the fragment. This case report describes the retrieval of a separated instrument from central incisor of 25-year-old boy.

CASE REPORT

Instrument Retrieval from Central Incisor was seen with respect to 21. The patient was informed about the

separated instrument and the prognosis of the tooth and consent was taken (FIGURE – 1).

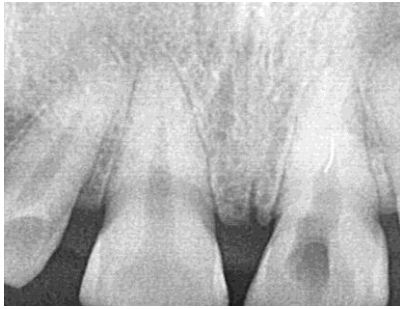

FIGURE 1- Pre operative radiograph of tooth with fractured file segment.

Routine endodontic treatment with instrument retrieval was planned for the patient. After complete history taking, local anaesthesia was administered to the patient. The concerned tooth 21 was isolated using rubber dam. The temporary filling material was removed. Starting with an ISO # 8 K-file, and attempt was made to bypass the instrument at working length. Progressively, ISO # 8, no d finer (Mani Co. In), 8 no c plus file (DENTSPLY)files were used (FIGURE -2).

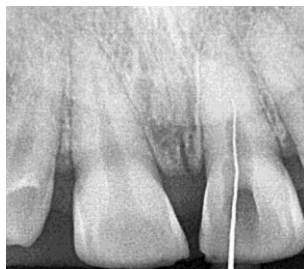

FIGURE 2 – Trying to bypass the fracture file.

The calcified canal was negotiated with 8 No, 10 no C plus file and 12 no 1% neoprobe file subsequently 15 no file (Mani.Co. In) was used till working length. Then rotary instrument NT GOLD FILE SYSTEM (NEO ENDO) was used. The files were used along with ethylenediaminetetraacetic acid (EDTA) gel and copious irrigation of 3% sodium hypochlorite. At every step, apex locator (Canal Pro; Coltene) was used to check if the file had been bypassed and if the apex was reached. Once the file had been bypassed and apex was reached, a confirmatory radiograph was taken. Working length was measured to be 20 mm (FIGURE – 4).

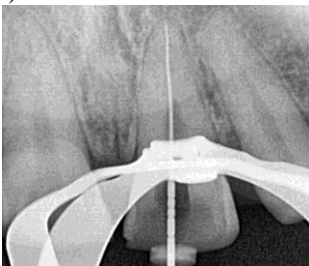


FIGURE 4- Working length measured after file retrieval.

Subsequent biomechanical preparation was done using progressive files along with EDTA and sodium hypochlorite for irrigation days. Calcium hydroxide dressing was placed for 7 days. No pain was observed after 7 days. After removing the temporary filling, the calcium hydroxide dressing was removed from the canal of the tooth and the canals were thoroughly irrigated. After biomechanical preparation up to 25/6, the separated fragment became little loose in the canal. Ultrasonic GOLDEN tips (ORIKAM) were used to loosen it further and then irrigated it thoroughly to retrieve the fragment. RVG was taken to confirm the complete retrieval (Figures 3).

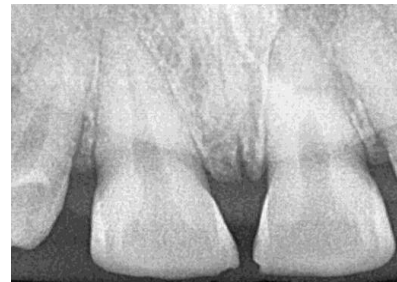

FIGURE 3 – Radiograph taken after file retrieval

After the retrieval, through irrigation with 3% Sodium Hypochlorite was done. Master cone selection was done (Figure- 5).

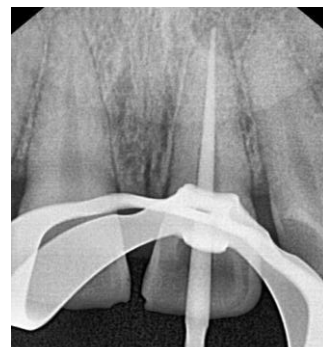

FIGURE 5 – Mastercone selection done

Canals were dried with paper points and obturated using Cold Lateral Compaction Technique using AH PLUS sealer. (Figure 6).

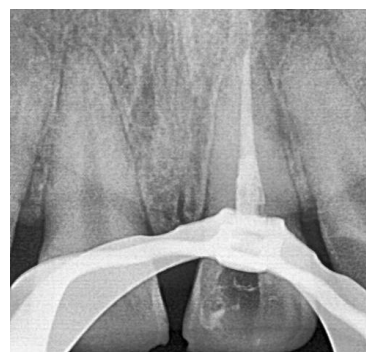

FIGURE 6 – Obturation after file retrieval

The patient was then kept under recall.

DISCUSSION

Fracture of an endodontic instrument is one of the most common procedural errors. There are various factors that contribute to fracture of endodontic files, of which a few are listed below:^[6]

1. Operator's skill – inadequate access cavity preparation, failure to achieve glide path, and improper instrumentation technique 2. Dynamics of instrument use – torque, rotational speed, engine driven or hand driven 3. Root canal anatomy or morphology 4. Fatigue of instrument and overuse. Every case of endodontic instrument fracture creates dilemma for the operator, whether to bypass or remove the fragment. Furthermore, it is important to stress the need for additional armamentarium that is required for instrument retrieval which includes microscope, ultrasonic endodontic tips, and special endodontic instrument retrieval kits.

A few factors that should be considered in management of fracture endodontic instrument;

(1) length of the fragment, (2) location of fractured fragment - beyond the apex, near apex, mid root (3) Root curvature, length, thickness. The fracture of endodontic instrument is unpredictable but few precautions that one should take to reduce the risk of fracture,^[7] 1. Access cavity preparation should be adequate for visual access 2. Choosing the right armamentarium based on the instrumentation technique 3. Establish a glide path and a straight-line access to reduce flexion of files and resistance at multiple points 4. Follow the recommended torque values.

Every case of endodontic instrument fracture creates dilemma for the operator, whether to bypass or remove the fragment. Furthermore, it is important to stress the need for additional armamentarium that is required for instrument retrieval which includes microscope, ultrasonic endodontic tips, and special endodontic instrument retrieval kits. All the devices, techniques, and methods vary in their effectiveness, cost, and mechanism of action. Hence, before a final treatment plan is designed, it is advisable to weigh the advantages and disadvantages for the success of the treatment. Sometimes, the clinician may have to

consider other factors such as periodontal status of the tooth, periapical lesion, additional financial expense, patient's anxiety related to a broken instrument in the tooth, and a potential medico legal scenario.

A few factors that should be considered in management of fracture endodontic instrument; (1)length of the fragment, (2) location of fractured fragment - beyond the apex, near apex, mid root (3) Root curvature, length, thickness. The fracture of endodontic instrument is unpredictable but few precautions that one should take to reduce the risk of fracture,^[7] 1. Access cavity preparation should be adequate for visual access 2. Choosing the right armamentarium based on the instrumentation technique 3. Establish a glide path and a straight-line access to reduce flexion of files and resistance at multiple points 4. Follow the recommended torque values.

CONFLICTS OF INTEREST – There is no conflicts of interest.

REFERENCES

1. Souter NJ, Messer HH. Complications associated with fractured file removal using an ultrasonic technique. *J Endod* 2005; 31:450-2.
2. Shen Y, Peng B, Cheung GS. Factors associated with the removal of fractured niTi instruments from root canal systems. *Oral Surg Oral Med Oral Pathol Oral Radiol Endod* 2004; 98:605-10.
3. Roda RS, Gettleman BH. Nonsurgical retreatment. In: Roda RS, Gettleman BH, editors. *Pathways of the Pulp*. 9th ed. St. Louis: CV Mosby; 2006. p. 982-90.
4. Terauchi Y, O'Leary L, Suda H. Removal of separated files from root canals with a new file-removal system: Case reports. *J Endod* 2006; 32:789-97.
5. Andrabi SM, Kumar A, Iftekhhar H, Alam S. Retrieval of a separated nickel titanium instrument using a modified 18-guage needle and cyanoacrylate glue: A case report. *Restor Dent Endod* 2013; 38:93-7.
6. McGuigan MB, Loucal C, Duncan HF. Endodontic instrument fracture: Causes and prevention. *Br Dent J* 2013; 214:341-8.
7. Tang WR, Smales JR, Chen HF, Guo XY, Si HY, Gao LM, et al. Prevention and management of fractured instruments in endodontic treatment. *World J Surg Proced* 2015; 5:82-98.