

## Case Report

### Case Report of Trichoepithelioma over Eyelid

Sonal Gowaikar<sup>1</sup>, Ankita Chavan<sup>2</sup>, Milind Sabnis<sup>3</sup>

<sup>1</sup>Senior Resident, <sup>2</sup>Resident, <sup>3</sup>Prof and HOD, Dept of Ophthalmology, DR D Y Patil Hospital and Research Institute, Kolhapur, Maharashtra, India

#### **ABSTRACT:**

Solitary trichoepithelioma of the eyelid is a very rare tumor, which needs to be differentiated from basal cell carcinoma. Diagnosis is based on clinical and histopathological examination. We present a case of a solitary right upper eyelid trichoepithelioma along with its clinical and histopathological feature eyelid

**Key words:** Eyelid, hair follicle, trichoepithelioma, tumor.

Received: 20 November 2017

Revised: 30 December 2017

Accepted: 2 January 2018

**Corresponding Author:** Dr. Sonal Gowaikar, Senior Resident, Dept of Ophthalmology, DR D Y Patil Hospital and Research Institute, Kolhapur, Maharashtra, India

**This article may be cited as:** Gowaikar S, Chavan A, Sabnis M. Case Report of Trichoepithelioma over Eyelid. J Adv Med Dent Scie Res 2018;6(2):22-24.

#### **I**NTRODUCTION

Trichoepithelioma is a neoplasm of adnexa of the skin. These skin lesions originate from benign proliferation of epithelial-mesenchymal cells. These tumours are small (usually less than one centimeter diameter), firm and rounded. Trichoepithelioma may be divided into the multiple familial, Solitary and desmoplastic trichoepithelioma.<sup>1</sup> Due to its autosomal dominant trait, both genders receive the gene equally but more commonly seen in females. The gene for the development of familial trichoepithelioma encodes a tumor suppressor and links to the short arm of chromosome 9. Individual lesions may be confused clinically and pathologically with basal cell carcinoma. In histopathology, Trichoepithelioma shows Basaloid cells that form primitive hair follicle-germ structures with fibromyxoid stroma but in basal cell carcinoma there is a Basaloid cells with scant cytoplasm and elongated hyperchromatic nuclei, peripheral palisading, peritumoral clefting and mucinous alteration of surrounding stroma.<sup>2-5</sup> The diagnosis is often only made by pathology after removing the lesion surgically.

#### **CASE REPORT**

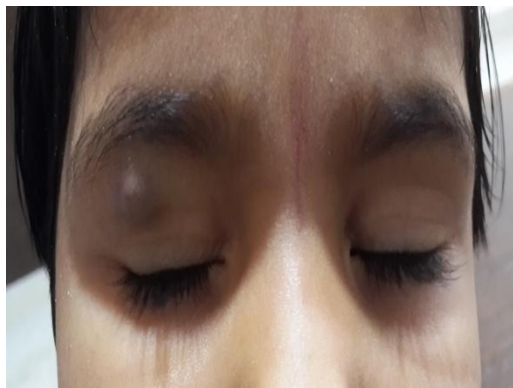A 4 years old female child brought by mother, who is a resident of Kolhapur came to ophthalmology OPD in Dr D.Y.Patil Medical College Hospital and Research Institute, Kolhapur.

As per history narrated by mother, the child had mass over right upper eyelid since 3 months which was associated with pain and gradually progressive in nature.

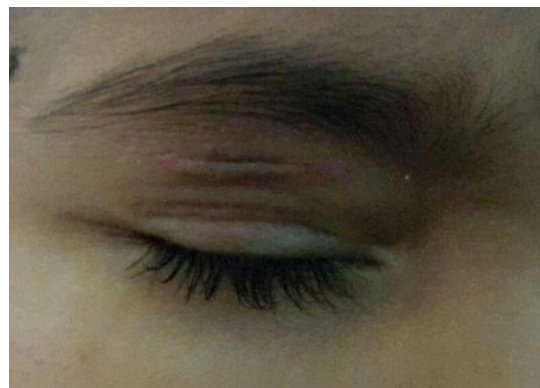She had no traumatic history or no similar complaints in past, neither of her family members had similar complaints.

On examination she had a firm, mobile, tender lesion of 5mm × 5mm × 6mm dimension attached to the overlying skin but not attached to underlying tissue, over lateral 2/3<sup>rd</sup> of right upper eyelid which had bluish-black discoloration of overlying skin. Her rest ocular examination was normal and her unaided vision was 6/6 in both eyes.

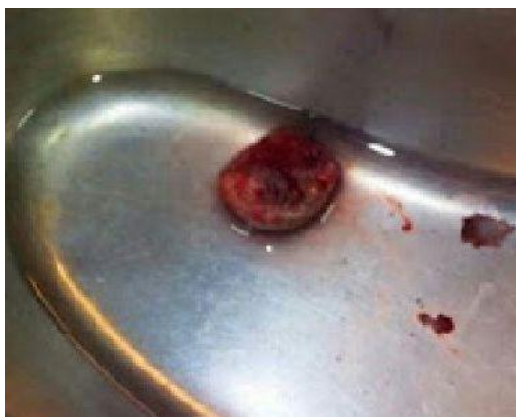Patient underwent excisional biopsy of the lesion under general anesthesia. The mass was removed along with its capsule and adjacent normal tissue. Histopathological report showed tissue lined by stratified squamous keratinized epithelium, below which seen a sheets of basaloid squamous epithelial cells merged with sheets of ghost squamous cells. Foci of dystrophic calcification were seen. Stroma showed lymphocytic infiltrates with multinucleated giant cells. No evidence of malignancy was found.



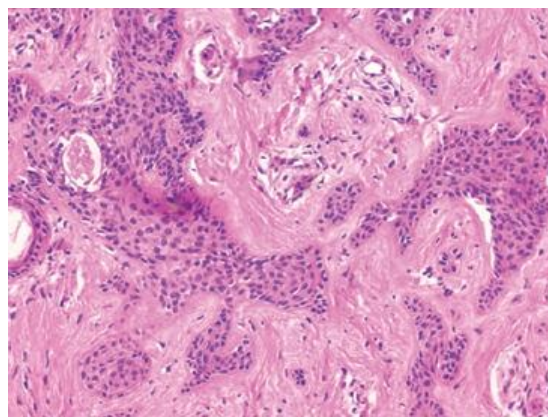
**Figure 01:PRE OPERATIVE**



**Figure 02: POST OPERATIVE**



**Figure 04 EXCISED TISSUE**



**Figure 05 HISTOPATHOLOGY**

## DISCUSSION

We present the findings of surgical excisional biopsy of four year old female patient diagnosed on clinical examination as having mass over upper lid, which was found on histological examination to have trichoepithelioma. It is important to distinguish between basal cell carcinoma and trichoepithelioma. Currently, all lesions diagnosed clinically as basal cell carcinoma (BCC) are treated by the excision of the lesion with 3–4 mm margins followed by histopathological examination to assess clearance and confirm the diagnosis. It may be possible to distinguish the features of trichoepithelioma in incisional biopsy specimens on morphological grounds alone, it is often difficult, and immune-histochemical staining, to delineate the features of the basement membrane, provides useful additional information in the histological diagnosis. As trichoepithelioma is more common in the young it should be considered in the differential diagnosis in young patients presenting with BCC-like lesions of the periocular tissues.

This case also demonstrates an uncommon location- the eyelid- for solitary trichoepithelioma. Aurora<sup>3</sup> reported the first case of solitary eyelid trichoepithelioma in 1974. Gray and helwig<sup>1</sup> found only one case in 83 solitary trichoepitheliomas; simpson and colleagues<sup>2</sup> found 18 cases

in 117 benign eyelid tumors; amd ozdal and colleagues found 3 cases in 2315 benign eyelid lesions.

Our case supports these observations about the predilection of solitary eyelid trichoepithelioma for upper eyelid

## CONCLUSION

Trichoepithelioma is uncommon tumor. Preoperative diagnosis can be challenging because of the unusual presentation and its similarity with basal cell carcinoma. It is important to perform early diagnosis , intervention and measures to be taken to rule out malignancies and avoid recurrence.

## REFERENCES

1. Gray HR, Helwig EB. Epithelioma adenoides cysticum and solitary trichoepithelioma. Arch Dermatol. 1963;87:102–14. [PubMed]
2. Simpson W, Garner A, Collin JR. Benign hair-follicle derived tumours in the differential diagnosis of basal-cell carcinoma of the eyelids: A clinicopathological comparison. Br J Ophthalmol. 1989;73:347–53.[PMC free article] [PubMed]
3. Aurora AL. Solitary trichoepithelioma of the eyelid. Indian J Ophthalmol. 1974;22:32–3. [PubMed]
4. Kuo DS, Nyong'o OL. Congenital solitary eyelid trichoepithelioma. J AAPOS. 2010;14:277–9.[PubMed]

5. Ozdal PC, Callejo SA, Codère F, Burnier MN., Jr Benign ocular adnexal tumours of apocrine, eccrine or hair follicle origin. *Can J Ophthalmol.* 2003;38:357–63. [PubMed]
6. Sugano DM, Lucci LM, Avila MP, Rehder JR, Pettinati J. Eyelid trichoepithelioma - Report of 2 cases. *Arq Bras Oftalmol.* 2005;68:136–9. [PubMed]
7. Mencía Gutiérrez E, Gutiérrez Díaz E, Ricoy JR, Gómez Ledesma I, Monescillo J, García Torre JP. Benign hair-follicle derived eyelids tumors in adults. *Arch Soc Esp Oftalmol.* 2002;77:605–10. [PubMed]

**Source of support:** Nil

**Conflict of interest:** None declared

This work is licensed under CC BY: *Creative Commons Attribution 3.0 License.*