

ORIGINAL ARTICLE

A DESCRIPTIVE STUDY OF HISTOPATHOLOGIC DIAGNOSIS OF LYMPH NODE BIOPSIES

Rekha Rani¹, Charu Chandra²

¹Assistant Professor, Department of Pathology, Career Institute of Medical Science and Hospital, Lucknow, Uttar Pradesh

²Associate Professor, Department of Pathology, Mayo Institute of Medical Science, Barabanki, Uttar Pradesh


ABSTRACT:

Background: Lymphadenopathy is a common clinical problem and biopsies are usually undertaken to determine the cause of nodal enlargement, which may be neoplastic or non-neoplastic. The present study was conducted to evaluate the spectrum of histopathological diagnosis of peripheral lymph node biopsies. **Materials & Methods:** This study was conducted in the department of general pathology in year 2013. Sections from formalin fixed, paraffin embedded blocks and stained with H and E, stains were studied in all cases. **Results:** Out of 850 biopsies, 450 were of males and 400 were of females. The difference was non - significant ($P > 0.05$). Age group 11-20 years had 50%, 21-30 years had 12%, 31-40 years had 27%, 41-50 years had 7% and > 50 years had 4% of lesions. The difference was significant ($P = 0.02$). Different lesions on lymph node biopsy were Non Hodgkin lymphoma (35%), Hodgkin lymphoma (12%), Tuberculosis (22%), Follicular hyperplasia (10%), Sinus histiocytosis (6%), Paracortical hyperplasia (5%) and metastatic lesion (10%). The difference was statistical significant ($P = 0.05$). Among 102 hodgkin lymphoma patients, the most common type was nodular sclerosis (39) followed by mixed cellularity (32), lymphocytic rich (10), lymphocytic depleted (9), not otherwise specified (6) and nodular lymphocyte predominant (4). The difference was statistical significant ($P = 0.05$). Among types of non Hodgkin lymphoma, we reported T-cell/ histiocyte rich large B cell lymphoma (TCHRBL) (3%), Follicular lymphoma (7%), burkitt's lymphoma (4%), diffuse large B- cell lymphoma (30%), lymphoplasmacytic lymphoma (8%), marginal zone lymphoma (9%), Mantle cell lymphoma (8%), angioimmunoblastic T-cell lymphoma (17%), Peripheral T- cell lymphoma (14%). **Conclusion:** For establishing the cause of lymphadenopathy, lymph node biopsy plays an important role. Maximum cases were of non hodgkin's lymphoma. Younger age group was commonly encountered. Among HL, nodular sclerosis was the commonest involved type.

Key words: Hodgkin lymphoma, Lymphadenopathy, neoplastic

Corresponding Author: Dr. Rekha Rani, Assistant Professor, Department of Pathology, Career Institute of Medical Science and Hospital, Lucknow, Uttar Pradesh, India

This article may be cited as: Rani R, Chandra C. A descriptive study of histopathologic diagnosis of lymph node biopsies. J Adv Med Dent Scie Res 2016;4(6):276-279.

Access this article online	
Quick Response Code 	Website: www.jamdsr.com
	DOI: 10.21276/jamdsr.2016.4.6.67

INTRODUCTION

Lymphadenopathy may be defined as one or more lymph nodes that are abnormal in size, consistency or number. It can be due to benign, self limited process or may be sign of serious underline disease. Infections, malignancy and immunologic disorders lead to lymphadenopathy. Lymphadenopathy is a common clinical problem and biopsies are usually undertaken to determine the cause of nodal enlargement, which may be neoplastic or non-neoplastic.¹ The neoplastic disorders are mainly lymphohematogenous malignancies and metastases while the causes of non-neoplastic lymphadenopathy are more varied such as infections (bacterial, viral, fungal), drug reactions (including certain vaccines), lipid storage

disorders and a wide variety of miscellaneous non-neoplastic lymphoproliferative disorders such as Castleman disease, Kimura disease, and systemic lupus erythematosus (SLE).²

Clinically, lymphadenopathy may be peripheral or visceral. Peripheral lymphadenopathies are easily detected by routine physical examination and are often biopsied as they are easily accessible for lymphadenectomy, which is a minor surgical procedure. Visceral lymphadenopathy on the other hand requires laparotomy or sophisticated imaging techniques for detection.³ Among the peripheral nodes, those in the upper part of the body (cervical, supraclavicular, axillary) are preferentially biopsied than lower limb nodes (popliteal, inguinal or femoral) as the

former are more likely to yield definitive diagnosis, whereas the latter are often characterized by non-specific reactive or chronic inflammatory and fibrotic changes.⁴ The present study was conducted to evaluate the spectrum of histopathological diagnosis of peripheral lymph node biopsies.

MATERIALS & METHODS

This study was conducted in the department of general pathology in year 2013. It included 850 cases of peripheral lymph node biopsies. All the cases were retrieved from the departmental archives and were reviewed. The patient information such as name, age, gender and clinical details were obtained from histopathology form.

Sections from formalin fixed, paraffin embedded blocks and stained with H and E, stains were studied in all cases. Where indicated, special stains including Ziehl Neelsen, periodic acid Schiff and Gomori’s methenamine silver were used. Immunohistochemistry (IHC) was performed using relevant antibodies according to the histomorphological features. The panel of antibodies included cluster of differentiation (CD)3, CD5, CD10, CD15, CD20, CD23, CD30, CD56, CD68, Leukocyte Common Antigen (LCA), Epithelial membrane antigen, cytokeratin, Bcl-2, Bcl-6, cyclin D1, kappa light chain, lambda light chain, Ki-67, TdT, smooth muscle actin, desmin, vimentin, Human Melanoma Black (HMB)-45, synaptophysin, chromogranin and S100. IHC was performed by avidin-biotin peroxidase method with pre-treatment by microwave heating. All lymphoma cases were classified according to standard World Health Organization classification of hemato-

lymphoid malignancies. Results were subjected to statistical analysis using chi square test. P value < 0.05 was considered significant.

RESULTS

Table I shows that out of 850 biopsies, 450 were of males and 400 were of females. The difference was non - significant (P > 0.05). Table II shows that age group 11-20 years had 50%, 21-30 years had 12%, 31-40 years had 27%, 41-50 years had 7% and > 50 years had 4% of lesions. The difference was significant (P - 0.02). Table III shows that different lesions on lymph node biopsy were Non Hodgkin lymphoma (35%), Hodgkin lymphoma (12%), Tuberculosis (22%), Follicular hyperplasia (10%), Sinus histiocytosis (6%), Paracortical hyperplasia (5%) and metastatic lesion (10%). The difference was statistical significant (P - 0.05). Graph I shows that among 102 hodgkin lymphoma patients, the most common type was nodular sclerosis (39) followed by mixed cellularity (32), lymphocytic rich (10), lymphocytic depleted (9), not otherwise specified (6) and nodular lymphocyte predominant (4). The difference was statistical significant (P - 0.05). Graph II shows that among types of non Hodgkin lymphoma, we reported T-cell/ histiocyte rich large B cell lymphoma (TCHRB) (3%), Follicular lymphoma (7%), burkitt lymphoma (4%), diffuse large B-cell lymphoma (30%), lymphoplasmacytic lymphoma (8%), marginal zone lymphoma (9%), Mantle cell lymphoma (8%), angioimmunoblastic T-cell lymphoma (17%), Peripheral T- cell lymphoma (14%).

Table I Distribution of patients with biopsy

Male	Female	P value
450	400	0.1

Table II Age wise distribution of patients

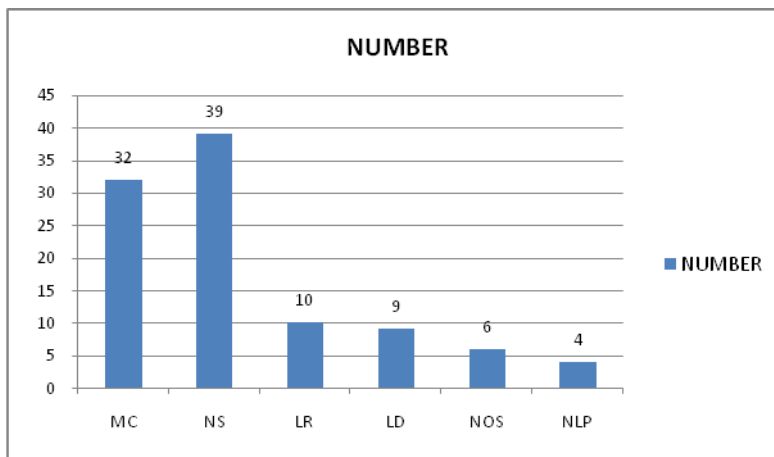
Age group	Percentage	P value
11-20 years	50%	0.02
21-30 years	12%	
31-40 years	27%	
41-50 years	7%	
>50 years	4%	

Table III Different lesions on lymph node biopsy

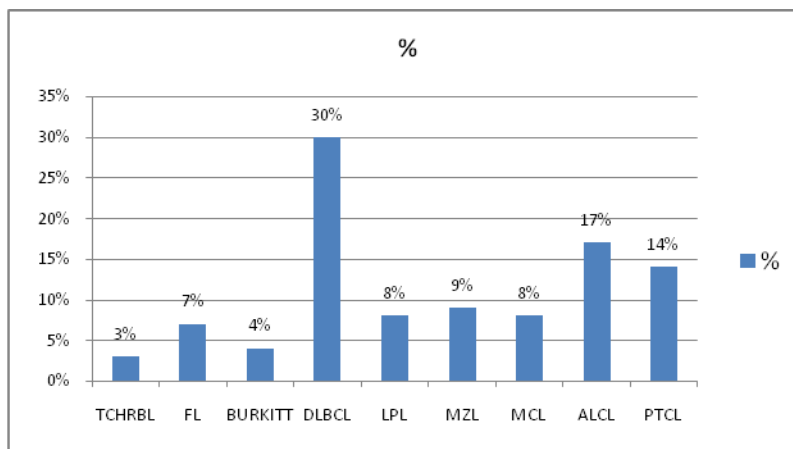
Type	Percentage	P value
Non Hodgkin lymphoma	35%	0.05
Hodgkin lymphoma	12%	
Tuberculosis	22%	
Follicular hyperplasia	10%	
Sinus histiocytosis	6%	
Paracortical hyperplasia	5%	
Metastatic lesion	10%	

Metastatic lesion 10%

Graph I Distribution of patients of Hodgkin lymphoma



Graph II Distribution of patients of Non- Hodgkin lymphoma



DISCUSSION

Palpable lymph nodes offer an important diagnostic clue to the etiology of the underlying condition. Though fine needle aspiration cytology is commonly used to establish the etiological diagnosis, excision biopsy of the lymph node remains the "gold standard" for diagnosis.⁵

The present study was conducted to evaluate the spectrum of histopathological diagnosis of peripheral lymph node biopsies. We found that out of 850 biopsies, 450 were of males and 400 were of females.

We found maximum number of biopsies in age group 11-20 years which had 50%, 21-30 years had 12%, 31-40 years had 27%, 41-50 years had 7% and > 50 years had 4% of lesions. This is in accordance to Grooves FD et al⁶ who also reported maximum specimen in younger age group in their study. We found that different lesions on lymph node biopsy were Non Hodgkin lymphoma (35%), Hodgkin’s lymphoma (12%), Tuberculosis (22%), Follicular hyperplasia (10%), Sinus histiocytosis (6%), Paracortical hyperplasia (5%) and metastatic lesion (10%). Anderson JR et al⁷ in their study found maximum of NHL cases.

However a study by Ko YH⁸ found maximum cases of Hodgkin lymphoma cases in their study.

Tuberculosis has been reported by several authors as the predominant cause of lymph node enlargement in adults in the tropics. In the Western countries, infections like tuberculosis have become rare and malignancies including lymphoma are now the predominant causes of lymph node enlargement.⁹

In this study we found that that among 102 hodgkin’s lymphoma patients, the most common type was nodular sclerosis followed by mixed cellularity, lymphocytic rich, lymphocytic depleted, not otherwise specified and nodular lymphocyte predominant. Similar results were obtained in the study of Sukhpanichnant S.¹⁰ However, Walter¹¹ found lymphocytic rich to be the commonest form.

We found that among types of non Hodgkin lymphoma, commonly reported were T-cell/ histiocyte rich large B cell lymphoma (TCHRBL), Follicular lymphoma, burkitt lymphoma, diffuse large B- cell lymphoma, lymphoplasmacytic lymphoma, marginal zone lymphoma,

Mantle cell lymphoma, angioimmunoblastic T-cell lymphoma, Peripheral T- cell lymphoma. This is in accordance to Ahmad M et al.¹²

CONCLUSION

For establishing the cause of lymphadenopathy, lymph node biopsy plays an important role. Maximum cases were of non hodgkin's lymphoma. Younger age group was commonly encountered. Among HL, nodular sclerosis was the commonest involved type.

REFERENCES

1. Ferrer R. Lymphadenopathy: Differential diagnosis and evaluation. *Am Fam Physician*. 1998; 58:1313-20.
2. Adeniji KA, Anjorin AS. Peripheral lymphadenopathy in Nigeria. *Afr J Med Med Sci*. 2000; 29: 233-7.
3. Sibanda EN, Stanczuk G. Lymph node pathology in Zimbabwe: A review of 2194 specimens. *Q J Med*. 1993; 86: 811-7.
4. Hartge P, Devesa SS, Fraumeni JF Jr. Hodgkin's and non-Hodgkin's lymphomas. *Cancer Surv* 1994; 20: 423-53.
5. Effect of age on the characteristics and clinical behavior of non-Hodgkin's lymphoma patients. The non-Hodgkin's lymphoma classification project. *Ann Oncol*. 1997; 8: 973-8.
6. Groves FD, Linet MS, Travis LB, Devesa SS. Cancer surveillance series: Non-Hodgkin's lymphoma incidence by histologic subtype in the United States from 1978 through 1995. *J Natl Cancer Inst*. 2000; 92:1240-51.
7. Anderson JR, Armitage JO, Weisenburger DD. Epidemiology of the non-Hodgkin's lymphomas: Distributions of the major subtypes differ by geographic locations. Non-Hodgkin's Lymphoma Classification Project. *Ann Oncol*. 1998; 9: 717-20.
8. Ko YH, Kim CW, Park CS, Jang HK, Lee SS, Kim SH, *et al*. REAL classification of malignant lymphomas in the Republic of Korea: Incidence of recently recognized entities and changes in clinicopathologic features. Hematolymphoreticular Study Group of the Korean Society of Pathologists. Revised European-American lymphoma. *Cancer*. 1998; 83: 806-12.
9. Chee YC. Tuberculous lymphadenitis in Singapore. *Ann Acad Med Singapore* 1982; 11: 587-92.
10. Sukpanichnant S, Sonakul D, Piankijagum A, Wanachiwanawin W, Veerakul G, Mahasandana C, *et al*. Malignant lymphoma in Thailand: Changes in the frequency of malignant lymphoma determined from a histopathologic and immunophenotypic analysis of 425 cases at Siriraj Hospital. *Cancer*. 1998; 83: 1197-204.
11. Walter PR, Klotz F, Alfy-Gattas T, Minko-Mi-Etoua D, Nguembi-Mbina C. Malignant lymphomas in Gabon (equatorial Africa): A morphologic study of 72 cases. *Hum Pathol*. 1991; 22: 1040-3.
12. Ahmad M, Khan AH, Mansoor A, Khan MA, Saeed S. Non-Hodgkin's lymphoma - Clinicopathological pattern. *J Pak Med Assoc*. 1992; 42: 205-7.

Source of support: Nil

Conflict of interest: None declared

This work is licensed under CC BY: *Creative Commons Attribution 3.0 License*.