

## Original Research

### A study of comparison between sigmoidectomy with colorectal anastomosis versus hartmann's procedure in the management of sigmoid gangrene

Dr. Arun Kumar Pandey<sup>1</sup>, Dr. Virendra K Mishra<sup>2</sup>

<sup>1</sup>MBBS, MS (General Surgery), Director, OPEC Hospital, Kaily, District- Basti, Uttar Pradesh, India;

<sup>2</sup>MBBS, DA, Senior Consultant, OPEC Hospital, Kaily, District- Basti, Uttar Pradesh, India

#### ABSTRACT:

**Background:** The present study compared sigmoidectomy with colorectal anastomosis versus hartmann's procedure in the management of sigmoid gangrene. **Materials & Methods:** 60 patients diagnosed with sigmoid volvulus were classified into 2 groups of 30 each. Group I patients were treated with sigmoidectomy with colorectal anastomosis and group II patients were managed with hartmann's procedure. Parameter such as wound infection, burst abdomen, anastomosis leak and colostomy retraction etc. was recorded. **Results:** Common comorbidities were diabetes mellitus seen in 5 in group I and 6 in group II, hypertension seen 4 in group I and 3 in group II, COPD 5 in group I and 7 in group II and neuropsychiatric disorder 2 in group I and 1 in group II. The difference was non- significant ( $P > 0.05$ ). Wound infection was seen 1 in group I and 2 in group II, burst abdomen 3 in group I and 2 in group II, anastomosis leak 2 in group I and 3 in group II and colostomy retraction 1 in each group. **Conclusion:** Conservative treatment with elective sigmoidectomy is the procedure of choice. If emergency surgery is indicated, Hartmann's procedure should be the procedure of choice.

**Key words:** Hartmann's procedure, Sigmoidectomy, Sigmoid gangrene.

Received: 5 November, 2019

Accepted: 26 November, 2019

**Corresponding author:** Dr. Arun Kumar Pandey, MBBS, MS (General Surgery), Director, OPEC Hospital, Kaily, District- Basti, Uttar Pradesh, India;

**This article may be cited as:** Pandey AK, Mishra VK. A study of comparison between sigmoidectomy with colorectal anastomosis versus hartmann's procedure in the management of sigmoid gangrene. J Adv Med Dent Sci Res 2019;7(12): 256-259.

#### INTRODUCTION

Volvulus refers to torsion of a segment of the alimentary tract, which often leads to bowel obstruction. The most common sites of volvulus are the sigmoid colon and cecum. Volvulus of other portions of the alimentary tract, such as the stomach, gallbladder, small bowel, splenic flexure, and transverse colon, are rare.<sup>1</sup> The presence of an elongated sigmoid colon with a narrow mesentery (dolichosigmoid) is a prerequisite for SV, which is thought to be related to advanced age, male gender, high altitude, dietary or defecation habits, and some pathologies such as megacolon.<sup>2</sup> Sigmoid volvulus (SV) generally presents as an acute large bowel obstruction. The most common clinical features

include abdominal pain, abdominal distention, and obstipation, which are known as the classical SV triad. It may be difficult to make an accurate preoperative diagnosis of SV without using sigmoidectomy, CT, or MRI; the diagnosis is currently made under laparotomy or on autopsy in 10-15% of patients.<sup>3</sup> Most common presenting symptom is abdominal pain and absolute constipation while vomiting is usually a late symptom.<sup>4</sup> Usually, huge abdominal distension is present and erect abdominal skiagram reveals omega sign which is a distended loop of sigmoid colon filling the entire abdomen with its base in the left iliac region.<sup>5</sup> It may be initially managed by sigmoidectomy or rectal tube insertion but where

fear of compromised vascular supply of the sigmoid colon is associated, immediate laparotomy after resuscitation must be undertaken to avoid gangrene and septic shock. Even following conservative detorsion, elective sigmoidectomy is advocated due to high rates of recurrence.<sup>6</sup> The present study compared sigmoidectomy with colorectal anastomosis versus hartmann's procedure in the management of sigmoid gangrene.

**MATERIALS & METHODS**

The present study was conducted among 60 patients diagnosed with sigmoid volvulus of both genders. All

were informed regarding the study and their consent was obtained.

Data such as name, age, gender etc. was recorded. A thorough physical and clinical examination was performed. All were classified into 2 groups of 30 each. Group I patients were treated with sigmoidectomy with colorectal anastomosis and group II patients were managed with hartmann's procedure. Parameter such as wound infection, burst abdomen, anastomosis leak and colostomy retraction etc. was recorded. Results were tabulated and subjected to statistical analysis. P value less than 0.05 was considered significant.

**RESULTS**

**Table I Distribution of patients**

Groups	Group I	Group II
Procedure	Sigmoidectomy with colorectal anastomosis	Hartmann's procedure.
M:F	20:10	16:14

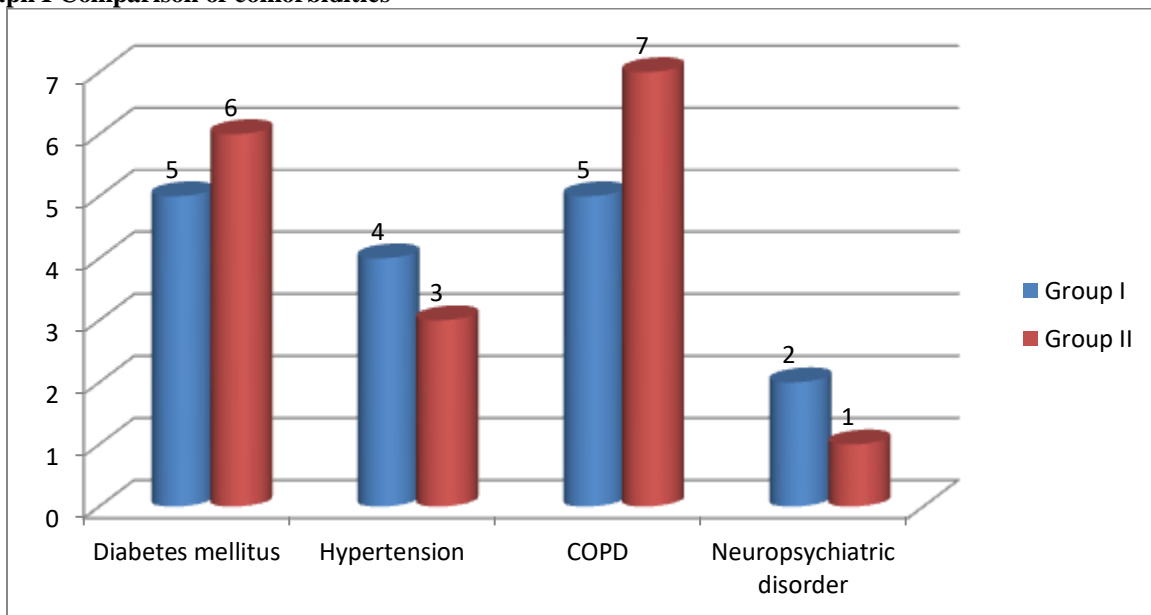
Table I shows distribution of patients based on procedure performed. There were 20 males and 10 females in group I and 16 males and 14 females in group II patients.

**Table II Comparison of comorbidities**

Comorbidities	Group I	Group II	P value
Diabetes mellitus	5	6	0.17
Hypertension	4	3	
COPD	5	7	
Neuropsychiatric disorder	2	1	

Table II, graph I shows that common comorbidities were diabetes mellitus seen in 5 in group I and 6 in group II, hypertension seen 4 in group I and 3 in group II, COPD 5 in group I and 7 in group II and neuropsychiatric disorder 2 in group I and 1 in group II. The difference was non-significant (P> 0.05).

**Graph I Comparison of comorbidities**

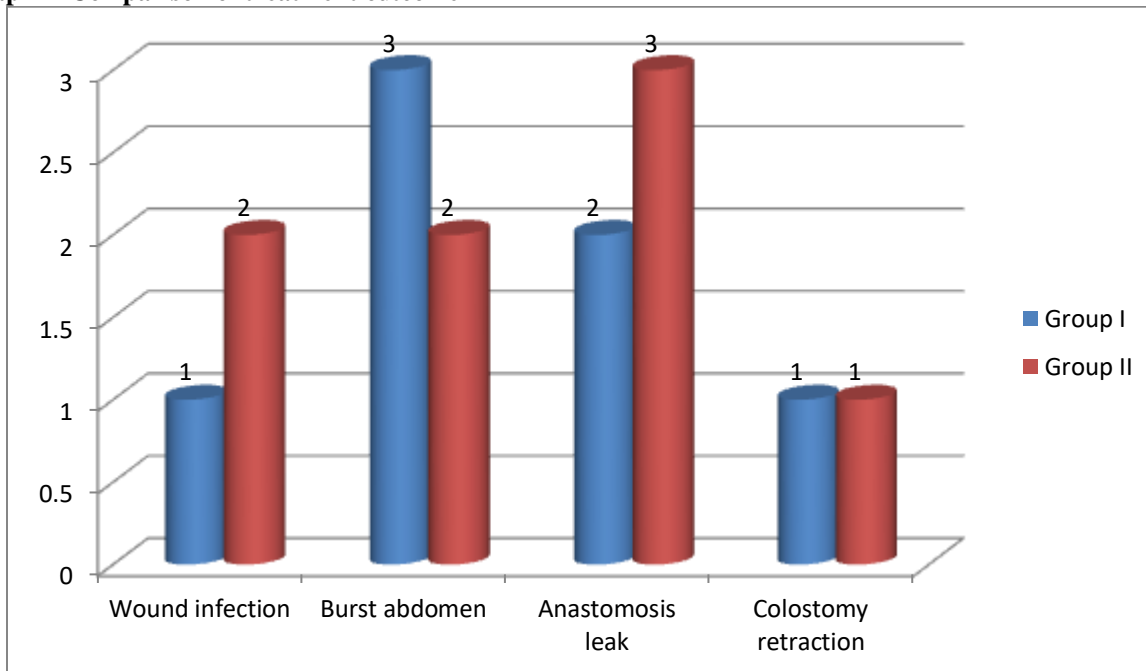


**Table III Comparison of treatment outcome**

Outcome	Group I	Group II	P value
Wound infection	1	2	0.52
Burst abdomen	3	2	0.94
Anastomosis leak	2	3	0.94
Colostomy retraction	1	1	1

Table III, graph II shows that wound infection was seen 1 in group I and 2 in group II, burst abdomen 3 in group I and 2 in group II, anastomosis leak 2 in group I and 3 in group II and colostomy retraction 1 in each group.

**Graph II Comparison of treatment outcome**



**DISCUSSION**

Any evidence or suspicion of a large bowel obstruction, particularly SV, is one of the main indications of diagnostic and/or therapeutic sigmoidectomy. Abdominal pain, abdominal distention, and obstipation (which are the symptoms of the classical SV triad) are observed on average in 93%, 89.9%, and 83% of SV patients, respectively.<sup>7</sup> Abdominal X-ray film shows SV findings, including a sigmoid dilatation with intestinal air-fluid levels, in 57-90% of patients.<sup>8</sup>

Sigmoidectomy helps establish the diagnosis of SV. The classical finding on sigmoidectomy is a spiral sphincter-like twist of the lumen, usually 20-30 cm from the anal verge additionally, the inability to insert the endoscope into the proximally twisted site helps lead to the correct diagnosis.<sup>9</sup> Sigmoidectomy allows for direct visualization of the bowel mucosa viability and may also be used in the differential diagnosis of SV by identifying the other causes of bowel obstruction, such as bowel malignancies or megacolon.<sup>10</sup> The

present study compared sigmoidectomy with colorectal anastomosis versus hartmann's procedure in the management of sigmoid gangrene.

In present study, group I patients were treated with sigmoidectomy with colorectal anastomosis and group II patients were managed with hartmann's procedure. There were 20 males and 10 females in group I and 16 males and 14 females in group II patients. Upendra et al<sup>11</sup> demonstrated the most suitable procedure for management of patients with sigmoid volvulus needing emergency surgery. Total 41 patients were included in the study of which 25 presented with gangrenous sigmoid colon on laparotomy and viable sigmoid colon was present in the remaining 16 cases. Comparison is done with respect to mortality and early morbidity associated with different operative procedures. Results: Highest mortality i.e. 33.3% observed among patients who underwent primary resection and anastomosis without proximal colostomy. Wound infection was more common following all forms of stoma procedure. Conclusion: Hartmann's procedure goes a long way in

decreasing mortality due to sigmoid volvulus in the emergency setting

We found that common comorbidities were diabetes mellitus seen in 5 in group I and 6 in group II, hypertension seen 4 in group I and 3 in group II, COPD 5 in group I and 7 in group II and neuropsychiatric disorder 2 in group I and 1 in group II. It has been documented previously by various studies that in the presence of gangrenous gut, Hartmann's procedure is the surgical intervention of choice as primary resection and anastomosis is associated with an unacceptably high mortality.

Atamanalp et al<sup>12</sup> did sigmoidectomy in 151 patients; the correct diagnosis was obtained in 149 of those patients (accuracy rate, 98.7%). Endoscopic misdiagnosis included colonic invagination in one patient and partial colonic volvulus in another; notably, there were colonic malignancies in both patients. Non-operative therapeutic procedures were used in 712 patients; barium enema in 13 patients, rigid sigmoidectomy in 351 patients, and flexible sigmoidectomy in 348 patients. When the patients with bowel gangrene are excluded, the therapeutic success rate of then on operative procedures is 82.1%, with a highest success rate in the flexible sigmoidectomy group (82.9%). In the non-operatively treated group, 5 patients (0.7%) died: 3 died from toxic shock and two died from peritonitis; the lowest mortality rate was in the flexible sigmoidectomy group (0.3%). Complications were observed in 17 of the non-operatively treated patients (2.4%). These complications included renal insufficiency in 13 patients, myocardial infarction in two patients, and peritonitis in 2 patients, with the lowest morbidity rate in the flexible sigmoidectomy group (1.4%). Early recurrence was observed in 26 patients (4.7%) with the lowest early recurrence rate in the rigid sigmoidectomy group (3.3%).

The shortcoming of the study is small sample size.

## CONCLUSION

Authors found that conservative treatment with elective sigmoidectomy is the procedure of choice. If emergency surgery is indicated, Hartmann's procedure should be the procedure of choice.

## REFERENCES

1. Shepherd JL. The epidemiology and clinical presentation of sigmoid volvulus. *Br J Surg* 1969; 56: 353-9.
2. Welch GH, Anderson JR. Acute volvulus of the sigmoid colon. *World J Surg* 1987; 11: 258-62.
3. Gibney EJ. Volvulus of the sigmoid colon. *Surg Gynecol Obstet* 1991; 173: 243-55.
4. Akgun Y. Mesosigmoidoplasty as a definitive operation in treatment of acute sigmoid volvulus. *Dis Colon Rectum* 1996;39: 579-81.
5. Kuzu MA, Aslar AK, Soran A, Polat A, Topcu O, Hengirmen S. Emergent resection for acute sigmoid volvulus – results of 106 consecutive cases. *Dis Colon Rectum* 2002; 45: 1085-90.
6. Dulger M, Canturk NZ, Utkan NZ, Gonullu NN. Management of sigmoid colon volvulus. *Hepatogastroenterology* 2000; 47: 1280-3.
7. Bagarani M, Conde AS, Longo R, Italiano A, Terenzi A, Venuto G. Sigmoid volvulus in west Africa: a prospective study on surgical treatments. *Dis Colon Rectum* 1993; 36: 186- 90.
8. Raveenthiran V. Restorative resection of unprepared left colon in gangrenous vs viable sigmoid volvulus. *Int J Colorectal Dis* 2004; 19: 258-63.
9. Madiba TE, Thomson SR. The management of sigmoid volvulus. *J R Coll Surg Edinb.* 2000;45(1):74–80.
10. Lal SK, Morgenstern R, Vinjirayer EP, Matin A. Sigmoid volvulus an update. *Gastrointest Sigmoidectomy Clin N Am.* 2006;16(1):175–187.
11. Upendra P, Modi B. Choice of operative technique for emergency cases of sigmoid volvulus in a tertiary care hospital of Gujarat. *Hypertension.* 2012;12:29-6.
12. Atamanalp SS, Atamanalp RS. The role of sigmoidectomy in the diagnosis and treatment of sigmoid volvulus. *Pakistan Journal of medical sciences.* 2016 Jan;32(1):244.