

## Original Research

### Assessment of ridge morphology and dental implant treatment outcome

Vibhash Priyadarshi<sup>1</sup>, Bineet Kumar<sup>2</sup>, Abhijit Kumar<sup>3</sup>, Ravi Shankar Prasad<sup>4</sup>, Ayusha Kumari<sup>5</sup>, Neeraj Kumar<sup>6</sup>

<sup>1</sup>Second year PG student, Department of Prosthodontics and crown and bridge,

<sup>2</sup>Third year PG student, Department of Prosthodontics and crown and bridge,

<sup>3</sup>Third year PG student, Department of Orthodontics,

<sup>4</sup>Second year PG student, Department of Cons and Endodontics,

<sup>5</sup>Second year PG student, Department of Periodontics,

<sup>6</sup>Second year PG student, Department of Prosthodontics and crown and bridge,

Vananchal Dental College and Hospital Garhwa, Jharkhand, India

#### ABSTRACT:

**Background:** The present study was conducted to assess effect of ridge morphology on dental implant treatment outcome.

**Materials & Methods:** The present study was conducted in the department of Prosthodontics. It comprised of 86 patients who received dental implants in mandibular posterior region. Different types of ridge such as undercut type, parallel and convex type was assessed. Number of dental implants failure was calculated. **Results:** Out of 86 patients, males were 37 and females were 49. Males had 52 and females had 68 dental implants. In 24 patients, ridge was undercut type, in 46 was parallel type and in 16 was convex type. Maximum dental implants failure was seen with undercut type 7 (29.1%) followed by convex type 4 (25%) and parallel in 5 (10.8%). The difference was significant ( $P < 0.05$ ). **Conclusion:** Authors found that maximum dental implants were observed with undercut type followed by convex type ridge.

**Key words:** Convex ridge, Dental implants, Undercut type.

Received: 12 December, 2019

Accepted: 22 December, 2019

**Corresponding author:** Dr. Bineet Kumar, Department of Prosthodontics and crown and bridge, Vananchal Dental College and Hospital Garhwa, Jharkhand, India

**This article may be cited as:** Priyadarshi V, Kumar B, Kumar A, Prasad RS, Kumari A, Kumar N. Assessment of ridge morphology and dental implant treatment outcome. *J Adv Med Dent Scie Res* 2020;8(1):240-243.

#### INTRODUCTION

Dental implants have been widely used in partial or full edentulism for oral rehabilitation. Long-term prospective studies and systematic reviews have demonstrated that more than 95% survival rate could be expected after 5-year of loading.<sup>1</sup>

However, several etiologies might still contribute to early or late failure of dental implants such as biological, mechanical or iatrogenic factors. Criteria to determine survival and success of dental implants have been reported in several studies. Based on the International Congress of Oral Implantologists (ICOI) Pisa Consensus Conference report, survival represents

that the implant is still kept in the mouth instead of being removed, and should not present any mobility, pain on function or bone loss more than 1/2 of implant length.<sup>2</sup>

In the posterior mandibular region, a lingual undercut is a common finding and can be difficult to manage. It is not unusual for surgeons to struggle when placing implants in this area, especially when a lingual plate perforation is suspected.<sup>3</sup> A lot of time it is necessary to check the angulations and positioning of the drills or implant fixtures via radiographs and clinical detection of a possible perforation in the osteotomy site. This tedious process increases the length of the surgery and

adds stress to both the patient and the clinician thus compromising the success of the procedure. The type C ridge was one where the base of the ridge was wider than its crest. On the other hand, the type P ridge generally had a more or less parallel ridge form. U shaped ridge was undercut type.<sup>4</sup> The present study was conducted to assess effect of ridge morphology on dental implant treatment outcome.

**MATERIALS & METHODS**

The present study was conducted in the department of Prosthodontics. It comprised of 86 patients who

received dental implants in mandibular posterior region. Ethical approval from institutional ethical committee was obtained. All were informed and written consent was obtained.

Data such as name, age, gender etc. was recorded. Different types of ridge such as undercut type, parallel and convex type was assessed. Number of dental implants failure was calculated. Results were tabulated and subjected to statistical analysis. P value less than 0.05 was considered significant.

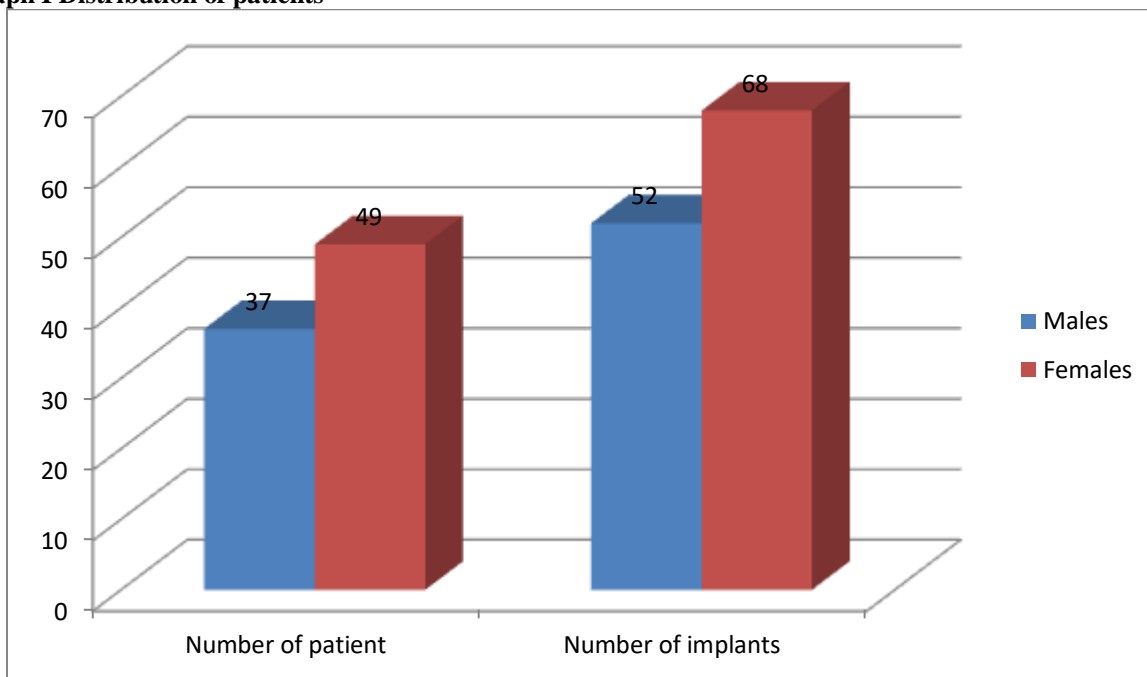
**RESULTS**

**Table I Distribution of patients**

Gender	Males	Females
Number of patient	37	49
Number of implants	52	68

Table I shows that out of 86 patients, males were 37 and females were 49. Males had 52 and females had 68 dental implants.

**Graph I Distribution of patients**

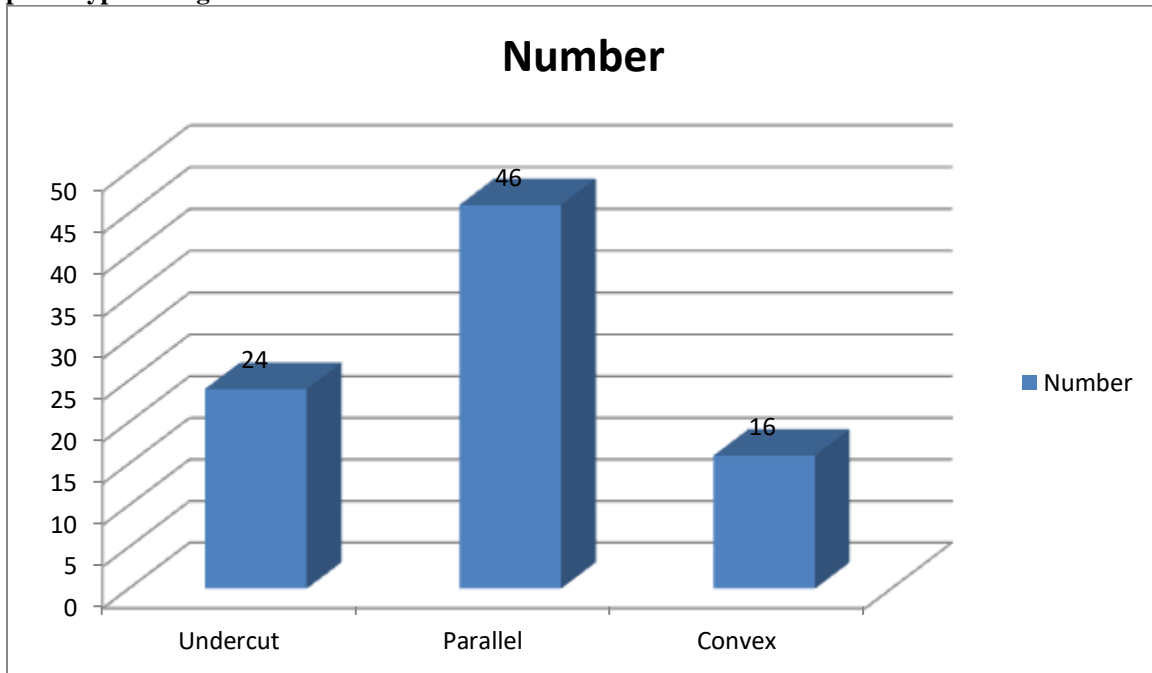


**Table II Type of ridge**

Ridge	Number	P value
Undercut	24	0.01
Parallel	46	
Convex	16	

Table II shows that in 24 patients, ridge was undercut type, in 46 was parallel type and in 16 was convex type. The difference was significant (P< 0.05).

**Graph II Type of ridge**



**Table III Dental implants failure rate**

Ridge type	Implant failure	P value
Undercut	7 (29.1%)	0.02
Parallel	5 (10.8%)	
Convex	4 (25%)	

Table III shows that maximum dental implants failure was seen with undercut type 7 (29.1%) followed by convex type 4 (25%) and parallel in 5 (10.8%). The difference was significant ( $P < 0.05$ ).

**DISCUSSION**

Implant therapy has become an integral part of daily dental practice because of its high success rate. With proper diagnosis and treatment planning, most implant surgeries can proceed uneventfully and fulfill functional and esthetic demands after osseointegration. However, surgical accidents and complications do occur.<sup>5</sup> They can happen during surgery, at the healing period or even after function. They can cause either mild or severe problems, depending on the degree of the damage. Unavoidable complications may be triggered by placing implants outside the osseous boundary. They may cause damage of vital anatomical structures, resulting in loss of function or life threatening events. They may also result in inflammation, infection and ultimate loss of implants at later time. Albrektsson et al<sup>6</sup> defined that a successful implant must present no mobility, no peri-implant radiolucency, bone loss less than 0.2 mm per year after the first year of loading, and no persistent pain, discomfort or infection. Failure of a dental implant is determined when an implant is with mobility, pain on function, uncontrolled exudates, or severe bone loss. In this case, the implant should be removed. The present

study was conducted to assess effect of ridge morphology on dental implant treatment outcome. In present study, out of 86 patients, males were 37 and females were 49. Males had 52 and females had 68 dental implants. Residual Alveolar Ridge is the absence of teeth after extraction of teeth where the bone starts to resorb.<sup>7</sup> The maxilla and mandible resorbs differently by which the maxilla becoming narrower or decreasing in width and the mandible become wider. Residual Ridge Resorption is greater during first few months after the tooth extraction. Later the rate of resorption is twice more pronounced in mandible than maxilla. Immediately following the extraction any sharp edges remaining are rounded off by external osteoclastic resorption leaving a high well rounded residual ridge. As resorption continuous from the labial and lingual aspect, the crest of the ridge become increasingly narrow ultimately becoming the knife edge as the process continues when knife edge become shorter or even eventually disappears leaving a low well rounded or flat ridge eventually this resorbs leaving a depressed ridge.<sup>8</sup>

We found that in 24 patients, ridge was undercut type, in 46 was parallel type and in 16 was convex type. Maximum dental implants failure was seen with undercut type 7 (29.1%) followed by convex type 4 (25%) and parallel in 5 (10.8%). Wang et al<sup>9</sup> in their study cone beam computed tomography images of 488 posterior teeth from 61 patients were selected. Virtual immediate implant placement (VIIP) was performed at each posterior tooth following the appropriate axis with the prosthetic-driven planning and different deviation angles of 3-, 6-, or 9-degree. BPP was then examined from cross-sectional images obtained. The incidence of buccal and lingual BPP increased as the deviation angle increased in posterior mandible area. Incidence of lingual BPP was significantly influenced by angular deviation and type of lingual bony morphology after adjusting for age, gender, tooth type, and right/left side. An increase in incidence odds of over 6-fold was noted for placements angled by 9° compared with placements made without angulation, and an increase in incidence odds of over 3-fold was noted for teeth with the undercut-type lingual morphology compared with the other types.<sup>10</sup>

## CONCLUSION

Authors found that maximum dental implants was observed with undercut type followed by convex type ridge.

## REFERENCES

1. Van der Weijden GA, van Bommel KM, Renvert S. Implant therapy in partially edentulous, periodontally compromised patients: a review. *J Clin Periodontol* 2005;32:506-511.
2. Ferreira SD, Silva GL, Cortelli JR, Costa JE, Costa FO. Prevalence and risk variables for peri-implant disease in Brazilian subjects. *J Clin Periodontol* 2006;33:929-935.
3. Fu JH, Hsu YT, Wang HL. Identifying occlusal overload and how to deal with it to avoid marginal bone loss around implants. *Eur J Oral Implantol* 2012;5 Suppl:S91-103.
4. Chan HL, Brooks SL, Fu JH, Yeh CY, Rudek I, Wang HL. Cross-sectional analysis of the mandibular lingual concavity using cone beam computed tomography. *Clinical oral implants research*. 2011 Feb;22(2):201-6.
5. Ferrigno N, Laureti M, Fanali S, Grippaudo G. A long-term follow-up study of non-submerged ITI implants in the treatment of totally edentulous jaws. Part I: Ten-year life table analysis of a prospective multicenter study with 1286 implants. *Clin Oral Implants Res* 2002;13:260-273.
6. Greenstein, G., Cavallaro, J., Romanos, G. & Tarnow, D. Clinical recommendations for avoiding and managing surgical complications associated with implant dentistry: a review. *Journal of Periodontology* 2008; 79: 1317–1329.
7. Albrektsson T, Zarb G, Worthington P, Eriksson AR. The long-term efficacy of currently used dental implants: a review and proposed criteria of success. *Int J Oral Maxillofac Implants* 1986;1:11-25.

8. Greenstein, G., Cavallaro, J. & Tarnow, D. Practical application of anatomy for the dental implant surgeon. *Journal of Periodontology* 2008; 79: 1833–1846.
9. Fu JH, Hsu YT, Wang HL. Identifying occlusal overload and how to deal with it to avoid marginal bone loss around implants. *Eur J Oral Implantol* 2012;5 Suppl:S91-103.
10. Ferrigno N, Laureti M, Fanali S, Grippaudo G. A long-term follow-up study of non-submerged ITI implants in the treatment of totally edentulous jaws. Part I: Ten-year life table analysis of a prospective multicenter study with 1286 implants. *Clin Oral Implants Res* 2002;13:260-273.
11. Wang TY, Kuo PJ, Fu E, Kuo HY, Chang NN, Fu MW, Shen EC, Chiu HC. Risks of angled implant placement on posterior mandible buccal/lingual plated perforation: A virtual immediate implant placement study using CBCT. *Journal of dental sciences* 2019 Sep 1;14(3):234-40.