

Review Article

Oral Manifestation of Helminth Infection Due to Nematode

Emma Rachmawati, Nani Murniati, Winny Yohana

Department of Oral Biology, Faculty of Dentistry, Universitas Padjadjaran, Bandung, West Java, Indonesia

ABSTRACT:

Nematode is helminth that have body shape of rounded, not segmented, its body cavity has a simple digestive tract starting with the oral cavity on the anterior side and ending at the anus on the posterior side. Some species live as parasites in human body as a host at certain stages in their life cycle that may be transmitted through soil and vector. Parasitic infections have very high prevalence especially in countries that have warm and humid climate. There are two species of nematode that may provoke oral manifestation are those *Ancylostoma sp.* and *Filariae sp.* *Ancylostoma sp.* can cause hookworm-related cutaneous larva migrans (HrCLM) is that the self-limited disease caused by worm larvae migration under skin which will provide the typical clinical symptoms as erythematous and linear lesion of oral mucosa. On the other hand, *Filariae sp.* may cause perioral lymphatic filariasis (LF) is that filariasis that is initiated by the emergence of nodules in the oral mucosa without causing pain but sometimes there is an itching in the nodules. Both of the disease are rare but it is still a possibility to be suffered by vulnerable individual and if it is so, administration of anthelmintic would be needed in order to accelerate healing process.

Key words: Oral manifestation, helminth infection, nematode.

Received: 13 March, 2019

Revised: 22 April 2019

Accepted: 25 April 2019

Corresponding author: Emma Rachmawati, Senior lecturer, Department of Oral Biology, Faculty of Dentistry, Padjadjaran University, Bandung-Indonesia

This article may be cited as: Rachmawati E, Murniati N, Yohana W. Oral Manifestation of Helminth Infection Due to Nematode. J Adv Med Dent Scie Res 2019;7(8): 211-213.

INTRODUCTION

Helminth literally means worms, not only those that live as parasites but even most species of worms live freely in nature. Some species live as parasites in human body as a host at certain stages and also live in nature at other stages in their life cycle. Morphologically, the worm's body shape is quite typical, which is long, and symmetrical bilaterally with a size that is quite varied from smaller than 1 millimeter to reach one meter or more. In its life cycle, there are several stages starting from the egg, larval and adult stages which can be completed in one or two host bodies.¹ The transmission of worm disease may be through various ways, according to WHO (1964) can be through soil and vectors. WHO reports that worm parasitic infections are very high, especially in countries that have warm and humid climate, including countries in Southeast Asia.

The body shape of the nematode is rounded, not segmented, has a body cavity that has a simple digestive tract starting with the oral cavity on the anterior side and ending at the anus on the posterior side. The Nematodes do not have a circulatory system, the excretory system is quite simple, its body is covered with a layer of fine

cuticles and underneath is a layer of longitudinal muscles. most of the Nematodes live as parasites and are the most infecting worm parasites.²

There are two species of Nematodes that can cause high prevalence of worm infection are those *Ancylostoma sp.* which belong to soil transmitted helminth and *Filariae sp.* belonging to tissue nematode. The species of *Ancylostoma* that may give manifestation in the oral cavity are *Ancylostoma braziliensis* and *Ancylostoma caninum* which inhabit dog and cat as their host. On the other hand, *Filariae sp.* have been reported to cause persistent oral mucosa and facial swelling, *Ancylostoma braziliensis* and *Ancylostoma caninum* are hookworm and the diseases caused by them is known as hookworm-related cutaneous larvae migrans (HrCLM) or creeping eruption³, meanwhile the infection caused by *Filariae sp.* is known as lymphatic filariasis (LF).⁴

Hookworm-Related Cutaneous Larva Migrans (HrCLM)

Based on its location, HrCLM is divided into two, namely visceral larvae migrans and cutaneous larvae migrans. In

the case of cutaneous larvae migrans, the worm parasite will be trapped under the skin and will remain alive for several weeks to several months where the parasite will form a cyst. Larvae can cause quite severe reactions by forming one or more winding tunnels in the epidermis tissue. The tunnel sizes may vary greatly, averaging 2 - 4mm.⁵ In this case parasitic worm larvae cannot continue their life cycle in the human body because humans act as accidental hosts while the definitive hosts are dogs and cats. Humans can be infected with this worm parasite because infective larvae or filariform larvae penetrate skin pores, hair follicles, or damaged skin. larvae will actively penetrate the skin by producing the hyaluronidase enzyme and will enter the blood capillaries which then will passively move in circulation system.⁶ Andre et al (1988) and Damante (2011) have ever reported HrCLM sufferers on oral mucosa. Damante reported the presence of parasite migratory stomatitis by observing the pathway of the parasite larvae histologically in the oral mucosa. One of the sufferers was a woman who complained of having a lesion on the oral mucosa that was painful and spread to various regions of the oral cavity accompanied by itching and the presence of parasitic movements. This condition spreads to the retromolar region, soft palate, tonsils, and throat which causes respiratory problems. Intra oral examination revealed erythematous on the buccal mucosa. Biopsy examination showed an increase in acute inflammatory cells, eosinophils, and larvae of worm parasites.^{7,8}

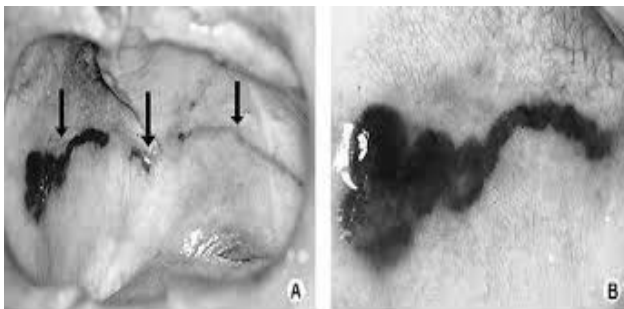


Figure 1: Erythematous linear as a sign of larvae parasite migration track.⁸

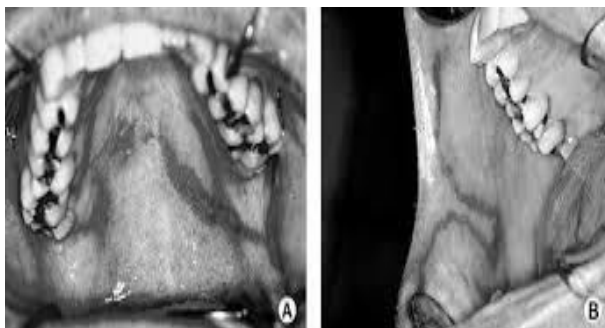


Figure 2: Spreading of erythema toward palatal and buccal mucosa as sign of larvae parasite migration.⁸

The second case Damante found was that a man suffering from erythematous on oral mucosa appeared intermittently within 3 months with a burning sensation.

Intra oral examination showed linear lesions throughout the oral mucosa. The lesion begins with the appearance of a fusiform lesion on the right side of the palatal mucosa that spreads to the left side that eventually reached the mandibular region which ended in the right-sided buccal mucosa. Biopsy examination found a dilatation of blood vessel, elevation of erythrocytes, PMN, neutrophils, eosinophils, and visible parasitic larvae that contain parasitic fragments.⁸

Oral HrCLM is actually a rare disease, but may occur as long as there is an opportunity to contact unhealthy pets and things contaminated with hookworm larvae. Oral HrCLM is a self-limited disease because the larvae will die within 4-8 weeks due to the inability to mature so the disease can heal by itself. Nevertheless, this could be a recurrence for those who are in constant contact with soil or contaminated matters as well as have a low immune response.^{1,2,8} Oral HrCLM can be diagnosed based on anamnesis, clinical symptoms, and biopsy. Although this disease may heal by itself, anthelmintic treatment is still needed with the aim of accelerating recovery, especially in infections with a large number of larvae. Anthelmintic that can be given is topical or oral thiabendazole. Administration of 400 mg orally for 3-5 days will give a better effect compared to topical treatment. Anthelmintic administration can be done repeatedly if one treatment period has no effect. In certain cases, required surgical incision or excision using ethyl chloride.^{1,2}

Perioral lymphatic filariasis (LF)

Filarial worms are tissue nematodes, which are nematodes that live as parasites in the blood and human or animal tissue as the host. Adult worms live in the lymphatic system, in subcutaneous tissue, in connective tissue or in human body cavities meanwhile its larvae known as microfilariae live in blood vessels. Once the adult female worm deliver larvae, motile microfilariae can immediately be detected in peripheral blood vessels. Microfilariae can live for 1-2 years in the body of a vertebrate host without further development and cannot be transmitted directly to other vertebrate hosts. This happens because tissue nematodes require another host for further larval development which will also act as an infection vector. Hosts that can act as transmission vectors are insect mosquitoes of *Anopheles*, *Aedes*, *Mansonia*, *Culex*, *Simulium*, *Chrysops* or *culicoides* depending on the species.^{1,2}

Perioral manifestations of LF are very rare, but several cases have been reported with symptoms of swelling of the lips, interdental papillae, oral mucosa and extra oral submandibular swelling. Oral manifestations of lymphatic filariasis can be initiated by the emergence of nodules in the oral mucosa without causing pain but sometimes there is an itching in the nodules. Usually, the general condition of the patient is quite good but on laboratory examination will be seen an increase in the number of eosinophils. Histopathological examination revealed worm parasites which were seen as capsule structures containing alimentary channels surrounded by necrotic tissue and proliferating blood vessels.⁹

LF often does not provide symptoms of microfilaremia because this disease is very dependent on the immune system so that if the patient's immune system is good enough then the infection becomes asymptomatic. In some cases, chronic LF will provide a fairly severe abnormality in the form of elephantiasis which is a symptom of lymph node obstruction, therefore this abnormality is also called chronic obstructive filariasis which is characterized by enlarged lymph nodes, thickening of lymph vessels, hydrocele, diarrhea and lymphedema. Another type of LF is the acute type which clinically will give symptoms of fever (filarial fever), lymphadenitis, lymphangitis, funikulitis, epididymitis, filarial orchitis and filarial abscess.^{1,2}

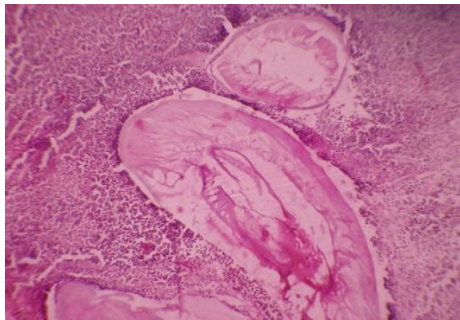


Figure 3: Histological examination revealed worm parasites.⁹

Perioral symptoms of lymphatic filariasis would be submandibular abscesses that do not heal after being treated with antibiotics several times and incision and drainage have also been performed. Cytological examination showed the presence of microfilaria *W.Bancrofti* which is round in the anterior and flat in the posterior and visible nucleus in the transparent area at the caudal end.¹⁰ Involvement of intraoral filariasis is very rare, and diagnosis is highly dependent on confirmation based on parasitic identification of nodules under a microscope.¹¹

Oral filariasis treatment can use the same medication as for other types of LF, namely diethyl carbamazine (DEC) given at a dose of 6 mg/kg for 7 to 12 days. This drug can kill microfilariae but its effect on adult worms is not yet clear. The combination of DEC with ivermectin or albendazole will give a better effect. DEC can have side effects as bullous eruptions on the skin as an allergic reaction and if this happens treatment can be accompanied by corticosteroids. Antibiotics may be given if there is a secondary infection due to bacteria.¹²

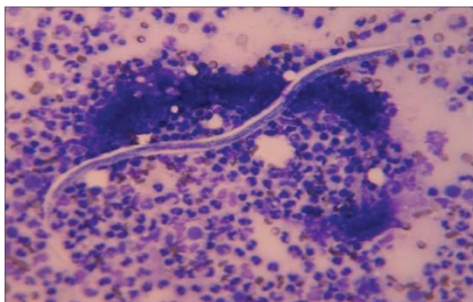


Figure 4: A microfilaria of *Wuchereria bancrofti*.¹⁰

CONCLUSION

Hookworm-related cutaneous larvae migrans (HrCLM) and lymphatic filariasis (FL) are diseases that are found in many tropical and subtropical countries according to the prevalence of nematode infections that have been proven to be very high in these countries. These diseases are found in oral cavity with their pathogenesis as same as in other part of the body. Oral LF requires treatment with the anthelmintic DEC to combat microfilaria in blood vessels while to eradicate adult worms can be given albendazole. In contrast to oral LF, HrCLM actually can heal by itself due to the larvae in the peripheral blood vessels will die because they cannot continue their life cycle. However, administration of anthelmintic drugs is still recommended to accelerate the healing process.

REFERENCES

1. Arora, Arora, B.B. Medical Parasitology. CBC Publishers & Distributors, Darya Ganj, New Delhi. 2004. 2nd ed.
2. Roberts, LS, Janovy J. Foundations of Parasitology. Mc Graw-Hill International Edition. 2010; 2nd ed.
3. Heukelbach J, Jackson A, Ariza L, Feldmeyer H. Prevalence and risk factor of hookworm-related cutaneous larva migrans in a rural community in Brazil. An Trop Med Parasitol, 2008; 102:53-61
4. Mohan H, Bisht B, Goel P, Garg G. Vulval Elephantiasis: A Case Report. <http://dx.doi.org/10.1155/2012/430745> Volume 2012 (2012), Article ID 430745, 3 pages
5. Joklik WK, Willet HP, Amos DB, Wilfert CM. Zinseer Microbiology. Appleton & Lange, Norwalk, Connecticut, California. 1992; 20th ed.
6. Quashie NB, Tsegah E. An unusual recurrence of pruritic eruption after treatment of cutaneous larvae migrans in an adult Ghanaian male: a case report with a brief review of literature. J. Pan African Medical. 2015; 21:28
7. Andre J, Bernard B, Ledoux M, Achten G. Larvae migrans of oral mucosa. J. Dermatologica. 1998; 176:296-98
8. Damante JH, Chinellato LEM, Oliveira FT, Soares CT, Fleury RN. Larva migrans in the oral mucosa: report of two cases. Braz Dent J. 2011; 22(2):166-70
9. Baliga M, Ramanathan A, Uppal N. Oral filariasis – a case report. British J of Oral and Maxillofacial Surgery 2010; 48:143-44
10. Kaur R, Philip KJ, Laxman KR, Masih K. Filarial abscess in the submandibular region. J. Oral Maxillofac Pathol 2013; 17:320
11. Pereira LL, Coletta RD, Monteiro LC, Ferreira VYN, Leon JE, Bonan PRF. Dirofilaria involving the oral cavity: report of the first case from South America. Rev. Soc. Bras. Med. Trop May/June 2015; 48(3):1-3
12. John DT, Petri WA. Medical Parasitology. 2006. Elsevier.