

**ORIGINAL ARTICLE****INCIDENTAL FINDINGS ON PANORAMIC RADIOGRAPH: A CLINICAL STUDY**

Syed Vaseemuddin

Professor, Department of Oral Medicine and Radiology, Dasmesh Institute of Research and Dental Sciences, Faridkot, Punjab, India


**ABSTRACT:**

**Background:** Panoramic radiography is a two-dimensional dental x-ray examination that captures the entire mouth in a single image, including the teeth, upper and lower jaws, surrounding structures and tissues. The study was conducted to report the incidental findings on panoramic radiographs. **Materials & Methods:** This study was conducted in the department of Oral Medicine & Radiology in year 2010. It included panoramic radiographs of 410 subjects obtained for various reasons. Patient's information such as name, age, gender, indication of OPG was recorded. All images which were of non informative and faulty were excluded from the study. All images were taken with single digital Care stream 8000 (Kodak OPG machine). **Results:** Out of 410 subjects whose OPG were taken, incidental findings were seen in 200 patients with prevalence rate of 50% (males- 90, females -110). The difference was non significant ( $P>0.01$ ). The mean age of males was 35.2 years and females 36.4 years. The difference was non significant ( $P>0.01$ ) Following incidental findings were recorded such as elongated styloid process (25%), maxillary sinus pathology (105), foreign bodies (5%), soft tissue calcification (12%), dental anomalies (7%) and TMJ disorders (2%). Most common finding was elongated styloid process. The difference was significant ( $P<0.05$ ). Unilateral 13% and bilateral 12% of styloid process showed elongation. Retention pseudocyst was seen in 5%, sinus opacification in 2% and mucosal thickening was seen in 3% of cases. Most commonly seen soft tissue calcifications was tonsillolith (4%), phlebolith (4%), vascular calcification (3%) and sialolith (1%). Common dental anomalies were supernumerary teeth (2%), microdontia (3%), root dilacerations and external root resorption in 1% of all cases. Commonly seen TMJ disorders such as cystic lesions and degenerative joint diseases in 1% of all cases. **Conclusion:** Panoramic radiograph is a preferred routine diagnostic tool for the evaluation of large lesions, cysts, tumors etc. The additional advantage is incidental findings which may remain undetected if other radiographs would be taken. Thus it can be useful in detecting hidden findings

**Key words:** Microdontia, panoramic radiograph, sialolith

Corresponding Author: Dr. Syeed Vaseemuddin, Professor, Department of Oral Medicine and Radiology, Dasmesh Institute of Research and Dental Sciences, Faridkot, Punjab, India

This article may be cited as: Vaseemuddin S. Incidental findings on panoramic radiograph: A clinical study. J Adv Med Dent Scie Res 2016;4(6):223-226.

Access this article online	
<b>Quick Response Code</b> 	Website: <a href="http://www.jamdsr.com">www.jamdsr.com</a>
	DOI: 10.21276/jamdsr.2016.4.6.54

**INTRODUCTION**

Panoramic radiography, also called panoramic x-ray, (OPG) orthopantomogram is a two-dimensional dental x-ray examination that captures the entire mouth in a single image, including the teeth, upper and lower jaws, surrounding structures and tissues. They provide a general overview of both jaws and their dentition and the temporomandibular joints, cervical vertebrae, and the inferior portion of the orbital cavity.<sup>1</sup>

It is also known as a routine radiological diagnostic tool for the examination since it uses relatively low doses of radiation approximately 20  $\mu$ Sv as compared to a full mouth radiographs which utilizes series approximately 171  $\mu$ Sv.<sup>2</sup>

The indications of OPG are cysts and tumors of the Jaws, advanced periodontal diseases, oral cancer, evaluation of impacted teeth including wisdom teeth such as depth and angulation of impaction, in addition to the relationship to adjacent structures, jaw disorders such as temporomandibular joint or TMJ disorders, sinusitis etc. Due to low resolution images that are unsuitable for examining details or detecting carious lesions and shadows of spine in midline interrupts examination of lower anteriors.<sup>3</sup> Sometimes, apart from required information, incidental findings do present on the radiographs. Identification and reporting of such findings is of paramount importance because they may necessitate medical and/or dental intervention.

The study was conducted to report the incidental findings on panoramic radiographs.

**MATERIALS & METHODS**

This study was conducted in the department of Oral Medicine & Radiology in year 2010. It included panoramic radiographs of 410 subjects obtained for various reasons. Patient’s information such as name, age, gender, indication of OPG was recorded. All images which were of non informative and faulty were excluded from the study. All images were taken with single digital Care stream 8000 (Kodak OPG machine). Results thus obtained were tabulated and subjected to statistical analysis using chi square test. P value<0.05 was considered significant.

**RESULTS**

Table I shows that out of 410 subjects whose OPG were taken, incidental findings were seen in 200 patients with prevalence rate of 50%. Table II shows that it consisted of 200 patients (males- 90, females -110). The difference was non significant (P>0.01). The present study comprised of patients ranged from 18 to 58 years of age. The mean age of males was 35.2 years and females 36.4 years. The difference was non significant (P>0.01) (Table III).

Graph I shows that following incidental findings were recorded such as elongated styloid process (25%), maxillary sinus pathology (10%), foreign bodies (5%), soft tissue calcification (12%), dental anomalies (7%) and TMJ disorders (2%). Most common finding was elongated styloid process. The difference was significant (P<0.05). Graph II shows that unilateral 13% and bilateral 12% of styloid process showed elongation. Graph III shows that retention pseudocyst was seen in 5%, sinus opacification in 2% and mucosal thickening was seen in 3% of cases. Graph IV shows that under soft tissue calcifications most commonly seen was tonsillolith (4%), phlebolith (4%), vascular calcification (3%) and sialolith (1%). Graph V shows that common dental anomalies were supernumerary teeth (2%), microdontia (3%), root dilacerations and external root resorption in 1% of all cases. Graph VI shows commonly seen TMJ disorders such as cystic lesions and degenerative joint diseases in 1% of all cases.

**Table I Prevalence of Incidental findings**

Total	Prevalence	Percentage
410	200	50%

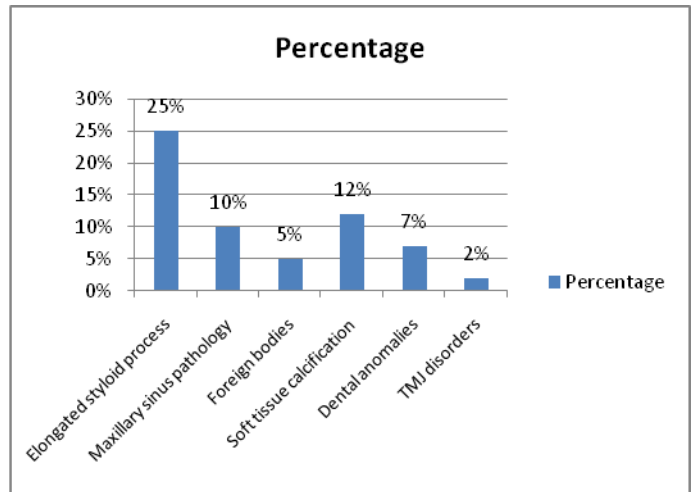
**Table II Distribution of patients**

Males	Females	P value
90	110	1

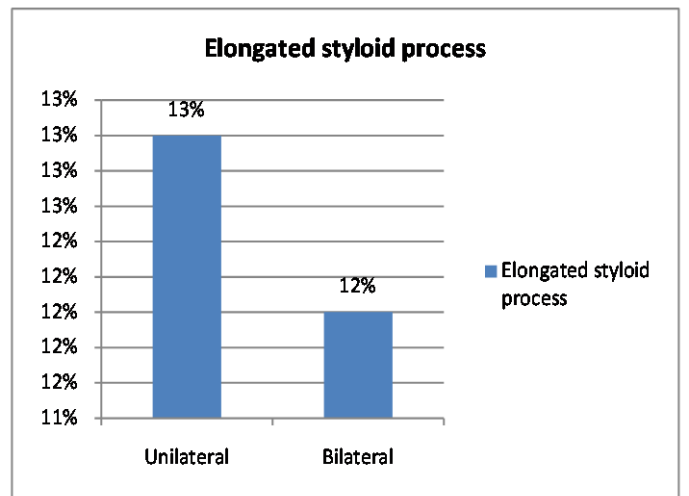
**Table III Mean age distribution of patients**

Males	Females	P value
35.2 years	36.4 years	0.1

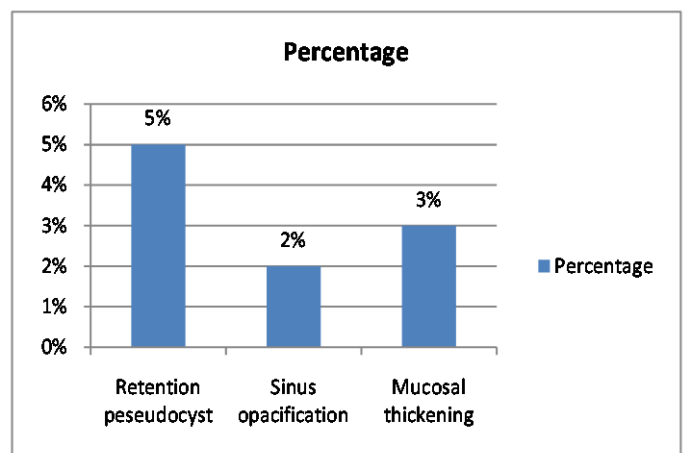
**Graph I Incidental findings**



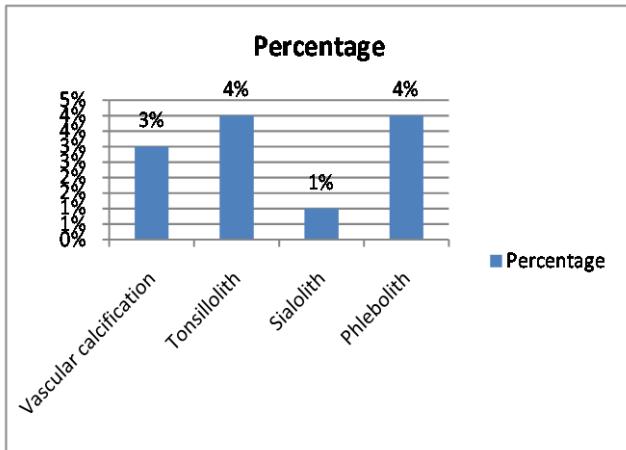
**Graph II Elongated styloid process**



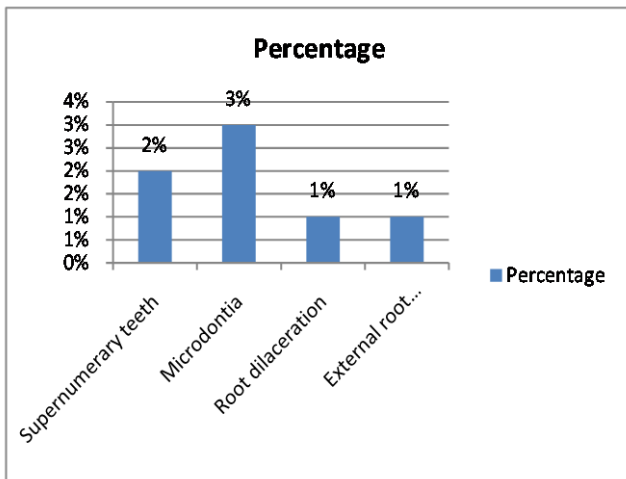
**Graph III Maxillary sinus pathology**



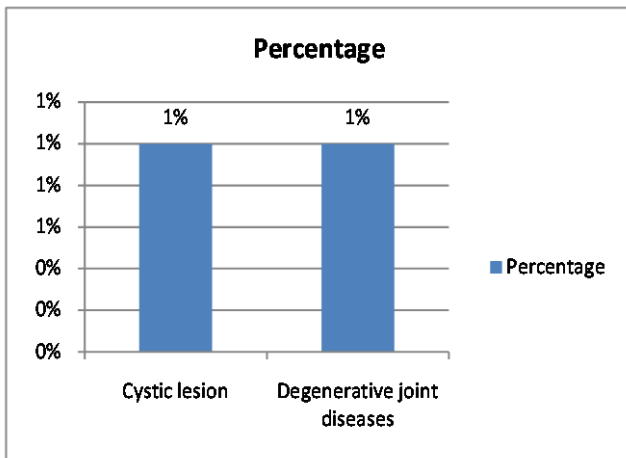
**Graph IV** Soft tissue calcification



**Graph V** Dental anomalies



**Graph VI** TMJ disorders



**DISCUSSION**

Panoramic radiograph is commonly advised extraoral radiograph in dentistry. It is indicated when there is need to examine larger area, cyst, tumors, TMJ disorders, sinus pathology and fractures etc. It is preferred over full moth radiographs as it offers less patient exposure as compared to full moth radiographs. The present study evaluated all panoramic radiographs obtained due to various reasons in 2015 to see incidental findings.

In our study, the prevalence rate of 50% was seen with incidental finding out of 410 OPG. However Roopashri<sup>4</sup> in 2012 reported 64% of findings. The slight less prevalence may be due to less number of examined panoramic radiographs in our study. Graph I shows that following incidental findings were recorded such as elongated styloid process (25%), maxillary sinus pathology (105), foreign bodies (5%), soft tissue calcification (12%), dental anomalies (7%) and TMJ disorders (2%). Similar findings were seen in study by Shaik et al.<sup>5</sup> They also reported radicular cysts and fractures in their study. We reported that elongated styloid process was seen in unilateral (13%) and bilateral (12%) of cases. Our results are in agreement with the study by Sudhakara Reddy et al.<sup>6</sup>

We reported retention pseudocyst in 5%, sinus opacification in 2% and mucosal thickening in 3% of cases. Similar results were seen in study of Mandian et al.<sup>7</sup> The most commonly seen soft tissue calcification was tonsillolith (4%), phlebolith (4%), vascular calcification (3%) and sialolith (1%). However Freidlander<sup>8</sup> reported most commonly seen soft tissue calcification was sialolith.

In our study, common dental anomalies were supernumerary teeth (2%), microdontia (3%), root dilacerations and external root resorption in 1% of all cases. Commonly seen TMJ disorders such as cystic lesions and degenerative joint diseases in 1% of all cases. Our results are in agreement with Griniatsos.<sup>9</sup>

**CONCLUSION**

Panoramic radiograph is a preferred routine diagnostic tool for the evaluation of large lesions, cysts, tumors etc. The additional advantage is incidental findings which may remain undetected if other radiographs would be taken. Thus it can be useful in detecting hidden findings.

**REFERENCES**

1. Pharoah, M. In: White SC PM, editor. Oral Radiology: Principles and Interpretation. St Louis, Missouri: Elsevier Mosby. 2013; 257-69.
2. Alpoz, E., Akar, G.C., Celik, S., Govsa, F. and Lomcali, G. Prevalence and pattern of stylohyoid chain complex patterns detected by panoramic radiographs among Turkish population. Surgical and radiologic anatomy SRA. 2014; 36: 39-46.
3. Bondemark, L., Jeppsson, M., Lindh-Ingildsen, L. and Rangne, K. Incidental findings of pathology and abnormality in pretreatment orthodontic panoramic radiographs. The Angle orthodontist. 2006; 76: 98-102.

4. Roopashri, G., Vaishali, M.R., David, M.P. and Baig, M. Evaluation of elongated styloid process on digital panoramic radiographs. *The journal of contemporary dental practice*.2012; 13: 618-22.
5. Shaik, M.A., Naheeda, Kaleem S.M., Wahab A, Hameed S. Prevalence of elongated styloid process in Saudi population of Aseer region. *European journal of dentistry*.2013; 7: 449-54.
6. Sudhakara Reddy, R., Sai Kiran, C., Sai Madhavi, N., Raghavendra, M.N. and Satish, A. Prevalence of elongation and calcification patterns of elongated styloid process in south India. *Journal of clinical and experimental dentistry*. 2013; 5: 30-5.
7. Mandian, M. and Tadinada, A. Incidental findings in the neck region of dental implant patients: a comparison between panoramic radiography and CBCT. *Journal of the Massachusetts Dental Society*. 2014; 63: 42-5.
8. Friedlander, A.H. Atheromas on panoramic radiographs often denote stenotic lesions and portend adverse vascular events. *Oral surgery, oral medicine, oral pathology, oral radiology, and endodontics*, 2007; 104: 451-2.
9. Griniatsos, J., Damaskos, S., Tsekouras, N., Klonaris, C. and Georgopoulos, S. Correlation of calcified carotid plaques detected by panoramic radiograph with risk factors for stroke development. *Oral surg, oral med, oral pathol, oral radio, and endod*. 2009; 108: 600-3.

**Source of support:** Nil

**Conflict of interest:** None declared

This work is licensed under CC BY: *Creative Commons Attribution 3.0 License*.