

## Original Research

### Exploring the reliability and accuracy of gonial angle beyond traditional methods

Mayma Nathasha M<sup>1</sup>, Yuvapriya P<sup>2</sup>, Jeyameera RR<sup>3</sup>, Madumitha Nandha<sup>4</sup>, Sukanya R<sup>5</sup>

<sup>1,4</sup>Assistant Professor, <sup>2,3</sup>Intern, <sup>5</sup>Associate Professor, Sathyabama Dental College and Hospital, Chennai, India

#### ABSTRACT:

**Objective:** The objective of the study is to assess the accuracy and reliability of gonial angle measurement using lateral cephalogram and CBCT of adult patients with skeletal class I malocclusion. **Materials & methods:** A retrospective study was conducted in patients with skeletal class I malocclusion using lateral cephalogram and CBCT images of mandible. One way ANOVA was used to find the mean difference of gonial angle between the cephalogram, left side CBCT and right side CBCT. Paired t test was used to find the mean difference of gonial angle between cephalogram and CBCT values. Independent sample t test was used to find the mean difference of gonial angle between the left and right side CBCT. **Results:** No statistically significant difference was found between the gonial angle measured using cephalogram and CBCT, on comparing the gonial angle measured by cephalogram and CBCT left side and on comparing the gonial angle measured by CBCT right and left sides. A statistically significant difference was found on comparing the gonial angle measured by cephalogram and CBCT right side (p value 0.041). **Conclusion:** Both lateral cephalogram and CBCT imaging techniques are similar in assessing the gonial angle in class I malocclusions. In cases where there are other indications for CBCT imaging, the gonial angle can be measured from it, without necessitating additional radiographs.

**Keywords:** Gonial angle, Lateral cephalogram, CBCT, Imaging techniques, Orthodontic diagnosis

Received: 13 September, 2024

Accepted: 17 October, 2024

**Corresponding author:** Mayma Nathasha M, Assistant Professor, Sathyabama Dental College and Hospital, Chennai, India

**This article may be cited as:** M Mayma N, P Yuvapriya, RR Jeyameera, Nandha M, R Sukanya. Exploring the reliability and accuracy of gonial angle beyond traditional methods. J Adv Med Dent Scie Res 2024; 12(11):21-26.

#### INTRODUCTION

The anthropometric term "gonion," comes from a Greek word, meaning "the lowest, most posterior, most lateral point of the angle."<sup>1</sup> The angle at which the posterior border of the ramus and the lower border of the mandibular body meet is called as the gonial angle (mandibular angle), which in cephalometry, is formed by the intersection of two lines drawn tangent to the inferior border of mandible and the posterior border of ramus.<sup>2</sup> It can be useful in both cephalometry and forensic science.<sup>3</sup> Assessment of gonial angle is a crucial aspect of evaluating mandibular morphology and diagnosing various skeletal malocclusions as it provides valuable insights into facial growth patterns, jaw development, and functional orthodontic relationships.<sup>4</sup> Accurate measurement of this angle is essential for treatment planning and prognosis in orthodontics and maxillofacial surgery.

A larger gonial angle is often associated with a more convex facial profile, while a smaller angle indicates a

more prominent jaw and a straighter facial profile. In cases of high gonial angle, there will be downward and backward rotation of mandible. Conversely, there will be upward and backward rotation of mandible in low angle cases. Further it also reflects the effectiveness of orthodontic interventions. Typically, males have a more acute gonial angle compared to females, and the angle tends to decrease with age due to bone remodelling and tooth loss.<sup>5</sup>

Cephalograms give an insight on the three-dimensional relation of the upper and lower jaws conferring to the skull base, the relationship between the upper and lower jaws, and the inclination of the teeth. However, the bilateral visualization of gonial angle is especially difficult due to the superimposition and shadow formation in the radiographs, leading to insufficiency and possible inaccuracy in cephalometric analysis.<sup>6</sup>

Lateral cephalometry, orthopantomography (OPG), and cone-beam computed tomography (CBCT) are commonly used for cephalometry. However, each of

them have their distinct pros and cons. Lateral cephalograms are considered as a "gold standard" for orthodontic diagnosis but it has geometric distortion and overlapping of anatomical structures. This may often lead to inaccuracies in analysis.<sup>7,8</sup> On the other hand, panoramic radiography may provide a broad visualization of the dental and surrounding structures, however, it still lacks a three-dimensional visualization needed for accurate measurements [5]. In this regard, CBCT offers a high-resolution three-dimensional (3D) image, free from distortion. This allows for more accurate cephalometric analysis.<sup>9,10</sup> Therefore, it is necessary to analyse if CBCT offers better accuracy in gonial angle measurement. However, CBCT typically involves a higher radiation dose compared to lateral cephalograms, raising concerns, especially for paediatric patients. Thus, while CBCT enhances diagnostic capabilities, the balance between image quality and radiation exposure remains a critical consideration in orthodontic practice.

In the past, gonial angle has been measured using two-dimensional imaging methods - lateral cephalograms and panoramic radiographs, as the latter can eliminate the disadvantage of superimposition. In the recent years, Cone beam computed tomography (CBCT) which is a 3D imaging technique, has unlocked a pathway in enhancing the diagnosis and treatment planning in Orthodontics to overcome the inefficiency of the two-dimensional records.<sup>11</sup> It provides additional information compared to normal radiography described earlier.<sup>12</sup>

Previous authors have noted that panoramic radiograph and lateral cephalogram have good agreement in measurements.<sup>13, 14, 15</sup> However, there is a lacuna in the literature regarding comparability of these radiographs and CBCT in terms of measuring the gonial angle. Therefore, the aim of this study is to assess the accuracy and reliability of gonial angle measurement using lateral cephalogram and CBCT of adult patients with skeletal class I malocclusion.

## MATERIALS AND METHODS

A retrospective study was conducted in patients with skeletal class I malocclusion using lateral cephalogram and CBCT images of mandible, in Sathyabama Dental College and Hospital, Chennai. The study design was approved by the Institutional Review Board, Sathyabama Dental College and Hospital (----). Lateral Cephalogram images were acquired with a Orthophos XG X-ray unit with an x-ray energy of 73kVp and exposure time of 9.4 seconds. CBCT images were acquired using X MIND trium machine with an energy of 90kVp and exposure time of 10 seconds were used for this study.

**Sample size determination:** The sample size was calculated using G Power software with a power of 95%,  $\alpha$  error of 5% and  $P < 0.05$ . The estimated sample size was 42 with 21 in each group.

**The inclusion criteria:** Skeletal class I malocclusion and in the age group 18-30 years.

**The exclusion criteria:** Skeletal malocclusions, history of trauma, previous facial/mandibular surgery, syndromes affecting the face and jaw and facial asymmetry cases.

**Methodology:** The class I skeletal patterns were assessed by SNA (Position of maxilla to skull base), SNB (Position of mandible to skull base) and ANB angles (Relationship of maxilla and mandible to each other). CBCT images were grouped according to this criterion. Gonial angle was measured in CBCT images of 21 skeletal class I patients. The landmarks were identified and the gonial angle was measured at the point of intersection of the plane tangential to the lower border of the mandible and that tangential to the distal border of the ascending ramus and the condyle. The data was tabulated and submitted for statistical analysis

## Statistical Analysis

Statistical analysis was done using SPSS IBM software version 25. Descriptive statistics was used to identify the mean and standard deviation. One way ANOVA was used to find the mean difference of gonial angle between the cephalogram, left CBCT and right CBCT. Paired t test was used to find the mean difference of gonial angle between cephalogram and CBCT values. Independent sample t test was used to find the mean difference of gonial angle between the left and right CBCT. P value  $< 0.05^*$  was considered as statistically significant.

## RESULTS

The study sample consisted of CBCT and Cephalograms of 42 patients. No statistically significant difference was found between the gonial angle measured using cephalogram and CBCT (right and left) p value 0.075 (Table I) There was a statistically significant difference found on comparing the gonial angle measured by cephalogram and CBCT right p value 0.041\*. (Table II) There was no statistically significant difference found on comparing the gonial angle measured by cephalogram and CBCT left p value 0.057. (Table II) There was no statistically significant difference found on comparing the gonial angle measured by CBCT right and left p value 0.645 (Table II).

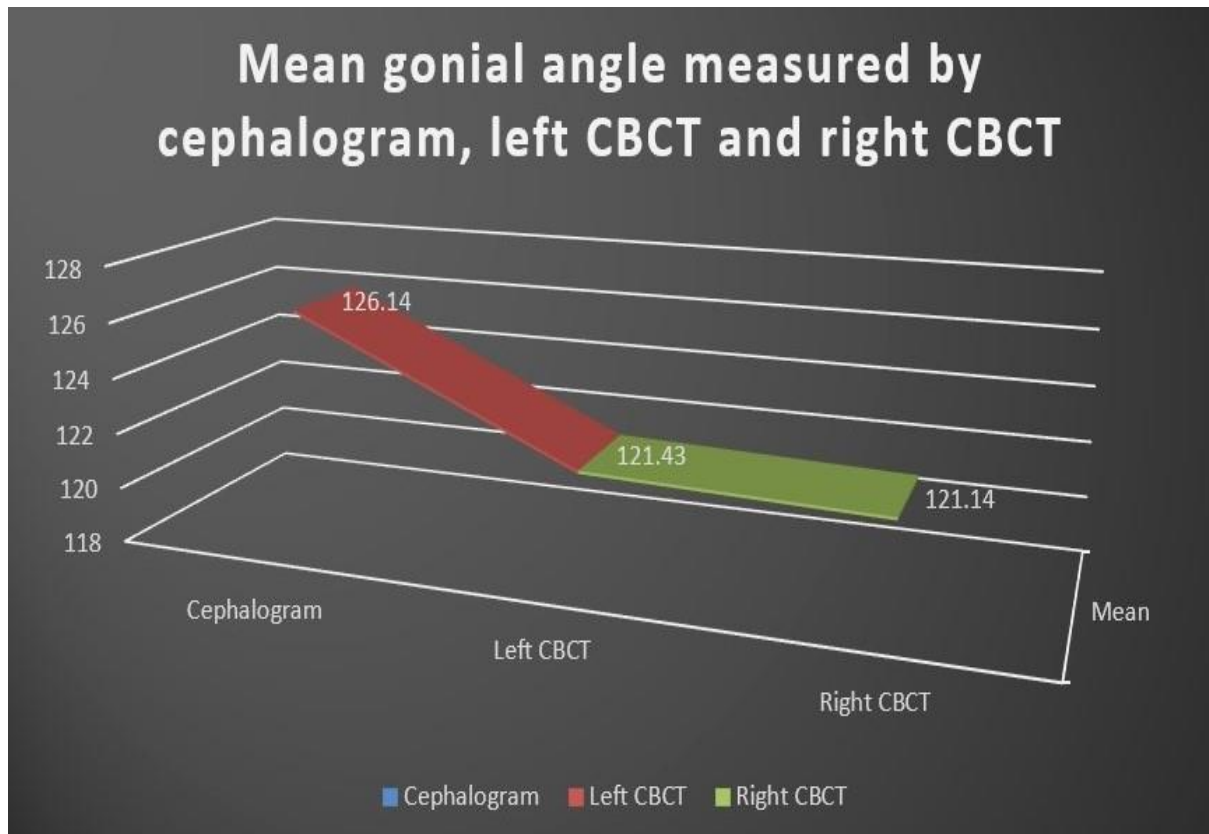
Graph 1 represents the distribution of the mean gonial angle measured by cephalogram, left CBCT and right CBCT, graph 2 representing the distribution of the mean gonial angle measured by cephalogram and left CBCT and graph 3 representing the distribution of the mean gonial angle measured by cephalogram and right CBCT.

**TABLE I: Difference in the gonial angle measured using cephalogram and the Cone Beam Computed Tomography (Right and left)**

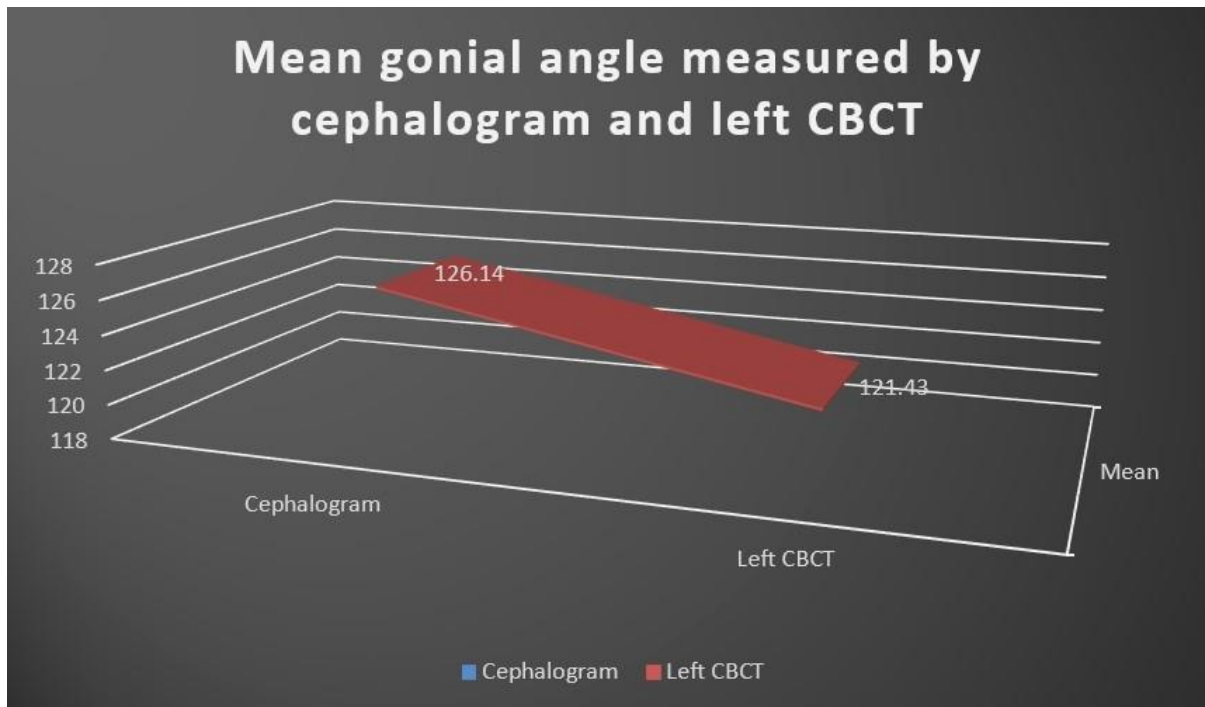
	Mean±SD	Minimum	Maximum	95% Confidence Interval		P value (One way ANOVA)
				Lower Bound	Upper Bound	
<b>Cephalogram</b>	126.14±7.458	108	140	122.75	129.54	0.075
<b>Left CBCT</b>	121.43±8.140	103	140	117.72	125.13	
<b>Right CBCT</b>	121.14±7.850	103	140	117.57	124.72	

**TABLE II: Difference in the gonial angle measured by various techniques**

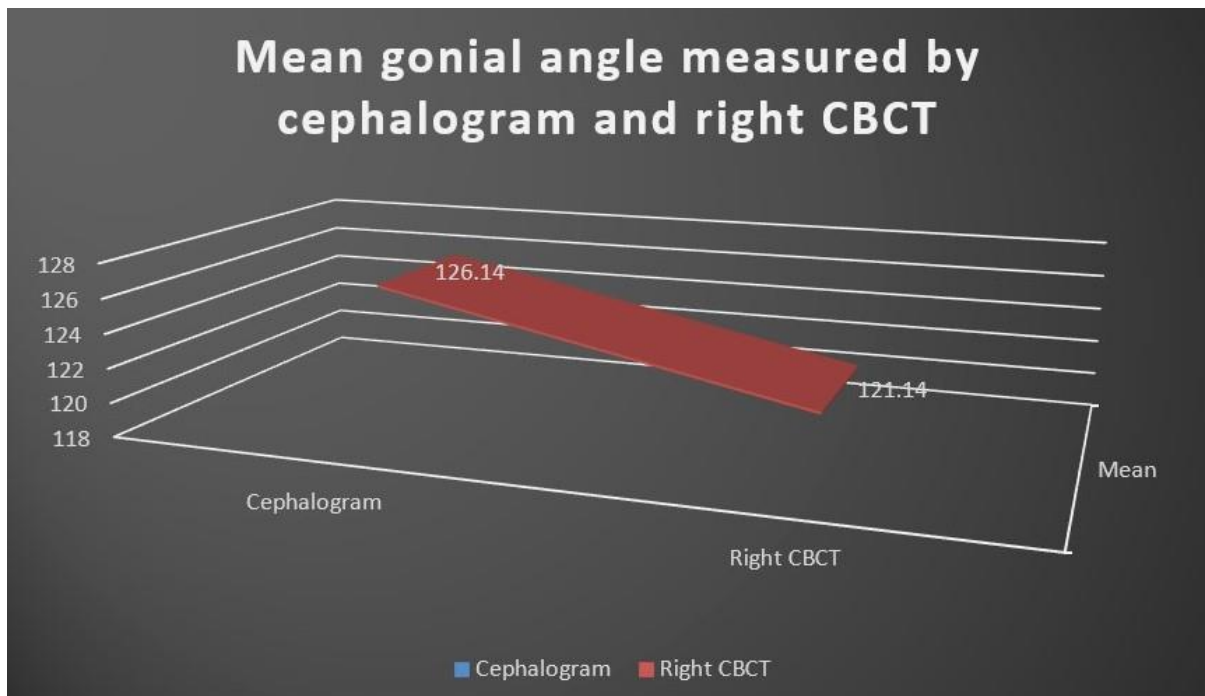
	Mean	SD	P value
<b>Cephalogram</b>	126.14	7.458	<b>0.041*</b>
<b>Right CBCT</b>	121.14	7.85	
<b>Cephalogram</b>	126.14	7.458	0.057
<b>Left CBCT</b>	121.43	8.14	
<b>Right CBCT</b>	121.14	7.85	0.908
<b>Left CBCT</b>	121.43	8.14	



**Graph 1: Line graph representing the distribution of the mean gonial angle measured by cephalogram, left CBCT and right CBCT**



**Graph 2: Line graph representing the distribution of the mean gonial angle measured by cephalogram and left CBCT**



**Graph 3: Line graph representing the distribution of the mean gonial angle measured by cephalogram and right CBCT**

### DISCUSSION

The aim of this study is to assess the accuracy and reliability of gonial angle measurement using lateral cephalogram and CBCT of adult patients with skeletal class I malocclusion. The results of the study have indicated that the gonial angle measured by lateral cephalogram and CBCT were generally comparable. This implies that both imaging modalities can be interchangeably used to assess the gonial angle in

Class I malocclusion cases. However, a statistical difference is observed between cephalogram and the right-side CBCT. The reason may be due to possible discrepancy in measurements on that side. Many factors such as patient positioning, anatomical asymmetry and variation in handwriting recognition can influence this difference. However, these images are better seen on CBCT than on radiographs. However, the left side does not show any statistical

variation between the two methods. This supports the overall reliability of both techniques for clinical use, although CBCT may provide more detailed and accurate images of anatomical structures without overlapping them.

It has been reported in the literature that there have been differences in the cephalometric measurements with change in imaging modality. Farhadian et al., (2012)<sup>16</sup> have shown that larger gonial angle and longer ramus height in CBCT-generated cephalograms are seen relative to conventional lateral cephalograms. Park et al., (2012)<sup>11</sup> have shown similarity in measurement of cephalometric values in most of the parameters but not in gonial angle. They have attributed the differences due to discrepancies in manual measurements. Markic et al., (2015)<sup>18</sup> have compared various imaging modalities and found good comparability and inter-rater reliability amongst them. War Firdous et al assessed the reliability of panoramic radiographs to determine gonial angle and found that the gonial angle value determined in panoramic radiograph was found to be different compared with the lateral cephalogram using Tweed's, Steiner's and Down's methods.<sup>11</sup> Bakan et al used cone-beam computed tomography (CBCT) images to assess the gonial angle and examine its relationship to age and gender and observed no correlation between age and gonial angle in any of the age groups.<sup>12</sup> Hence there is inconclusive evidence on the issue, necessitating further studies.

In this study, as suggested, the difference may be due to measuring discrepancy, but for which the accuracy is similar in all groups. While CBCT has higher radiation dose compared to conventional radiographs, due to similarity in accuracy, conventional radiographs can be preferred.

The finding of this study has a clinical significance as the samples were of class I malocclusions. The idea was to assess the utility in class I cases only to assess the difference in imaging modalities. However, previous authors have done studies on other malocclusions also. Studies indicate that the mean gonial angle measured from lateral cephalograms is typically higher than that from panoramic radiographs, with values reported at 127.50° and 125.49°, respectively, demonstrating a strong correlation between the two methods ( $\rho = 0.945$ ).<sup>19</sup> Variation between different imaging techniques is due to the inherent characteristics of each imaging technique, so it is important for orthodontists to understand these variations.<sup>20, 21</sup> This is to be able to accurately diagnose and plan dental treatment.

## CONCLUSION

The following were the conclusions drawn from the study: There was no statistically significant difference found between the gonial angle measured using cephalogram and CBCT (right and left). There was a statistically significant difference on comparing the gonial angle measured by cephalogram and CBCT

right side. There was no statistically significant difference on comparing the gonial angle measured by cephalogram and CBCT left side. To conclude, both techniques are similar in assessing the gonial angle in class I malocclusions and can be used interchangeably. In cases where there are other indications for CBCT, the gonial angle can be measured from it, without necessitating additional radiographs. In cases where economical assessment is needed, radiography appears to be sufficient.

## REFERENCES

1. Jensen E, Palling M. The gonial angle: A survey. *American Journal of Orthodontics*. 1954 Feb 1;40(2):120-33.
2. Javidi P, Ostovarrad F, Shekarbaghani SA. Comparative analysis of the gonial angle on panoramic and lateral cephalometric radiographs. *Journal of Dentomaxillofacial Radiology, Pathology and Surgery*. 2019 Mar 10;8(1):31-6.
3. Upadhyay RB, Upadhyay J, Agrawal P, Rao NN. Analysis of gonial angle in relation to age, gender, and dentition status by radiological and anthropometric methods. *Journal of forensic dental sciences*. 2012 Jan;4(1):29.
4. Firdous W, Mohammad M. Reliability of panoramic radiograph to determine gonial angle. Adil S, Awan MH, Khan I, Syed K. Comparison of the gonial angle measurements on Lateral Cephalogram and both hemispheres of Orthopantomogram. *Pakistan Orthodontic Journal*. 2015;7(2):48-50.
5. Al-Dawoody AD. Does high gonial angle increases the risk of mandibular angle fracture? A digital orthopantomographic study. *J Clin Exp Dent*. 2022 Dec 1;14(12):e994-e999.
6. Adil S, Awan MH, Khan I, Syed K. Comparison of the gonial angle measurements on Lateral Cephalogram and both hemispheres of Orthopantomogram. *Pakistan Orthodontic Journal*. 2015;7(2):48-50.
7. Chung EJ, Yang BE, Park IY, Yi S, On SW, Kim YH, Kang SH, Byun SH. Effectiveness of cone-beam computed tomography-generated cephalograms using artificial intelligence cephalometric analysis. *Scientific Reports*. 2022 Nov 29;12(1):20585.
8. Manuel, Estuardo, Bravo, Calderón., Marco, Vinicio, Bernal, Pinos., Karina, Viviana, Morocho, Llivizaca. 4. comparison of cephalometric measurements with conventional lateral cephalic 2D and reconstructed lateral cephalic of CBCT. *International Journal of Health Sciences (IJHS)*, (2022). doi: 10.53730/ijhs.v6ns3.8813
9. Chung EJ, Yang BE, Park IY, Yi S, On SW, Kim YH, Kang SH, Byun SH. Effectiveness of cone-beam computed tomography-generated cephalograms using artificial intelligence cephalometric analysis. *Scientific Reports*. 2022 Nov 29;12(1):20585.
10. Benedetta, Baldini., Davide, Cavagnetto., Giuseppe, Iaselli., Chiarella, Sforza., Gianluca, M., Tartaglia. (2022). 5. Cephalometric measurements performed on CBCT and reconstructed lateral cephalograms: a cross-sectional study providing a quantitative approach of differences and bias. *BMC Oral Health*, doi: 10.1186/s12903-022-02131-3
11. Park CS, Park JK, Kim H, Han SS, Jeong HG, Park H. Comparison of conventional lateral cephalograms with

- corresponding CBCT radiographs. *Imaging science in dentistry*. 2012 Dec 1;42(4):201-5.
12. Gribel BF, Gribel MN, Frazão DC, McNamara Jr JA, Manzi FR. Accuracy and reliability of craniometric measurements on lateral cephalometry and 3D measurements on CBCT scans. *The Angle Orthodontist*. 2011 Jan 1;81(1):26-35.
  13. Radhakrishnan PD, Varma NK, Ajith VV. Dilemma of gonial angle measurement: Panoramic radiograph or lateral cephalogram. *Imaging science in dentistry*. 2017 Jun 1;47(2):93-7.
  14. Ozkan TH, Arici S, Ozkan E. The better choice for measuring the gonial angle of different skeletal malocclusion types: orthopantomograms or lateral cephalograms. *Med-Science*. 2019 Jan;8:93-6.
  15. Shahabi M, Ramazanzadeh BA, Mokhber N. Comparison between the external gonial angle in panoramic radiographs and lateral cephalograms of adult patients with Class I malocclusion. *J Oral Sci*. 2009; 51:425–429.
  16. Farhadian N, Miresmaeili A, Mahvelati R, Sajedi A. A comparative cephalometric analysis between conventional and CBCT generated lateral cephalograms. *Iranian Journal of Orthodontics*. 2012 Jun 1;7(1):22-6.
  17. Markic G, Müller L, Patcas R, Roos M, Lochbühler N, Peltomäki T, Karlo CA, Ullrich O, Kellenberger CJ. Assessing the length of the mandibular ramus and the condylar process: a comparison of OPG, CBCT, CT, MRI, and lateral cephalometric measurements. *European journal of orthodontics*. 2015 Feb 1;37(1):13-21.
  18. Park SH, Kim YJ, Lee SH, Kim CC, Jang KT. The simple regression model of gonial angles: comparison between panoramic radiographs and lateral cephalograms. *Journal of the Korean Academy of Pediatric Dentistry*. 2017 May 25;44(2):129-37.
  19. Sharma P, Shrivastava S. Comparative Evaluation of the External Gonial Angle in Adults Patients with Class I Malocclusion from Panoramic Radiographs and Lateral Cephalograms. *Journal of Research in Medical and Dental Science*. 2020 May;8(3):157-62.
  20. Yousefi F, Mollabashi V, Bahmani S, Farhadian M. Comparison of Gonial Angle and Alveolar Bone Height Changes in Panoramic and Lateral Cephalometry Radiography in Growing Patients. *Avicenna Journal of Dental Research*. 2022 Mar 29;14(1):33-8.