

# Review Article

## Calculi – A Review

Karthik R<sup>1</sup>, Mohan N<sup>2</sup>, Ravikumar PT<sup>3</sup>, Saramma Mathew Fenn<sup>4</sup>, Kumar<sup>5</sup>

<sup>1</sup>Reader, <sup>2</sup>Professor and Head, <sup>3</sup>Associate professor, <sup>4,5</sup>Senior Lecturer

Department of Oral Medicine and Radiology, Vinayaka Missions Sankarachariyar Dental College, Salem, Vinayaka Missions Research Foundation (Deemed to be University), Tamil Nadu, India

### ABSTRACT:

A calculus (plural *calculi*), often called a stone, is a concretion of material, usually mineral salts, that forms in an organ or duct of the body. Small sized calculi remain completely asymptomatic and are poorly localised by conventional radiographic techniques unless they become large.

**Key words:** Staghorn, Sialolith, struvite, xanthine, Uric acid, Gall stone, Phlebolith.

Received: 18 April 2018

Accepted: 29 May 2018

**Corresponding author:** Dr. Karthik R, Reader, Department of Oral Medicine and Radiology, Vinayaka Missions Sankarachariyar Dental College, Salem, Vinayaka Missions Research Foundation (Deemed to be University), Tamil Nadu, India

**This article may be cited as:** R Karthik, N Mohan, PT Ravikumar, Fenn SM, Kumar. Calculi – A Review. J Adv Med Dent Scie Res 2018;6(7):12-16.

### Introduction:

Calculi is a concretion of material, usually mineral salts, that forms in an organ or duct of the body. The process of formation of calculi is referred to as lithiasis.

### Types of calculi

Organ	Name
Salivary gland	Sialolith
Maxillary sinus	Antrolith
Nasal cavity	Rhinolith
Tonsil	Tonsillolith
Kidney	Kidney stones or Nephroliths
Gall Bladder	Gall stones
stomach	Gastrolith
Veins	Phlebolith
Teeth	Odontolith

### Sialolith :

The most common site of calculi formation is the submandibular salivary gland – 80% (60–90%). Approximately 10–20% (5–20%) of stones are located in

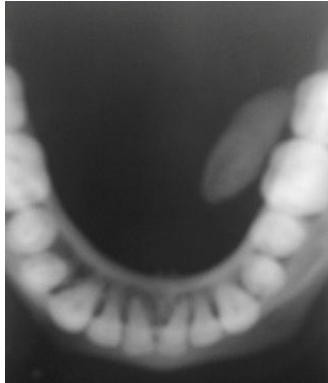the parotid gland, and 1–5% in the sublingual gland . In 25% of cases, the stones are multiple.<sup>[1]</sup>

Submandibular gland is the most common place for calculi formation because it produces a particularly viscous, mucous and more alkaline saliva, with a relatively high concentration of hydroxyapatites and phosphates. This predisposes to the precipitation of salts<sup>[1]</sup>. Moreover, the opening of the main salivary duct of the submandibular gland (Wharton’s duct) is narrower than the diameter of the whole duct and the tortuous nature of the duct and ascends towards its opening, which is also conducive to saliva retention .

As much as 85% of submandibular gland stones are located in Wharton’s duct, while the remaining 15% in gland parenchyma .Calculi situated in glandular parenchyma do not tend to cause significant clinical symptoms .It is rare for a large stone located in Wharton’s duct not to produce any symptoms of inflammation or pain<sup>[2]</sup>. The most common site of Wharton’s duct for calculi formation is its proximal segment, in which the duct wraps around the posterior edge of the mylohyoid muscle, at a steep angle, where 35% of the deposits are located, 30 % of the calculi are located near the opening of the submandibular duct, and 20% in its medial part.

Mature large sialolith can be localised by Mandibular occlusal radiograph.(Fig 1)

Fig 1: Mandibular occlusal radiograph revealing a Submandibular sialolith

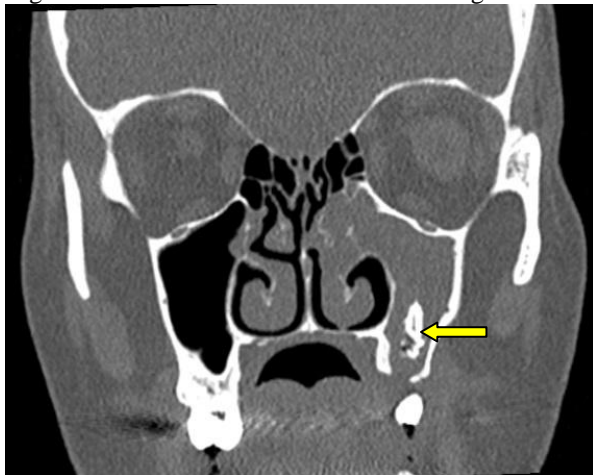


**Antrolith :**

An antrolith is a calcified mass within the maxillary sinus. The origin of the nidus of calcification may be extrinsic (foreign body in sinus) or intrinsic (stagnant mucus, fungal ball).

Most antroliths are small and asymptomatic. Antrolith of the paranasal sinuses are rare entity which are usually asymptomatic, caused by calcification of a nidus and are detected incidentally on radiological examinations. Larger ones may present as sinusitis with symptoms like pain and discharge.

Fig 2 . Coronal section of CT Scan revealing Antrolith

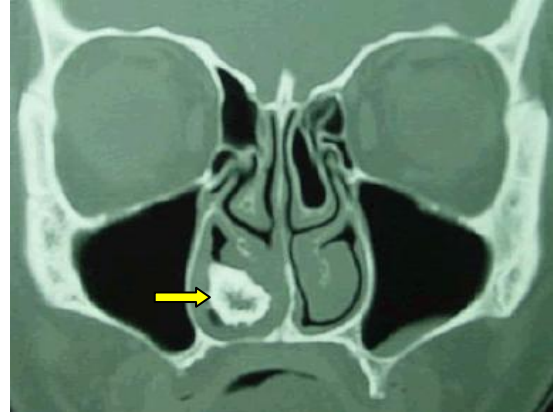


**Rhinolith**

Rhinolith was first reported by Bartholin in 1654. Rhinoliths are believed to be formed by the deposition of magnesium, iron, calcium and phosphorus around a core, which can be intranasal endogenous or exogenous foreign material.<sup>[3]</sup> The endogenous central core could be due to a blood clot, mucus or bone fragment following trauma. Rhinoliths may be found incidentally during routine clinical examination usually in the floor of the nasal cavity located halfway between the posterior and anterior nares. Rhinoliths do not show

any symptoms at an initial stage but may cause minor symptoms due to their gradual increase in size. However, with significant increase in the size of the rhinolith, nasal discharge and obstruction are observed with the consequent misdiagnosis as rhinitis or sinusitis. In addition to the unilaterality of the symptoms, other presentations of rhinoliths include epistaxis and erosion of the nasal septum and the medial wall of maxillary sinus and perforation of hard palate.

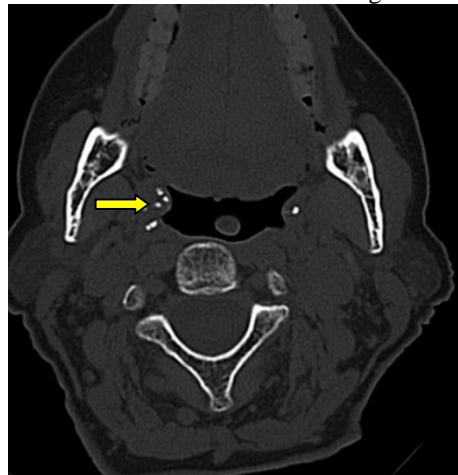
Fig 3. Coronal section of CT Scan showing Rhinolith



**Tonsilloliths**

Tonsilloliths, also known as tonsil (or tonsillar) stones or calculi, are clusters of calcifications that form in tonsillar crypts, within the tonsils or around them.

Fig 4. Axial section of CT scan showing Tonsillolith



**Nephrolith :**

A small stone may pass without causing symptoms. If a stone grows to more than 5 millimeters (0.2 in) it can cause blockage of the ureter resulting in severe pain in the lower back or abdomen. <sup>[8]</sup>A stone may also result in blood in the urine, vomiting, or painful urination. Risk factors include hyperparathyroidism, obesity, gout, calcium supplements, inadequate drinking of sufficient amount of water. Stones are typically classified by their location: nephrolithiasis (in the kidney), ureterolithiasis (in the ureter), cystolithiasis (in the bladder), or by what

they are made of (calcium oxalate, uric acid, struvite, cystine)

Type of kidney stone	Population	Color	Sensitivity
Calcium oxalate	80 %	Black/dark brown	Radiopaque
struvite	10-15 %	Dirty white	Radiopaque
Calcium phosphate	5- 10 %	Dirty white	Radiopaque
Uric acid	5- 10 %	Yellow/reddish brown	Radiolucent
cystine	1-2 %	Pink/yellow	Radiopaque
xanthine	Extremely rare	Brick red	Radiolucent

### Calcium-containing stones

The most common type of kidney stones worldwide contains calcium oxalate either alone or in combination with calcium phosphate in the form of apatite or brushite. Factors that promote the precipitation of oxalate crystals in the urine, such as primary hyperoxaluria, are associated with the development of calcium oxalate stones. The formation of calcium phosphate stones is associated with conditions such as hyperparathyroidism and renal tubular acidosis.<sup>[6]</sup>

Oxaluria is increased in patients with certain gastrointestinal disorders including inflammatory bowel disease such as Crohn disease or patients who have undergone resection of the small bowel or small bowel bypass procedures. Oxaluria is also increased in patients who consume increased amounts of oxalate (found in vegetables and nuts). Primary hyperoxaluria is a rare autosomal recessive condition which usually presents in childhood. Calcium oxalate crystals in urine appear as 'envelopes' microscopically. They may also form 'dumbbells'.

### Struvite stones

About 10–15% of urinary calculi are composed of struvite (ammonium magnesium phosphate,  $\text{NH}_4\text{MgPO}_4 \cdot 6\text{H}_2\text{O}$ ). Struvite stones (also known as "infection stones", urease or triple-phosphate stones), form most often in the presence of infection by urea-splitting bacteria. Using the enzyme urease, these organisms metabolize urea into ammonia and carbon dioxide. This alkalizes the urine, resulting in favorable conditions for the formation of struvite stones. *Proteus mirabilis*, *Proteus vulgaris*, and *Morganellamorganii* are the most common organisms isolated; less common organisms include *Ureaplasmaurealyticum*, and some species of *Providencia*, *Klebsiella*, *Serratia*, and *Enterobacter*. These infection stones are commonly observed in people who have factors that predispose them to urinary tract infections, such as those with spinal cord injury and other forms of neurogenic bladder, ileal conduit urinary diversion, vesicoureteral reflux, and obstructive uropathies. They are also commonly seen in people with underlying metabolic disorders, such as idiopathic

hypercalciuria, hyperparathyroidism, and gout. Infection stones can grow rapidly, forming large calyceal staghorn (antler-shaped) calculi requiring invasive surgery such as percutaneous nephrolithotomy for definitive treatment.<sup>[7]</sup> Struvite stones (triple phosphate/magnesium ammonium phosphate) have a 'coffin lid' morphology by microscopy.<sup>[7]</sup>

### Uric acid stones

About 5–10% of all stones are formed from uric acid.<sup>[8]</sup> People with certain metabolic abnormalities, including obesity may produce uric acid stones. They also may form in association with conditions that cause hyperuricosuria (an excessive amount of uric acid in the urine) with or without hyperuricemia (an excessive amount of uric acid in the serum). They may also form in association with disorders of acid/base metabolism where the urine is excessively acidic (low pH), resulting in precipitation of uric acid crystals. A diagnosis of uric acid urolithiasis is supported by the presence of a radiolucent stone in the face of persistent urine acidity, in conjunction with the finding of uric acid crystals in fresh urine samples.<sup>[8]</sup> People with inflammatory bowel disease (Crohn's disease, ulcerative colitis) tend to have hyperoxaluria and form oxalate stones. They also have a tendency to form urate stones. Urate stones are especially common after colon resection.<sup>[8]</sup>

Uric acid stones appear as pleomorphic crystals, usually diamond-shaped. They may also look like squares or rods which are polarizable. Patients with hyperuricosuria can be treated with allopurinol which will reduce urate formation. Urine alkalization may also be helpful in this setting.<sup>[8]</sup>

### Other types

People with certain rare inborn errors of metabolism have a propensity to accumulate crystal-forming substances in their urine. For example, those with cystinuria, cystinosis, and Fanconis syndrome may form stones composed of cystine. Cystine stone formation can be treated with urine alkalization and dietary protein restriction. People afflicted with xanthinuria often produce stones composed of xanthine. People afflicted with adenine phosphoribosyltransferase deficiency may produce 2,8-dihydroxyadenine stones, alkaptonurics produce homogentisic acid stones, and iminoglycinurics produce stones of glycine, proline and hydroxyproline. Urolithiasis has also been noted to occur in the setting of therapeutic drug use, with crystals of drug forming within the renal tract in some people currently being treated with agents such as indinavir, sulfadiazine and triamterene.

### Gall stones :

The process of formation of gall stones in the gall bladder is referred to as Cholelithiasis. If gallstones migrate into the ducts of the biliary tract, the condition is referred to as choledocholithiasis, from the Greek *chol-* (bile) + *docho-* (duct) + *lith-* (stone) + *iasis-* (process).

Cholelithiasis is frequently associated with obstruction of the biliary tree, which in turn can lead to acute ascending cholangitis, from the Greek: chol- (bile) + ang- (vessel) + itis- (inflammation), a serious infection of the bile ducts. Gallstones within the ampulla of Vater can obstruct the exocrine system of the pancreas, which in turn can result in pancreatitis.<sup>[9]</sup>

### Composition:

Gallstones can vary in size and shape from as small as a grain of sand to as large as a golf ball. The gallbladder may contain a single large stone or many smaller ones. Pseudoliths, sometimes referred to as sludge, are thick secretions that may be present within the gallbladder, either alone or in conjunction with fully formed gallstones. The composition of gallstones is affected by age, diet and ethnicity. In 1986, the gall stone research committee from the Japanese society of gastroenterology classified gall stones into three classes cholesterol, Pigment and rare stones.<sup>[10]</sup> Cholesterol stones were sub classified into pure cholesterol, combination and mixed stones, while pigment stones were further divided into calcium bilirubinate and black stones. On the basis of their composition, gallstones can be divided into the following types:

### Cholesterol stones

Cholesterol stones vary from light yellow to dark green or brown or chalk white and are oval, usually solitary, between 2 and 3 cm long, each often having a tiny, dark, central spot. To be classified as such, they must be at least 80% cholesterol by weight (or 70%, according to the Japanese-classification system). Between 35% and 90% of stones are cholesterol stones.<sup>[10]</sup>

### Bilirubin stones

Bilirubin ("pigment", "black pigment") stones are small, dark (often appearing black), and usually numerous. They are composed primarily of bilirubin (insoluble bilirubin pigment polymer) and calcium (calcium phosphate) salts that are found in bile. They contain less than 20% of cholesterol (or 30%, according to the Japanese-classification system). Between 2% and 30% of stones are bilirubin stones.<sup>[10]</sup>

### Mixed stones

Mixed ("Brown Pigment") stones typically contain 20–80% cholesterol (or 30–70%, according to the Japanese-classification system).<sup>[30]</sup> Other common constituents are calcium carbonate, palmitate phosphate, bilirubin and other bile pigments (calcium bilirubinate, calcium palmitate and calcium stearate). Because of their calcium content, they are often radiographically visible. They typically arise secondary to infection of the biliary tract which results in the release of  $\beta$ -glucuronidase (by injured hepatocytes and bacteria) which hydrolyzes bilirubin glucuronides and increases the amount of unconjugated

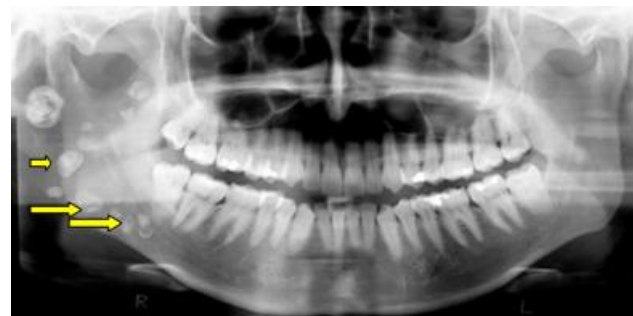bilirubin in bile. Between 4% and 20% of stones are mixed.<sup>[10]</sup>

Gallstones may be asymptomatic, even for years. These gallstones are called "silent stones" and do not require treatment. The size and number of gallstones present does not appear to influence whether people are symptomatic or asymptomatic. A characteristic symptom of gallstones is a gallstone attack, in which a person may experience colicky pain in the upper-right side of the abdomen, often accompanied by nausea and vomiting, that steadily increases for approximately 30 minutes to several hours. A person may also experience referred pain between the shoulder blades or below the right shoulder. These symptoms may resemble those of a "kidney stone attack". Often, attacks occur after a particularly fatty meal and almost always happen at night, and after drinking.<sup>[10]</sup> In addition to pain, nausea, and vomiting, a person may experience a fever. If the stones block the duct and cause bilirubin to leak into the bloodstream and surrounding tissue, there may also be jaundice and itching. This can also lead to confusion. If this is the case, the liver enzymes are likely to be raised<sup>[10]</sup>

### Phlebolith :

A phlebolith is a small local, usually rounded, calcification within a vein. These are very common in the veins of the lower part of the pelvis, and they are generally of no clinical importance. In the face they occur usually multiple. When located in the pelvis they are sometimes difficult to differentiate from kidney stones in the ureters on X-ray.<sup>[11]</sup>

Fig 5. Digital orthopantomography revealing multiple phleboliths



### References:

1. Iwona Rzymyska-Grala et al, Salivary gland imaging, contemporary methods of imaging. Pol J Radiol. 2010 Jul-Sep; 75(3): 25–37.
2. Yousem DM, Kraut MA, Chalian AA. Major Salivary Gland Imaging. Radiology. 2000;216(1):19–29. [PubMed]
3. Haraji A., Mohtasham N., Zareh M.R., Pezeshkirad H. Antrolith in the maxillary sinus: report of a case. J Dentistry AJNR Am J Neuroradiol. 2006;15:917–922.
4. Appleton SS, Kimbrough RE, Engstrom HI. Rhinolithiasis: A review. Oral Surg Oral Med Oral Pathol. 1988;65(6):693–8.

5. AA Yarako et al, Rhinolith: An important cause of foul-smelling nasal discharge, Malays Fam Physician. 2014; 9(1): 30–32.
6. Smith, Lynwood H, calcium containing renal stones, Kidney International , Volume 13 , Issue 5 , 383 - 389
7. Getmann MT, Sequera JW, Struvite stones, Diagnosis and current treatment concepts, J Endourol. 1999 Nov;13(9):653-8.
8. Tin C Ngo, Dean G Assimos, Uric acid Nephrolithiasis: Recent Progress and Future directions, Rev Urol. 2007 Winter; 9(1): 17–27.
9. Lee, JY; Keane, MG; Pereira, S (June 2015). "Diagnosis and treatment of gallstone disease." The Practitioner. **259** (1783): 15–9, 2. PMID 26455113
10. Kim IS, Myung SJ, Lee SS, Lee SK, Kim MH (2003). "Classification and nomenclature of gallstones revisited"(PDF). Yonsei Medical Journal. 44 (4): 561–70. ISSN 0513-5796. PMID 12950109
11. Raviprakash S et al, Intraoral venous malformation with phleboliths, Saudi Dent J. 2011 Jul; 23(3): 161–163.

**Source of support:** Nil

**Conflict of interest:** None declared

This work is licensed under CC BY: **Creative Commons Attribution 3.0 License.**