

## *CASE REPORT*

### **Benign Cementoblastoma of Maxillary Bone and Review of Literature**

Harpreet Sandhu<sup>1</sup>, Ali Amir<sup>2</sup>, Yumna Qamar<sup>3</sup>

<sup>1</sup>Registered Dental Assistant and Hygiene Co-ordinator, Saddleback Dental Centre, Canada,

<sup>2</sup>Lecturer, Department OF Public Health Dentistry, <sup>3</sup>Lecturer, Department Of Orthodontics, Hazaribagh College of Dental Sciences & Hospital, Hazaribagh, Jharkhand

#### **ABSTRACT:**

Cementoblastoma, known as true cementoma, is a rare, benign, odontogenic tumour that tends to be associated with the roots of the mandibular first molars and which is seldom associated with the maxillary teeth. Here is a case report of a swelling in the maxillary left molar region in a 27 year old male which was diagnosed as cementoblastoma along with a brief review of literature.

**Key words:** Benign cementoblastoma, Odontogenic tumor, Maxilla.

Received: 4 August 2018

Revised: 28 August 2018

Accepted: 29 August 2018

**Corresponding Author:** Dr. Ali Amir, Lecturer, Department of Public Health Dentistry, Hazaribagh College of Dental Sciences & Hospital, Hazaribagh, Jharkhand, India

**This article may be cited as:** Sandhu H, Amir A, Qamar Y. Benign Cementoblastoma of Maxillary Bone and Review of Literature. J Adv Med Dent Res 2018;6(10):18-21

#### **INTRODUCTION:**

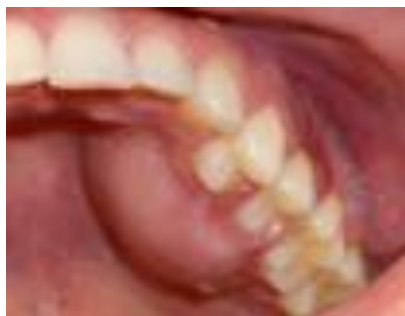Cementoblastoma is a rare benign neoplasm of cementoblasts. <sup>1</sup> It arises from the odontogenic ectomesenchyme and was first described by Dewey in 1927. Some class of authors say that it was described by Norberg in 1930. It consists of proliferating cementum tissue with functional cementoblasts. <sup>2,3,4</sup> The benign cementoblastoma is recognized in WHO classification (1971) of periapical odontogenic tumors as one of the four types of cementum producing disorders. The other three are periapical cemental dysplasia, cementifying fibroma and gigantiform familial cementoma. <sup>5</sup> The WHO defines benign cementoblastoma as “a neoplasm characterized by the formation of sheets of cementum like tissue containing a large number of reversal lines and a lack of mineralization at the periphery of the mass or in more active growth area.” <sup>5</sup> It accounts for less than one percent of all the odontogenic tumors. <sup>6</sup> It is a large bulbous mass of cementum or cementum like tissue on roots of teeth. <sup>7</sup> The case reported is with a one-year history of swelling and pain in the left maxillary molar region.

#### **CASE REPORT:**

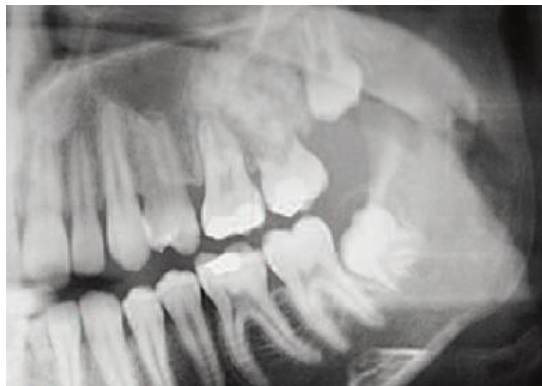A 27 year male patient reported with complaints of swelling and pain in the left maxillary posterior region at our department. History revealed that swelling appeared suddenly one years back and was associated with dull throbbing pain which aggravated and radiated to the ear during morning and night hours and its intensity increased in the past few days.

On intraoral examination, an incompressible swelling associated with respect to vital 26, 27, 28 measuring 1.5 cms in size, hard in consistency with no sinus opening and pus discharge was observed (Figure 1). Provisional diagnosis of cementoblastoma, odontome, fibrous dysplasia, condensing osteitis and ossifying fibroma were kept in mind. Complete blood count was within normal limits. Intra oral periapical radiograph revealed well defined radio-opacity with surrounding peripheral radiolucent rim in relation to 26, 27 and 28 (Figure 2). Excisional biopsy was performed under local anesthesia by extracting the teeth with the attached calcified mass and the specimen was submitted for histopathological examination (Figure 3).

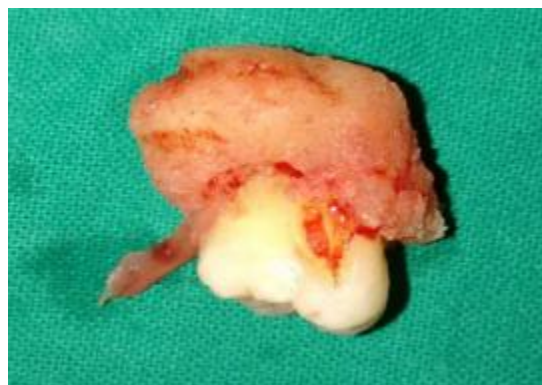The microscopic study the decalcified Hematoxylin and Eosin stained sections showed presence of sheets and trabeculae of cementum like material and few bony trabeculae surrounded by a cellular fibro vascular stroma, adjacent to the apical portion of the root. At places few osteoclastic multinucleated giant cells were seen (Figure 4).The diagnosis of Benign cementoblastoma was achieved. The patient was followed up for one year and no evidence of recurrence was noted.



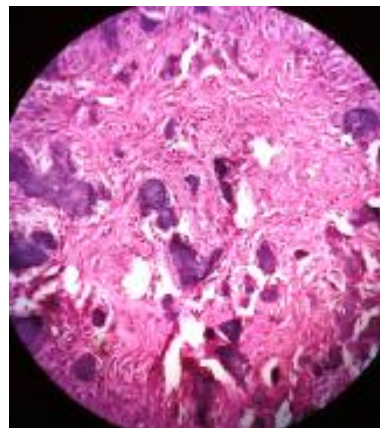
**Figure 1:** The intraoral examination revealed a palatine growth in the premolar-molar region.



**Figure 2:** Radiographically, a large radiopaque lesion was present in the upper-left quadrant, with a surrounding rim of radiolucency. This was associated with the roots of 27, which showed evidence of resorption.



**Figure 3:** Tumor attached with the roots.



**Figure 4:** Photomicrograph showing sheets and trabeculae of cementum like material surrounded by a cellular fibro vascular stroma

#### DISCUSSION:

The benign cementoblastoma or true cementoma is a slow-growing, benign odontogenic tumour arising from cementoblasts. The lesion, which was first recognized by Norberg in 1930, is rare with fewer than 100 cases ever reported.<sup>8</sup>

In the past the benign cementoblastoma was recognized in the World Health Organization’s classification of odontogenic tumours as one of the cementoma neoplasias. Recently the benign cementoblastoma is included into ‘Mesenchyme and/or odontogenic ectomesenchyme, with or without odontogenic epithelium’ odontogenic tumours. The lesion derives from mesenchymal tissue, although its aetiology is unknown.<sup>2</sup>

Most patients initially present with mild pain and bony swelling in the area of the lesion. At least 50% of the reported cases occurred in patients under the age of 20 and 75% under the age of 30 (age range, 6-75 years).<sup>9</sup> There does not appear to be any significant gender or racial predilection. The mandible is by far the most common location; half of all reported cases were associated with the mandibular permanent first molar or second premolar.<sup>9,10</sup> When lesions in the maxilla and mandible are grouped together, over 90% of cases affect a single tooth in the premolar–molar area; however, the tumour has been associated with multiple teeth, impacted molars and deciduous teeth.<sup>8,10</sup> Our case presented with pain, and had swelling. Grossly, a round to ovoid, well-circumscribed mass of hard, calcified tissue surrounds the root of the affected tooth.

The cementoblastoma has a pathognomonic radiographic appearance. It appears as a well-defined solitary circular radiopacity with a radiolucent halo. The lesion is fused to the partly resorbed root (s) of the associated tooth. The internal structure of the mass may possess a mixed radiolucent-radiopaque quality often with a radiating pattern.<sup>11</sup> The differential diagnosis for a periapical radiopacity includes cementoblastoma, osteoblastoma,

odontome, periapical cemental dysplasia, condensing osteitis and hypercementosis. The cementoblastoma and osteoblastoma are closely related lesions that are histologically very similar.<sup>12</sup> The cementoblastoma is distinguished from the osteoblastoma by its location in intimate association with a tooth root. The osteoblastoma arises in the medullary cavity of many bones, including the long bones, vertebrae and jaws.<sup>13</sup> The odontome is usually not fused to the adjacent tooth and appears as a more heterogeneous radiopacity, reflecting the presence of multiple dental hard tissues. Periapical cemental dysplasia usually produces a smaller lesion than cementoblastoma and shows a progressive change in radiographic appearance over time, from radiolucent to mixed to radiopaque. Condensing osteitis lacks a peripheral radiolucent halo. The radiopaque lesion of hypercementosis is usually small, and there is no associated pain or jaw swelling.

Histopathologically the lesion is characterized by deposition of unmineralised eosinophilic matrix rimmed by plump cementoblasts that are continuous with normal cemental layer of one of the tooth roots.<sup>11</sup>

It clinically resembles the lesions such as bone tumors, especially osteoblastoma, cementifying fibroma, periapical cemental dysplasia, condensing osteitis and also atypical hypercementosis which may make the diagnosis a challenging task.<sup>1</sup>

The differential diagnosis for a periapical radio-opacity should include cementoblastoma along with osteoblastoma, odontome, periapical cemental dysplasia, condensing osteitis and hypercementosis. It is differentiated from the osteoblastoma by its location in close association with the tooth's root. The odontome is generally not fused with the adjacent tooth and it does not appear as a homogeneous radiopacity, thus suggesting the presence of multiple dental hard tissues. Periapical cemental dysplasia generally presents as a smaller lesion than cementoblastoma and it shows a progressive change in the radiographic appearance over time, being initially radiolucent, then a mixed lesion and finally a radiopaque lesion. Condensing osteitis lacks a peripheral radiolucent halo. In cementoblastoma, the outline of the root of the involved tooth is usually obscured due to root resorption and fusion of the tumour with the tooth, whereas in hypercementosis, there is an intact lamina dura.<sup>3</sup>

The histopathological differential diagnosis of cementoblastoma includes osteoblastoma and osteosarcoma. It is differentiated from osteoblastoma by its presentation as cementum-like tissue with numerous reversal lines. This lesion is differentiated from osteosarcoma by the absence of malignant features. The differentiation of the above mentioned lesions from cementoblastoma requires a correlation with the clinical and the radiographic findings.<sup>3</sup>

The cementoblastoma has been described as a benign, solitary, slow-growing lesion, although there have been reports of aggressive behaviour.<sup>14,15</sup> Due to the benign

neoplastic nature of the lesion, the treatment of choice is complete removal of the lesion with extraction of the associated tooth. A more conservative technique, to retain the involved tooth and remove the lesion using a surgical endodontic approach, has been reported.<sup>16,17</sup> It can be used for small lesions on strategic teeth that can be completely enucleated without compromising adjacent teeth and that will maintain a sufficient crown-to-root ratio after apicoectomy. The prognosis is excellent, as the tumour does not recur after total excision.<sup>18,19</sup>

#### CONCLUSION:

We have reported case of cementoblastoma with rare occurrence in the maxilla and review of literature of the same. It should be considered as one of the differential diagnosis in bony swellings of the maxilla.

#### REFERENCES:

1. Rezvani G., Dehghani Nazhvani A. Cementoblastoma: Report of a Case with a Long-Term Pain J Dent Shiraz Univ Med Scien 2012; 13(3): 135-8.
2. Sumer M, Gunduz K, Sumer AP, Gunhan O. Benign cementoblastoma: A case report. Med Oral Patol Oral Cir Bucal 2006;11:E483-5.
3. Bal Reddy P., Shyam N.D.V.N., SridharReddy B., KiranG., PrasadN. Cementoblastoma which was associated with the maxillary first premolar: An unusual case report Journal of Clinical and Diagnostic Research. 2012 June, Vol-6(5): 919-20.
4. Ahrens A, Bressi T. true cementoma(Benign Cementoblastoma): A case report. Rivista Scientifica Europea 2005;2:1-4.
5. Kumar S, Prabhakar V, Angra R. infected cementoblastoma Natl J Maxillofac Surg. 2011 Jul;2(2):200-3.
6. Huber AR, Folk GS. Cementoblastoma. Head Neck Pathol 2009; 3: 133-5.
7. J.Dinakar, M.S.Senthil Kumar, Shiju Mathew Jacob. Benign cementoblastoma associated with an unerupted third molar- a case report. Oral & Maxillofacial Pathology Journal 2010; 1(2):76-9.
8. Garlick AC, Newhouse RF, Boyd DB. Benign cementoblastoma: report of a case. Milt Med 1990; 155(11): 567-70
9. Zachariades N, Skordalaki A, Papanicolous S, Androurlakakis E, Bournias M. Cementoblastoma: review of the literature and report of a case in a 7 year-old girl. Br J Oral Maxillofac Surg 1985; 23(6) :456-61.
10. Piattelli A, Di Alberti L, Scarano A, Piattelli M. Benign cementoblastoma associated with an unerupted third molar. Oral Oncol 1998; 34(2):229-31.
11. Matteson SR. Benign tumors of the jaws. In: White SC, Pharoah MJ, editors. Oral radiology: principles and interpretation. 4th ed. Toronto: Mosby; 2000. p. 401-2.
12. Slootweg PJ. Cementoblastoma and osteoblastoma: a comparison of histologic features. J Oral Pathol Med 1992; 21(9):385-9.
13. Neville BW, Damm DD, Allen CM, Bouquot JE. Oral and maxillofacial pathology. 1st ed. Philadelphia: Saunders; 1995. p. 476-7.

14. Krausen AS, Pullon PA, Gulmen S, Schenck NL, Ogura JH. Cementomas — aggressive or innocuous neoplasms? Arch Otolaryngol 1977; 103(6):349-54
15. Langdon JD. The benign cementoblastoma — just how benign? Br J Oral Surg 1976; 13(3):239-49
16. Goerig AC, Fay JT, King E. Endodontic treatment of a cementoblastoma. Oral Surg 1984; 58(2):133-6.
17. Biggs JT, Benenati, FW. Surgically treating a benign cementoblastoma while retaining the involved tooth. J Am Dent Assoc 1995; 126(9):1288-90.
18. Ulmansky M, Hjorting-Hansen E, Praetorius F, Hacque MF. Benign cementoblastoma: a review and five new cases. Oral Surg Oral Med Oral Pathol 1994; 77(1):48-55.
19. Huvar RJ, Butura CC. Benign cementoblastoma: report of case. CDS Rev 1995; 88(8):36-7.

**Source of support:** Nil

**Conflict of interest:** None declared

This work is licensed under CC BY: ***Creative Commons Attribution 3.0 License.***