

## Original Research

### Evaluation of the efficacy of Bipolar hip prosthesis and Austin Moore prosthesis in the management of Intracapsular Fracture neck of femur

Ghansham A. Pol<sup>1</sup>, Abhishek Ranjan<sup>2</sup>

<sup>1</sup>Assistant Professor, <sup>2</sup>Junior Resident, Department of Orthopaedics, RCSM Govt. Medical College & CPR Hospital, Kolhapur, Maharashtra, India;

#### ABSTRACT:

**Background:** Fracture of the hip is a common injury. With increasing life expectancy worldwide, the number of elderly individuals is increasing, and it is estimated that the incidence of hip fracture will rise from 1.66 million in 1990 to 6.26 million by 2050. Many surgeons perform hemi-replacement arthroplasty as a primary procedure for the treatment of fracture neck of femur. The successful application of it is in the hands of various surgeons points to its continued usefulness as both Austin Moore & Bipolar hemiarthroplasty for treatment of elderly patient suffering from fracture neck of femur achieve high ambulatory ability and low revision rates. **Aim of the study:** To evaluate the efficacy of Bipolar hip prosthesis and Austin Moore prosthesis in the management of Intracapsular Fracture neck of femur where replacement of head and neck of femur offers the advantage of rapid return of joint function. **Materials and methods:** This is a hospital based prospective study with 30 patients evaluated for efficacy and functional outcome of Bipolar hip prosthesis and Austin Moore prosthesis in the management of Intracapsular Fracture neck of femur. The duration of study was for one year. The study was done at tertiary care center in Rajarshree Chhatrapati Shahu Maharaj Govt. Medical College & C.P.R Hospital, Kolhapur. Implants used were Bipolar Prosthesis and Austin Moore Prosthesis. **Results:** Majority of the patients (40%) were from the age group of 76-80 years followed by 33.3% from the age group of 71-75 years, 16.7% from the age group of 81-85 years and 10% from the age group of 86-90 years. The mean age of patients was  $78.07 \pm 4.91$  years. 3 (10%) patients had painful hip while 2 (6.7%) patients each had periprosthetic fracture and superficial infection. 2 (6.7%) patients each had limb discrepancy >2cm and acetabular erosion while 1 (3.3%) patient each had deep wound infection and intra operative fracture. The mean VAS Score at post-op 6 weeks was  $4.83 \pm 2.13$  which decreased significantly to  $2.53 \pm 0.63$  at post-op 3 months,  $2.03 \pm 0.41$  at post-op 6 months and  $1.33 \pm 0.48$  at post-op 1 year. There was significant improvement in VAS Score during follow-up period as per Student t-test. **Conclusion:** Hemiarthroplasty with Austin Moore Prosthesis is safe and effective method of treatment for displaced fracture neck of femur in elderly. There was early post-operative full weight bearing mobilization with reduction in major complications. The end functional results also depend on the associated comorbidities and optimum post op rehabilitation.

**Keywords:** Austin Moore prosthesis, Bipolar hip prosthesis, Hip prosthesis.

Received: 17 March, 2019

Revised: 26 April 2019

Accepted: 27 April 2019

**Corresponding Author:** Dr. Ghansham A. Pol, Assistant Professor, Department of Orthopaedics, RCSM Govt. Medical College & CPR Hospital, Kolhapur, Maharashtra, India;

**This article may be cited as:** Pol GA, Ranjan A. Evaluation of the efficacy of Bipolar hip prosthesis and Austin Moore prosthesis in the management of Intracapsular Fracture neck of femur. J Adv Med Dent Scie Res 2019;7(7): 190-195.

#### INTRODUCTION:

Fracture of the hip is a common injury. With increasing life expectancy worldwide, the number of elderly individuals is increasing, and it is estimated that the incidence of hip fracture will rise from 1.66 million in 1990 to 6.26 million by 2050. Intracapsular fractures of the femoral neck constitute 53% of all hip fractures with 33% undisplaced

and 67% displaced. Proximal femoral Fractures account for a large proportion of hospitalization among trauma cases.<sup>1</sup> An overwhelming majority of these patients (>90%) are aged above 50 years. The incidence of these fractures is 2–3 times more in females as compared to male population.<sup>2</sup> They are classified on basis of anatomical location of fracture into: neck of femur fracture, inter trochanteric

fracture and subtrochanteric fracture. Each of these fracture types require special methods of treatment and have their own set of complications and controversies regarding the optimal method of management. Management of femoral neck fractures in elderly patients has been controversial. Femoral neck fractures have been considered 'unsolvable fractures' in the older era of orthopaedics<sup>3</sup> due to the high rate of associated complications, which include nonunion, lack of rigid fixation and avascular necrosis of the femoral head, among others. Presently, there are multiple surgical treatment options (cannulated screws, dynamic hip screw systems, blade plates, hemi and total hip arthroplasty) available. Intracapsular extent of the fracture, tenuous blood supply to the femoral head going through the neck and difficulty in maintaining fracture reduction have been cited as reasons for failure of fixation. Although treatment methods have been refined over the years, a consensus on the ideal treatment remains elusive.<sup>3,4</sup> Replacement of the femoral head and neck with a prosthesis offers a way to prevent complications of internal fixation and is therefore an attractive alternative in the elderly patient.<sup>5</sup> There is however no consensus on how to treat patients with a displaced intracapsular fracture between sixty and eighty years of age. It is because of the poor clinical results that the displaced intracapsular fracture is referred to as "the unsolved fracture". The development of bipolar hemiarthroplasty was based on the clinical experience with limited success of unipolar prosthesis due to progressive acetabular erosion and protrusion.<sup>6-8</sup> Replacement arthroplasty (total hip arthroplasty, bipolar & hemiarthroplasty) are very useful procedures and have to be carried out when it is not possible to achieve union of fracture or in old people who have to be put on their feet without loss of time.<sup>9</sup> The choice between unipolar and bipolar prosthesis is less clear. The main theoretical advantage of a bipolar over a unipolar prosthesis is the reduction of acetabular erosion due to movement taking place within the implant rather than between the head of the prosthesis and the acetabulum, although there is variation in the comparative distribution of the movement. Movement within the prosthesis may also reduce the pain. Hemiarthroplasty, when compared to internal fixation, showed better functional outcome in elderly patients.<sup>10</sup> It can avoid complications like osteonecrosis and non-union.<sup>11</sup> There is significant reduction in reoperation rate following hemiarthroplasty.<sup>12</sup> According to Boyd HB and Salvatore J "That sacrifice of head and neck and its replacement by a metallic foreign substance is not the answer for majority of patients; in over half, the best available material is in the acetabulum and its indiscriminate removal should be avoided".<sup>13</sup> Austin Moore hemiarthroplasty is a frequently done and well accepted procedure which has good functional outcome with the low cost of the implant compared to bipolar and total hip arthroplasty.<sup>14</sup> The primary goal of treatment is to return the patient to his or her pre-fracture functional status.<sup>15</sup> Many

surgeons perform hemi-replacement arthroplasty as a primary procedure for the treatment of fracture neck of femur. The successful application of it is in the hands of various surgeons points to its continued usefulness as both Austin Moore & Bipolar hemiarthroplasty for treatment of elderly patient suffering from fracture neck of femur achieve high ambulatory ability and low revision rates.<sup>16</sup> Hence the present study was done at our tertiary care center to evaluate the efficacy of Bipolar hip prosthesis and Austin Moore prosthesis in the management of Intracapsular Fracture neck of femur and assess the functional outcome of Bipolar hip prosthesis and Austin Moore prosthesis in the Intracapsular Fracture neck of femur.

#### **MATERIALS AND METHODS:**

This is a hospital based prospective study with 30 patients evaluated for efficacy and functional outcome of Bipolar hip prosthesis and Austin Moore prosthesis in the management of Intracapsular Fracture neck of femur. The duration of study was for one year. The study was done at tertiary care center in Rajarshee Chhatrapati Shahu Maharaj Govt. Medical College & C.P.R Hospital, Kolhapur. All cases of Intracapsular Fracture neck of Femur admitted in Rajarshee Chhatrapati Shahu Maharaj Govt. Medical College & C.P.R Hospital, Kolhapur who fulfilled the inclusion criteria were included in the study.

#### **Inclusion criteria**

- Patient more than 70 years of age with fresh and old intracapsular fracture neck of femur.
- Intracapsular fracture neck of femur in elderly due to bone weakness by osteoporosis.

#### **Exclusion criteria**

- Fracture neck of femur associated with fracture shaft of femur or Trochanteric fracture and Acetabular fracture.
- Pathological fracture neck of femur excluding osteoporotic fractures. It includes fractures induced by osteolytic lesions eg. metastatic lesions.

#### **Sampling Procedure:**

- History
- Clinical examination
- Radiological examination

The study done in the Department of Orthopedics in Rajarshee Chhatrapati Shahu Maharaj Govt. Medical College & C.P.R Hospital, Kolhapur after obtaining due permission from the Institutional Ethics Committee and Review Board and after taking Written Informed Consent from the patients. Investigations were conducted on patients, investigations were routine standardized procedures.

- X-ray Pelvis with Both Hips-AP view.

- Complete blood count.
- Random blood sugar, Blood urea and Serum creatinine.
- HIV and HBsAg.
- Blood grouping and Rh- typing.
- ECG.
- Chest X-ray- Postero-anterior view.
- Computed-tomography scan if necessary.

Other specific investigations if needed.

### **Pre-Operative Preparation:**

Patients were put on ankle traction or high tibial skeletal traction. Adequate analgesics either oral or parenteral were given to provide relief from pain. Patients with associated medical illness like anemia, Hypertension etc. were referred to the physician and appropriate treatment instituted. Pre-anaesthetic evaluation was carried out and patients were taken up for surgery after obtaining informed written consent. Parenteral antibiotics were started the night prior to the surgery and continued thereafter.

### **Surgical Procedure:**

Under spinal anaesthesia, patient were placed in a lateral position on the unaffected side.

Hip is exposed through modified Gibson (posterolateral) approach. Incision is made approximately 10cm distal to the posterior superior iliac spine and extended distally and laterally parallel to the fibres of gluteus maximus to the posterior margin of greater trochanter. The incision is directed distally 10-13 cms parallel with femoral shaft. The deep fascia is divided in line with the skin incision, by blunt dissection the fibers of gluteus maximus are divided avoiding injury to superior gluteal vessels in the proximal part. The proximal fibres of gluteus maximus are retracted proximally exposing the Greater trochanter & the distal fibres are retracted distally. The sciatic nerve is identified and retracted carefully. The short external rotators are identified and stay sutures are applied exposing the capsule. The hip joint is opened by T shaped incision over posterior capsule. The thigh and knee are flexed upto 90 degrees and internally rotated to dislocate the hip joint. The head is extracted using an extractor or by using levers. The acetabulum cavity is cleared off of soft tissue remnants and Ligamentum Teres. The neck of femur is cut using a sagittal saw retaining approximately 5-10 mm of calcar over lesser trochanter at an angle parallel to that of prosthesis shoulder. The femoral canal is reamed using the specific reamer of prosthesis, the entry point being more lateral so as to avoid a varus position. While reaming the reamer should be positioned in the femoral canal with 5-10 degrees of ante-version. Reaming is done using hand and hammer gently for insertion and extraction of rasp. The correct size of prosthesis as determined by measuring the extracted head with the measuring gauge is taken and trial reduction is performed which should reduce or dislocate the head out of Acetabulum with the suction sound. The stem

of the prosthesis is placed in the proximal femur till the collar is flushed off of calcar and reduced by traction, external rotation of thigh and gentle manipulation of the head of the prosthesis into the Acetabulum. The stability is then checked by movement of the hip joint. Wound is closed in layers with suction drain in situ.

### **Implants used:**

1. Bipolar Prosthesis
2. Austin Moore Prosthesis

### **Post-Operative protocol:**

During the postoperative period the patients were placed in an abduction pillow for 5-7 days. On second post-operative day, the patients were made to sit in bed. By third postoperative day patients were mobilized using walker. Full weight bearing and ambulation was allowed as tolerated. The suction drain was removed after 48 hrs. Parenteral antibiotics were given for 5 days and then switched over to oral antibiotics until suture removal. Sutures were removed around 12th postoperative day. Check radiographs were obtained in all cases on postoperative day 1. Most of the patients were discharged by 12th post-operative day. On discharge, the patients were advised not to sit cross legged or squat to avoid excessive load on prosthesis decreasing its life span. Follow up examination were done at 6 weeks, 3 months, 6 months & 1 year. Radiographs were taken during follow up for evidence of any complication. Outcome of the surgery was assessed using modified Harris hip score system.

Association among the study groups is assessed with the help of Fisher test, student 't' test and Chi-Square test. 'p' value less than 0.05 is taken as significant.

### **RESULTS:**

A hospital based prospective, study was conducted with 30 patients to evaluate the efficacy and functional outcome of Bipolar hip prosthesis and Austin Moore prosthesis in the management of Intracapsular Fracture neck of femur. Table 1 shows the distribution of patients according to age. Majority of the patients (40%) were from the age group of 76-80 years followed by 33.3% from the age group of 71-75 years, 16.7% from the age group of 81-85 years and 10% from the age group of 86-90 years. The mean age of patients was  $78.07 \pm 4.91$  years. Table 2 shows the distribution of patients according to sex. Majority of the patients (66.7%) were male while female patients constituted 33.3% of the study group. Table 3 shows the distribution of patients according to complications.

3 (10%) patients had painful hip while 2 (6.7%) patients each had periprosthetic fracture and superficial infection. 2 (6.7%) patients each had limb discrepancy >2cm and acetabular erosion while 1 (3.3%) patient each had deep wound infection and intra operative fracture. Table 4 shows the distribution of patients according to Visual Analogue Scale (VAS) score. The mean VAS Score at post-op 6

weeks was  $4.83 \pm 2.13$  which decreased significantly to  $2.53 \pm 0.63$  at post-op 3 months,  $2.03 \pm 0.41$  at post-op 6 months and  $1.33 \pm 0.48$  at post-op 1 year. There was

significant improvement in VAS Score during follow-up period as per Student t-test ( $p < 0.05$ ).

**Table 1: Distribution of patients according to Age**

Age (years)	N	%
71-75 years	10	33.3%
76-80 years	12	40%
81-85 years	5	16.7%
86-90 years	3	10%
<b>Total</b>	<b>30</b>	<b>100%</b>
<b>Mean <math>\pm</math> SD</b>	<b>78.07 <math>\pm</math> 4.91</b>	

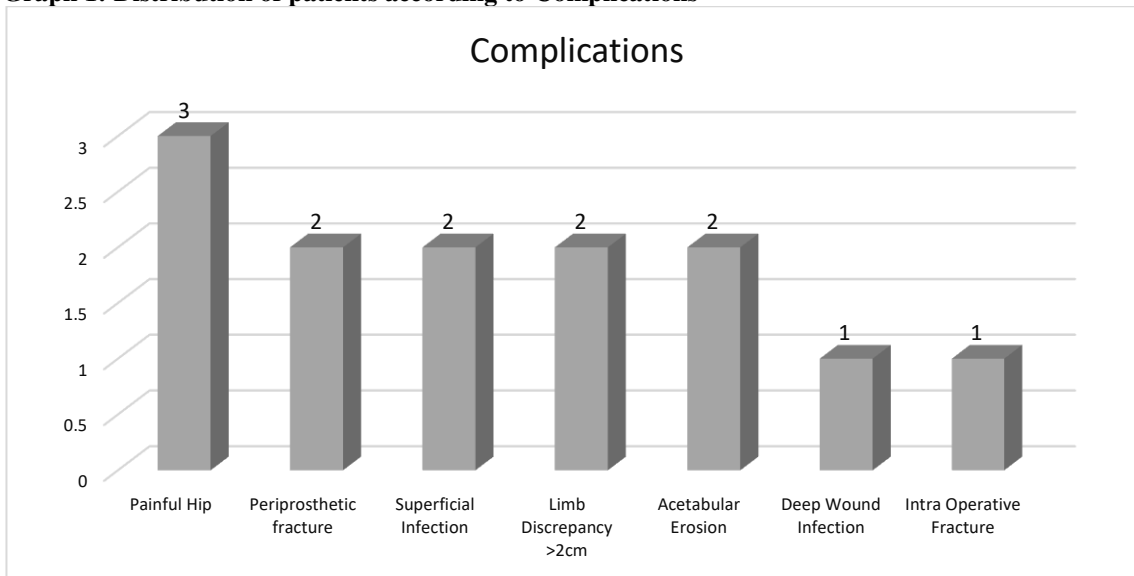
**Table 2: Distribution of patients according to Sex**

Sex	N	%
Male	20	66.7%
Female	10	33.3%
<b>Total</b>	<b>30</b>	<b>100%</b>

**Table 3: Distribution of patients according to Complications**

Complications	N	%
Painful Hip	3	10%
Periprosthetic fracture	2	6.7%
Superficial Infection	2	6.7%
Limb Discrepancy >2cm	2	6.7%
Acetabular Erosion	2	3.7%
Deep Wound Infection	1	3.3%
Intra Operative Fracture	1	1.8%

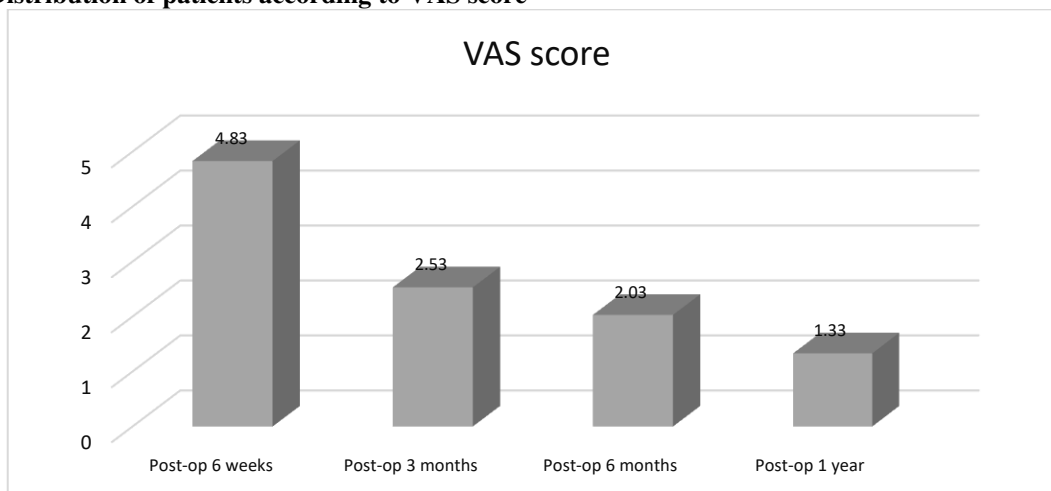
**Graph 1: Distribution of patients according to Complications**



**Table 4: Distribution of patients according to VAS score**

VAS Score	Mean	SD	p Value
Post-op 6 weeks	4.83	2.13	-
Post-op 3 months	2.53	0.63	<b>&lt;0.05</b>
Post-op 6 months	2.03	0.41	<b>&lt;0.05</b>
Post-op 1 year	1.33	0.48	<b>&lt;0.05</b>

**Graph 2: Distribution of patients according to VAS score**



**DISCUSSION:**

A hospital based prospective, study was conducted with 30 patients to evaluate the efficacy and functional outcome of Bipolar hip prosthesis and Austin Moore prosthesis in the management of Intracapsular Fracture neck of femur. Limping is a common consequence of hemiarthroplasty in adults. Alteration in the abductor mechanism due to a marginally greater excision of neck is the most probable cause<sup>87</sup>. Cornell CN et al<sup>88</sup> reported that patients with bipolar prosthesis did better on walk tests and had better range of motion at six months. In the present study, majority of the patients (40%) were from the age group of 76-80 years followed by 33.3% from the age group of 71-75 years, 16.7% from the age group of 81-85 years and 10% from the age group of 86-90 years. The mean age of patients was 78.07 ± 4.91 years. Majority of the patients (66.7%) were male while female patients constituted 33.3% of the study group. This is similar to the studies of Somashekar S et al<sup>19</sup>, Rakshith Kumar K et al<sup>20</sup>, Dawadi TP et al<sup>21</sup>, Sharoff L et al<sup>22</sup> and Vishwanath C et al<sup>23</sup>. SomashekarS et al<sup>19</sup> study comparing the outcome of unipolar with the bipolar prosthesis in geriatric patients observed who had unipolar prostheses were comparatively older to those with bipolar prostheses (75.5 vs. 67.3, P<0.01). Females constituted 65.8%. Rakshith Kumar K et al<sup>20</sup> prospective study analyzing surgical management of fracture neck of femur using modular bipolar hemiarthroplasty found 8 males and 12 females, with a maximum age of 92 yrs, minimum age of 50yrs and an average age of 65 years. Dawadi TP et al<sup>21</sup> prospective randomized study assessing the outcome of Austin Moore Hemire Placement Arthroplasty in terms of Harris Hip Score observed mean age of the patients was 74 years with SD of 5.31. Sixty percent (18) were females while 40% (12) were male. Sharoff L et al<sup>23</sup> prospective observational study evaluating the functional result of cemented Bipolar Hemiarthroplasty observed all patients were above 55

years. Only 4 patients were above 80 years. Out of the 38 patients, 24 were females. Vishwanath C et al<sup>23</sup> prospective comparative study comparing the efficiency of these two prosthesis unipolar and bipolar prosthesis found mean age of 70.4 in AMP group and 69.1 in Bipolar group. It was observed in our study that 3 (10%) patients had painful hip while 2 (6.7%) patients each had periprosthetic fracture and superficial infection. 2 (6.7%) patients each had limb discrepancy >2cm and acetabular erosion while 1 (3.3%) patient each had deep wound infection and intra operative fracture. This is similar to the studies of Sharoff L et al<sup>22</sup>, Vishwanath C et al<sup>23</sup>, Dawadi TP et al<sup>21</sup>, Zacharia B et al<sup>24</sup> and SomashekarS et al<sup>19</sup>. Sharoff L et al<sup>22</sup> prospective observational study evaluating the functional result of cemented Bipolar Hemiarthroplasty reported major complications were radiological i.e. improper cement mantle and valgus malalignment of the stem. Superficial infection was encountered in 1 patient (2.63%). Vishwanath C et al<sup>23</sup> prospective comparative study comparing the efficiency of these two prosthesis unipolar and bipolar prosthesis reported incidence of complications like Superficial infection, haematoma and acetabular erosion was encountered in AMP group. Dawadi TP et al<sup>21</sup> prospective randomized study assessing the outcome of Austin Moore Hemire Placement Arthroplasty in terms of Harris Hip Score reported complications were seen in 23.3% of patients. Among the total 6.6% had hip pain and similarly 6.6% had thigh pain. Limb length discrepancy of 2.5 cm was noted in 3.3% of cases and wound infection was found in 3.3% of cases. One case (3.3%) was suspected of DVT at 2nd post op day clinically, but couldn't be confirmed with Doppler due to lack of immediate facility of Doppler. Zacharia B et al<sup>24</sup> prospective comparative study assessing fracture neck of femur treated with cemented bipolar prosthesis and uncemented Austin Moore prosthesis reported three cases of femoral stem subsidence and two cases of acetabular erosion in the AMP group. SomashekarS et al<sup>19</sup> study comparing the

outcome of unipolar with the bipolar prosthesis in geriatric patients reported most of the complications were recorded with the unipolar group. All cases, one (4.7%) in the unipolar group presented with posterior dislocation on the 8<sup>th</sup> post operative day, for which closed reduction was done under GA and immobilized for one and half months and there after mobilized successfully. Another case (4.7%) of unipolar group presented with periprosthetic fracture after three months following trauma, which was managed with open reduction and internal fixation with plate and screws retaining the same prosthesis. The patient was mobilized after two months and he continued to have thigh pain. A case of acetabular erosion was noted in the unipolar group. A single case of superficial infection was recorded in each group, which responded to antibiotics.

In the present study, the mean VAS Score at post-op 6 weeks was 4.83±2.13 which decreased significantly to 2.53±0.63 at post-op 3 months, 2.03±0.41 at post-op 6 months and 1.33±0.48 at post-op 1 year. There was significant improvement in VAS Score during follow-up period as per Student t-test (**p<0.05**). This is comparable to the studies of Sharoff L et al<sup>22</sup> and Zacharia B et al<sup>24</sup>. Sharoff L et al<sup>22</sup> prospective observational study evaluating the functional result of cemented Bipolar Hemiarthroplasty reported majority of the patients i.e. 28 patients did not have pain 1 year post-surgery. (73.7%) had no pain in the operated hip. Zacharia B et al<sup>24</sup> prospective comparative study assessing fracture neck of femur treated with cemented bipolar prosthesis and uncemented Austin Moore prosthesis reported no significant difference in pain score between the two groups.

### CONCLUSION:

Hemiarthroplasty with Austin Moore Prosthesis is safe and effective method of treatment for displaced fracture neck of femur in elderly. There was early post-operative full weight bearing mobilization with reduction in major complications. The end functional results also depend on the associated comorbidities and optimum post op rehabilitation.

### REFERENCES:

1. Fox KM, Magaziner J, Hebel J.R. Intertrochanteric versus femoral neck fractures: differential characteristics, treatment, and sequelae. *J Gerontol A Biol Sci Med Sci.* 1999, 54:635–640.
2. Zuckerman JD. Hip fracture. *N Engl J Med.* 1996, 334:1519–1525.
3. Bandgar TR. Vitamin D and Hip Fractures: Indian Scenario. *Journal of Association of Physicians of India.* 2010, 58.
4. Lu-Yao GL, Keller RB, Littenberg B et al. Outcomes after displaced fractures of the femoral neck. A meta-analysis of one hundred and six published reports. *J Bone Joint Surg Am.* 1994, 76: 15-25.
5. Van Vugt AB. The unsolved fracture. A prospective study of 224 consecutive cases with an intracapsular hip fracture. Thesis, University of Nijmegen, 1991.

6. Moore AT, Bohlman HR. Metal Hip Joint. A Case Report. *J Bone Joint Surg.* 1943; 25: 688-92.
7. Krahn TH, Canale ST, Beaty JH et al. Long-term follow-up of patients with avascular necrosis after treatment of slipped capital femoral epiphysis. *J Pediatr Orthop.* 1993, 13(2):154-8.
8. Sandhu HS. Management of fracture neck of femur. *Indian J Orthop.* 2005, 39:130-6.
9. Parker MJ, Gurusamy KS, Azegami S. Arthroplasties (with and without bone cement) for proximal femoral fractures in adults. *Cochrane Database Syst Rev.* 2010, 16(6):CD001706.
10. Parker MJ. Hemiarthroplasty versus internal fixation for displaced intracapsular fractures of the hip in elderly men: a pilot randomised trial. *Bone Joint J.* 2015, 97-B(7):992-96.
11. Carpintero P, Caeiro JR, Carpintero R, Morales A et al. Complications of hip fractures: A review. *World J Orthop.* 2014, 5(4):402-11.
12. Blomfeldt R, Törnkvist H, Ponzer S et al. Comparison of internal fixation with total hip replacement for displaced femoral neck fractures. 2005, 87(8):1680-8.
13. Boyd HB, Salvatore JE. Acute Fracture of the Femoral Neck. 1964, 46(5):1066-8.
14. Parker MJ, Khan RJ, Crawford J et al. Hemiarthroplasty versus internal fixation for displaced intracapsular hip fractures in the elderly. A randomised trial of 455 patients. *J Bone Joint Surg Br.* 2002, 84: 1150-5.
15. SksMarya, R Thukral, Chanddeep Singh. Prosthetic replacement in femoral neck fracture in the elderly: Results and review of the literature.. *Indian Journal of Orthopaedics.* 2008, Vol 42 Pg 61-67.
16. Yang B, Lin X, Yin XM et al. Bipolar versus unipolar hemiarthroplasty for displaced femoral neck fractures in the elder patient: a systematic review and meta-analysis of randomized trials.. *Eur J Orthop Surg Traumatol.* 2015, 25(3):425-33.
17. Hinchey JJ, Day PL. Primary prosthetic replacement in fresh femoral neck fractures. *J Bone Joint Surg Am.* 1960; 42: 633-40.
18. Cornell CN, Levine D, O'Doherty J et al. Unipolar versus bipolar hemiarthroplasty for the treatment of femoral neck fractures in the elderly. *Clin Orthop Relat Res.* 1998; 348: 67-71.
19. Somashekar Krishna SV, Sridhara Murthy J. Treatment of femoral neck fractures: unipolar versus bipolar hemiarthroplasty. *Malays Orthop J.* 2013, 7(2):6–11.
20. Rakshith Kumar K, Maheshwarappa A. Prospective study of hemiarthroplasty for intracapsular fracture neck of femur using modular bipolar prosthesis. *International Journal of Orthopaedics Sciences* 2018; 4(4): 92-95
21. Dawadi TP, Bhatta TR, Gyawali B et al. Functional outcome of Austin Moore Hemire Placement Arthroplasty in Fracture Neck of Femur in elderly. *JMMIHS.* 2017; 3(1): 6-15.
22. Sharoff L, Nazeer M, Unnikrishnan R et al. Functional outcome of cemented bipolar hemireplacement arthroplasty in fracture neck of femur in elderly: A prospective observational study. *International Journal of Medical Research & Health Sciences,* 2016,5(2):70-76.
23. Vishwanath C and Mummigatti SB. Comparative study between Austin Moore prosthesis and bipolar prosthesis in fracture neck of femur. *National Journal of Clinical Orthopaedics.* 2017, 1(2): 53-61.
24. Zacharia B, Inassi J, Subramanian D et al. Unipolar Austin Moore's Prosthesis Versus Cemented Bipolar Arthroplasty in Displaced Neck of Femur Fracture, in Elderly Patients. *Journal of Clinical and Diagnostic Research.* 2018, Vol-12(8): RC01-RC04.