

Original Research

Assessment of outcomes and efficacy of clavicle hook plating and lateral clavicle locking plate while treating the lateral end clavicle fractures

Dr. Srikanth Nara¹, Dr. Sridhar Bandi²

¹Assistant Professor, Department of Orthopedics, RVM Institute of Medical Sciences and Research Center, Laxmakkapally Village, Mulugu Mandal, Siddipet Dist., Telangana - 502279.

²Civil Assistant Surgeon Specialist, Department of Orthopedics, Govt Area Hospital Bhainsa, Telangana 504103

ABSTRACT:

Background: This study was to retrospectively compare and review the clinical outcomes between the distal clavicular locking plate and clavicular hook plates in the treatment of unstable distal clavicle fractures using Constant Murley score. **Materials and methods:** The main outcome comparisons included Constant score, rate of non-union, rate of complication, and rate of returning to work three months postoperatively. This study include total of 30 cases with displaced lateral end clavicle fractures satisfying the inclusion criteria treated with lateral clavicle locking plate (15cases) and clavicle hook plate (15 cases). Patients were followed up at 1st month, 2nd month and 6th month, the functional outcome was assessed using Constant Murley score and the radiological outcome was also assessed. **Results:** In our study, 15 cases treated with clavicle hook plate had better results than 15 cases treated by lateral clavicle locking plate in terms of fracture union, Constant Murley score, range of movements. At the final follow-up of 6 months, excellent outcome was seen in 26.7% of patients treated with hook plate as compared to 6.7% of patients treated with lateral clavicle locking plate. **Conclusion:** However, internal fixation with a distal clavicular locking plate had greater ability to return to their previous work after surgery in three months and fewer complications than the clavicular hook plate. Both hook plate and locking plate have a good functional outcome for lateral end clavicle fractures. Addressing the coracoclavicular ligaments in case of lateral locking plate is of utmost importance in comminuted lateral end clavicle fractures. Hook plate is an absolute indication for comminuted lateral end clavicle fractures. Hook plate has implant-related complications, hence implant removal at earliest is advisable.

Key Word: Internal fixation, Lateral end clavicle fracture, Clavicle hook plate, Lateral clavicle locking plate, Subacromial osteolysis, Acromioclavicular joint dislocation, Clavicle fracture, Hook plate.

Received: 2 January 2019

Accepted: 24 January 2019

Corresponding Author: Dr. Sridhar Bandi, Civil Assistant Surgeon Specialist, Department of Orthopedics, Govt Area Hospital Bhainsa, Telangana 504103

This article may be cited as: Nara S, Bandi S. Assessment of outcomes and efficacy of clavicle hook plating and lateral clavicle locking plate while treating the lateral end clavicle fractures. J Adv Med Dent Scie Res 2019;7(2): 173-178.

INTRODUCTION

A decade ago it was convincingly shown in a study that long term complication of the clavicle fracture can occur like acromio-clavicular joint problems. To assess the role of hook plate in lateral end clavicle fractures, we studied & followed up the selected patients for an average period of 24 months. Fractures of the clavicle

are common injuries with an incidence of 29 per 100,000 population per year.¹ It accounts for 2.6–4% of the total adult fractures. Lateral end fracture constitutes 21–28% of all clavicle fractures. Of these 10–52% are displaced fractures.² While minimally displaced fractures of the lateral end of the clavicle can be managed non-operatively with good clinical outcome,

displaced fractures of the lateral end of clavicle have a higher rate of non-union.³ High incidence of non-union may be due to the loss of coracoclavicular ligamentous restraint on the medial fragment, muscle forces, and soft tissue interposition between the fracture fragments. Therefore, operative management is preferred for most displaced fractures. There is a wide variety of surgical techniques for the treatment for these fractures. If surgery of lateral end clavicle fractures is indicated, many implants or surgical methods are available, including Kirschner wires, coracoclavicular screw fixation, hook plate fixation, or lateral clavicle locking plate fixation. Although there are many types of operative procedures, no procedures are considered to be the gold standard treatment. The optimal treatment of unstable lateral clavicle fractures is still controversial. Unstable lateral end clavicle fractures often require open reduction and internal fixation.¹ The use of a pre-contoured superiorly placed lateral clavicle locking plate and screws, for the lateral end of the clavicle, is a recent development. It is advocated as a satisfactory technique for fixation of displaced fractures of the lateral end clavicle due to good results seen with this fixation. ¹ High rate of union (95% or higher) and good shoulder function have been reported with use of hook plates, but patient discomfort and acromial osteolysis generally require plate removal as soon as union occurs.⁴ The purpose of this study is to compare and review the clinical outcomes between the lateral clavicle locking plate and clavicle hook plate in the treatment of unstable lateral end clavicle fractures; moreover, the relevant literature of the two fixation methods will be reviewed systematically to identify the non-union, complications, or functional scores, according to the treatment methods and determine which treatment method is better.

MATERIALS AND METHODS

30 cases with lateral end clavicle fractures admitted in RVM Institute of Medical Sciences and Research Center, Laxmakkapally Village, Mulugu Mandal, Siddipet Dist., Telangana and Malla Reddy Institute of Medical Sciences, Venkatarama Colony, Suraram, Hyderabad, Telangana, in a period of September 2016 to April 2018 satisfying the inclusion criteria who were treated with lateral clavicle locking plate (15 cases) and clavicle hook plate (15 cases) were enrolled in this study using computer-generated random number.

Inclusion criteria

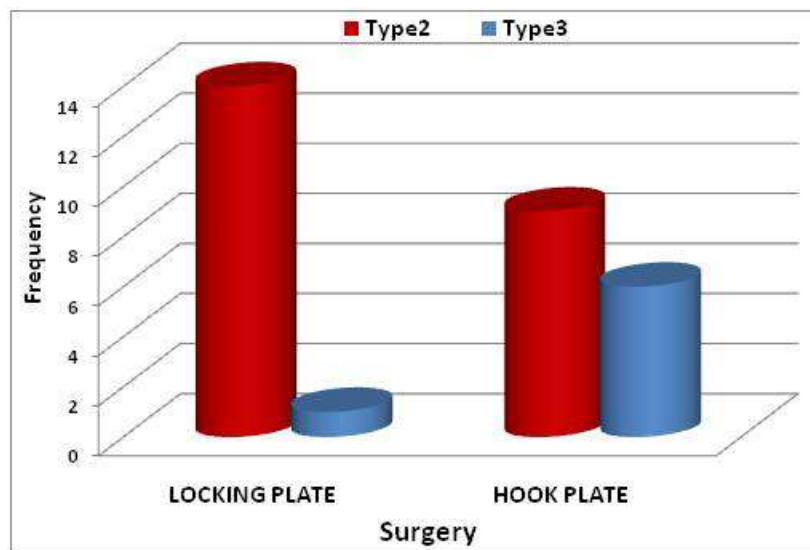
- A. Displaced lateral end clavicle fracture.
- B. Age > 18 years.

Exclusion criteria

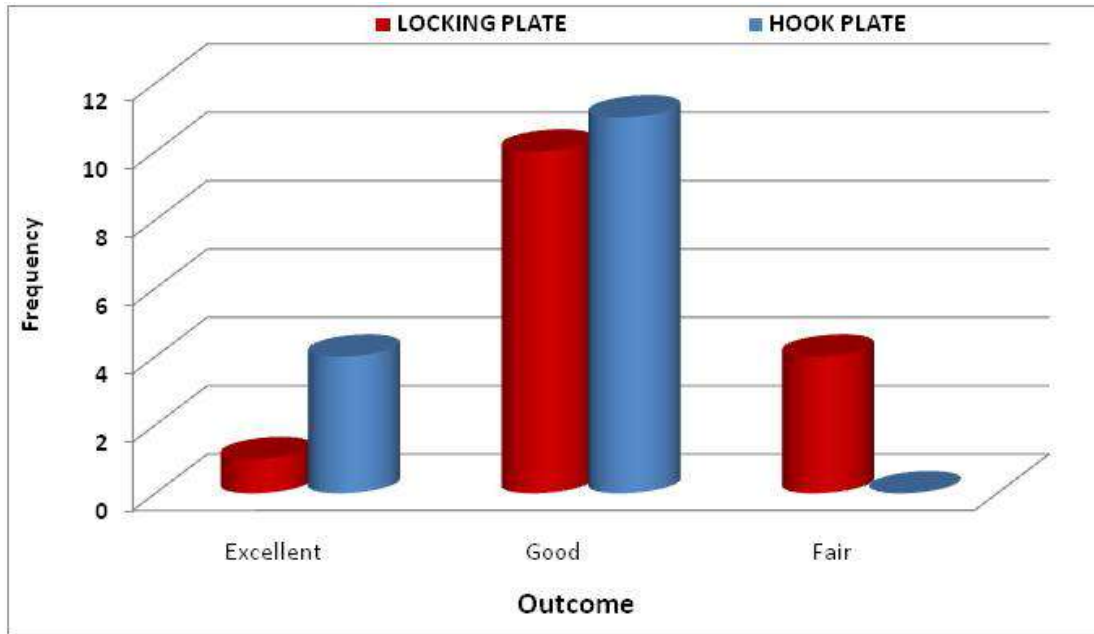
- A. Pathological fractures
- B. Medial and mid shaft clavicle fractures.
- C. Ipsilateral -humerus head/neck fracture.

RESULTS

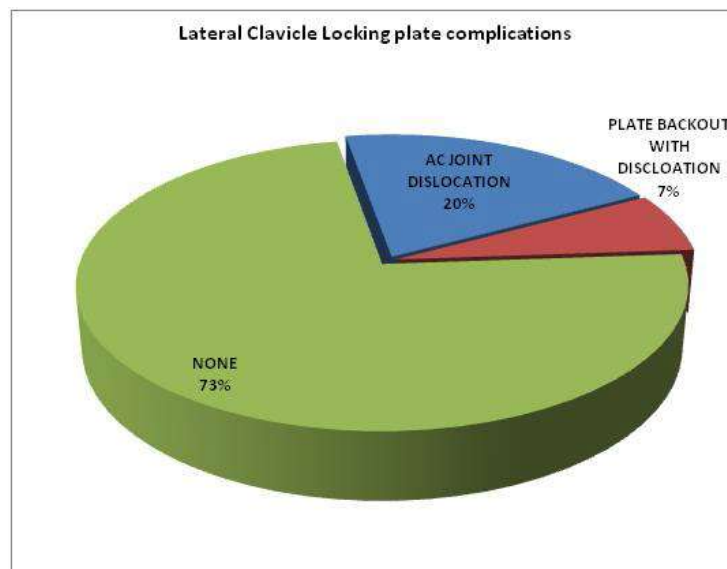
There were total of 30 patients, among them 25(83.3%) were male and 5(16.7%) were female. Right sided lateral end clavicle fracture was seen in 18(60%) and left in 12(40%) patients. Road traffic accidents was the cause of trauma in 22 (73.3%) and fall in 8(26.7%). 23(76.7%) patients were type 2 Neer’s fracture and 7(23.3%) were type 3 Neer’s fractures. 14(46.7%) patients were less than 40 years of age ,8(26.7%) patients were of 40-50 years and 8(26.7%) patients were more than 50 years. Lateral clavicle locking plate was performed in 14(93.3%) Neer’s type2 patients and 1(6.7%) Neer’s type 3 patients. Hook plate was performed in 9(60%) Neer’s type 2 patients and 6(40%) Neer’s type 3 patients.

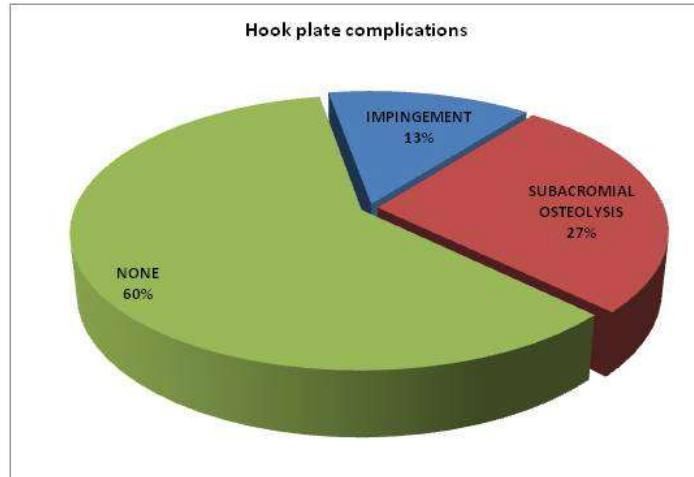


Constant murley score excellent outcome was seen in 1(6.7%) of Lateral clavicle locking plate group and 4(26.7%) of Hook plate group. Good outcome was seen in 10(66.7%) of Lateral clavicle locking plate group and 11(73.3%) of Hook plate group. Fair outcome was seen in 4 (26.7%) of Lateral clavicle locking plate group and there were no patients of Hook plate group. The mean duration of fracture union was 13.3 weeks in Lateral clavicle locking plate group and 12.6 weeks in hook plate group.

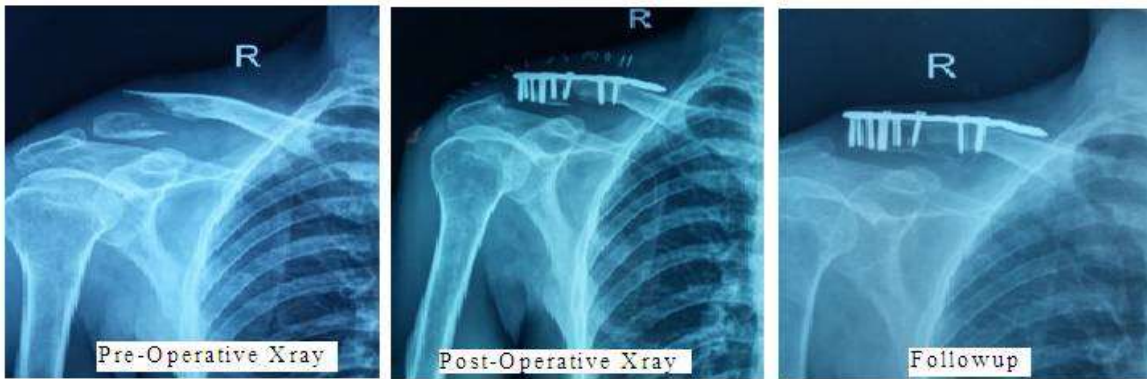

In the Lateral clavicle locking plate group 3(20%) patients had Acromioclavicular dislocation and 1(7%) patient had Plate backout with dislocation. In the Hook plate group 2(13.3%) patients had impingement and 4(26.7%) patients had subacromial osteolysis.

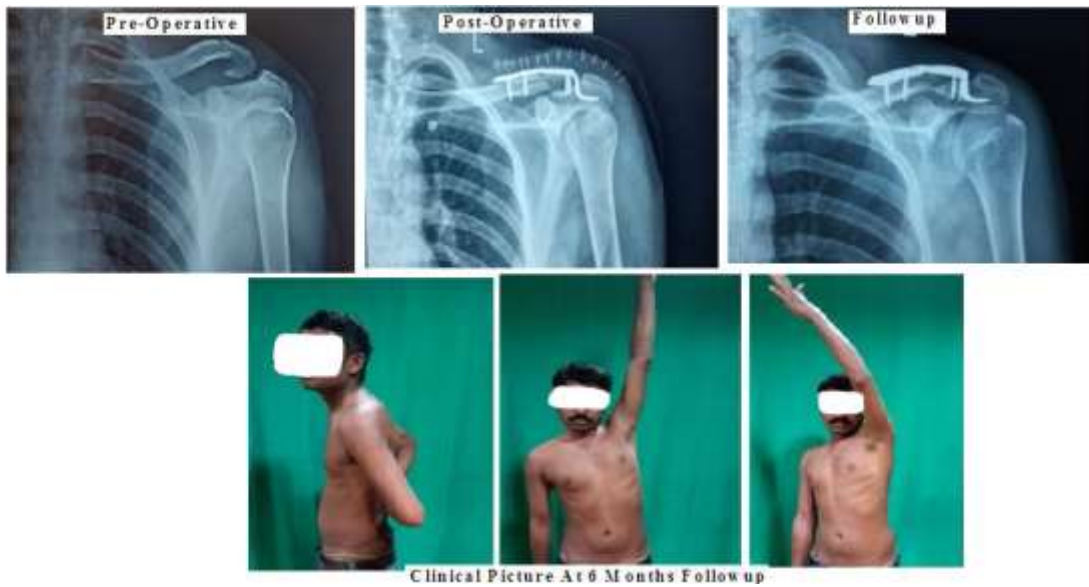



CASE 1



Case 2



DISCUSSION

The optimal treatment of unstable distal clavicle fractures is still controversially discussed in the literature. Unstable distal clavicle fractures often require open reduction and internal fixation. Most studies report using hook plate and locking plate on a small number of cases, as incidence of this specific injury is low. The use of a hook plate in the treatment of fractures of the lateral end of the clavicle is shown to be a good and acceptable treatment option.[6] In our study also, we found that hook plate had 100% union and 26.7% had excellent outcome 73.3% had a good outcome which was comparable to the above study. In regards to the use of a hook plate, there are debatable statements regarding retaining the implant for a more longer duration as against removal when the patient is symptomatic.[7] In our study, we found that 40% of patients had implant-related complications, but the functional outcome was good to excellent outcome in 100% patients. Most of the patients in this study had an excellent or good outcome which is similar to the findings of various other studies.[8,9,10] There is literature questioning the need for either simultaneous reconstruction or repair of the ligaments along with hook plate method of fixation, further suggesting implant removal after radiological or clinical indication and /or reconstruction after plate removal depending on the instability.[11] In our study, we did not reconstruct the ligaments, 5 patients had an excellent outcome as assessed by Constant score. These results are comparable to other studies using a hook plate.[12] We have noted the following complications: impingement occurred in 2 patients and osteolysis at the tip of the hook in 4 patients. These results are comparable with other studies.[13] The presence of osteolysis between the plate and the acromion has been attributed to the rotational movement (micro motion) which occurs with shoulder movements resulting in rotation of clavicle and the hook plate in respect to the acromion.[14] Senthil Loganathan concluded that there is a variation in the anatomy of the acromion in different ethnic groups. Hence a uniform sized hook plate will be inappropriate. A smaller hook depth is needed in South Asian population to prevent impingement and Intraoperatively distance between the acromion and supraspinatus tendon should be measured using depth gauge.[15] In our study, we found that, in comminuted fracture the placement of the screws for each fragment in lateral end locking plate was difficult, whereas hook plate did well in presence of comminution. In a meta-analysis by Stegeman et al. the hook plate and other fixation methods in the treatment of fracture were compared. There was no difference between the hook plate and other methods with respect to functional results and time to union. But the hook plate fixation was associated with an 11-fold increased risk of major

complications compared to intramedullary fixation and a 24-fold increased risk compared to suture anchoring.[16] In our study we found that the hook plate had a 40% of implant-related complication which was similar to above study. Shin et al. reported satisfactory clinical outcomes and high union rates using anatomic clavicle LCP fixation in patients with unstable distal clavicle fractures, even when the lateral fragment was small. They tried to insert more than 4 small screws in the distal fragment to achieve secure fixation. Even though the aim of open reduction and internal fixation is to obtain absolute stability, it is challenging to achieve in cases of unstable distal-third clavicle fractures, particularly in comminuted distal fragments. In some comminuted fracture cases, it is difficult to insert even 2 distal screws. Although recent studies have demonstrated satisfactory clinical and radiologic outcomes after treating Neer type II distal clavicle fracture using anatomic clavicle LCP, we thought that it would be difficult to control the force of the trapezius pulling on the proximal fragment superiorly if we could not insert enough screws in the distal fragment with anatomic clavicle LCP. Therefore, we hypothesized that the AO hook LCP could be an alternative option. Although there is no consensus as to a “gold standard” fixation method for Neer type II distal clavicle fractures, we obtained satisfactory outcomes using the AO hook LCP, despite not repairing or augmenting the coracoclavicular ligament. The favourable outcomes of this study may be due to the traits of the AO hook LCP. Just as in cases of acromioclavicular joint dislocation, this plate does not compress the fracture site firmly but instead works like a lever arm to maintain the level and alignment between the distal fragment and the proximal fragment, which may have migrated superiorly.[17]. Fleming et al. reviewed [19] patients who underwent surgery with superior pre-counteracted locking plates for displaced distal-third clavicle fractures[18]. All patients achieved union by 4 months and no plates have been removed. In our study also, the mean union time was same around 13.3 weeks or 4 months. The rate of union in the present study were similar to other studies by Robinson et al.[19], and Rokito et al.[20] In the study conducted by Klein et al. for locking plates, had a high union rate (near 100% overall) and relatively few complications. Of 64 total patients, there were five reported complications, including two infections, two occurrences of screw loosening, and one malunion.[21] In our study we found that one patient had hardware problem and there was need to remove implant after surgery. Our results compare favorably with these studies in terms of union rates, function. In a study conducted by Qureshi et al. for locking plates, had a union rate of 97.7% and constant murley score excellent to good outcome of 73% patients.[22] In our study there

was 100% union and constant murley score excellent to good outcome in 73% patients which was comparable to the above study.

CONCLUSION

Therefore no significant difference was found between locking plate and hook plate groups in union rate and Constant score ($P > 0.05$). However, the results indicated that the distal clavicular locking plate group had a significantly lower rate of complications ($P < 0.05$) and symptomatic hardware ($P < 0.05$). In addition, the distal clavicular locking plate facilitated the return to work better than the clavicular hook plate ($P < 0.05$). From the analysis of this study the following were noted:

1. The lateral end Clavicle locking plate as well as hook plate leads to sufficient stabilization and good functional outcome.
2. The locking plate technique does not cause rotator cuff injury or subacromial impingement and thus, does not require plate removal.
3. AC joint dislocation in locking plate was one of the complications. The reconstruction of the Coracoclavicular ligaments additionally to locking plate osteosynthesis can show superior biomechanical stability results.
4. Clavicle hook plate fixation is an absolute indication for the comminuted lateral clavicle fracture. It facilitates early mobilization of the shoulder postoperatively and results in a high percentage of union with a good objective and subjective shoulder function.
5. We conclude that in cases with far cortex comminution or avulsion injuries of CC ligaments, where it would be difficult to get screw purchase through the avulsed or comminuted fragment, chances of implant pullout is more. Such cases should be treated with lateral clavicle locking plate with reconstruction of CC ligaments or can also be treated with hook plate alone.

REFERENCES

1. Sajid S, Fawdington R, and Maneesh Sinha M. Locking plates for displaced fractures of the lateral end of clavicle: Potential pitfalls. *Int J Shoulder Surg.* 2012 OctDec; 6(4): 126-9.
2. Balaji Sambandam, Rajat Gupta, Santosh Kumar, Lalit Maini Fracture of distal end clavicle: A review journal of clinical orthopaedics and trauma 5 (2014) 65 e7 3
3. Edward A perez, Fractures of shoulder, arm and forearm, Campbells Operative Orthopaedics 12th ed 2836 pg
4. Lu C, Kao F, Hsu K, et al. Evaluation of a clavicle hook plate for fixation of unstable distal end comminuted clavicle fractures: seven case reports. *Formos J Musculoskelet Disord.* 2011;2:102-105
5. Constant CR, Murley AG. A Clinical Method of Functional Assessment of the Shoulder. *Clinical Orthopaedics and Related Research* 1987;214-216

6. Prasad VK, MedaBhuvaneswarM, ChrisSinopidis, Ian Braithwaite, Peter Brownson, Simon P. Frostick Clavicular hook plate for lateral end fractures—A prospective study 2006;37:277-283.
7. Ejam S, Lind T, Falkenberg B. Surgical treatment of acute and chronic acromioclavicular dislocation Tossy type III and V using the Hook plate. *Acta Orthop Belg.* 2008 Aug;74(4):441-445
8. Xue L, Chen Q, Zhou Z. [Clinical effects of clavicular hook plate for Neer type II fracture of distal clavicle]. *ZhongguoXiu Fu Chong Jian Wai Ke Za Zhi.* 2007 Sep; 21(9):979981.
9. Haidar SG, Krishnan KM, Deshmukh SC. Hook plate fixation for type II fractures of the lateral end of the clavicle. *J Shoulder Elbow Surg* 2006; 15:419-23.
10. OhJH, KimSH, LeeJH, ShinSH, GongHS. Treatment of distal clavicle fracture: a systematic review of treatment modalities in 425 fractures. *Arch Orthop Trauma Surg* 2011; 131:525-33
11. Sun S, Gan M, Sun H, Wu G, Yang H, Zhou F. Does subacromial osteolysis affects shoulder function after clavicle hook plating? *Biomed Res Int* 2016; Feb 2016 44-48
12. Hackenbruch W, Regazzoni P, Schwyzer K. Surgical treatment of lateral clavicular fracture with the “clavicular hooked plate” 1994; 87:145-52. 13.
13. Nadarajah R, Mahaluxmivala J, Amin A, Goodier D W. Clavicular hook-plate: complications of retaining the implant. *Injury* 2005; 36: 681-3.
14. LinHY, Wong PK, HoWP, ChuangTY, LiaoYS, WongCC. Clavicular hook plate may induce subacromial shoulder impingement and rotator cuff lesion—dynamicsonographic evaluation. *J OrthopSurg Res* 2014; 9:6.
15. Senthil Loganathan, ShenbaghavalliThanikaimalai, JambuNageshwaran, Samuel ChittaranjanClavicle Hook Depth and Impingement Syndrome—A Cause-Effect Relationship *Open Journal of Orthopedics* Vol.7 No.1
16. Stegeman Sylvania A., NacakHakan, Huvenaars Koen HJ., Stijnen Theo, Krijnen Pieta,Schipper Inger B. Surgical treatment of Neer type-2 of the distal clavicle, a metaanalysis. *Acta Orthop.* 2013; 84:184-189.
17. Shin SJ, Ko YW, Lee J, Park MG. Use of plate fixation without coracoclavicular ligament augmentation for unstable distal clavicle fractures. *J Shoulder Elbow Surg* 2016; 25:942-8.
18. Fleming MA, Dachs R, Maqungo S, du Plessis JP, Vrettos BC, Roche SJ. Angular stable fixation of displaced distal-third clavicle fractures with superior precontoured locking plates *J Shoulder Elbow Surg.* 2015 May;24(5):700-4
19. Robinson CM, Akhtar MA, Jenkins PJ, Sharpe T, Ray A, Olabi B. Open reduction and endobutton fixation of displaced fractures of the lateral end of the clavicle in younger patients. *J Bone Joint Surg Br.* 2010 Jun 1; 92-B(6):811-816.
20. Rokito AS, Zuckerman JD, Shaari JM, Eisenberg DP, Cuomo F, Gallagher MA. A comparison of nonoperative and operative treatment of type II distal clavicle fractures. *Bull Hosp Jt Dis.* 2002;61(1-2):32-3
21. Klein SM, Badman BL, Keating CJ, Devinney DS, Frankle MA, Mighell MA. Results of surgical treatment for unstable distal clavicular fractures. *J Shoulder Elbow Surg.* 2010; 19:1049-1055.
22. Qureshi Faisal, Sharma Gaurav Mahesh, Naik Lokesh Gudda, BadgireKrishnaSudhakar, Waghchoure Chaitanya. Treatment of lateral third clavicle fractures bylocking compression plate- a prospective study. *Intl. J. Clin. Diag. Res.* 2017; 5(4):78-84.