

Original Research

Comparison of paravertebral block vs erector spinae plane block in breast surgery patients

Dr. Abrar Mohammad¹, Col. (Retd.) Dr. Manish Gupta²

¹Assistant professor, Department of Anaesthesia, Prasad Institute of Medical Sciences, Lucknow, Uttar Pradesh, India;

²Ex Classified Specialist, Army Medical Corps, 92 Base Hospital (J&K)

ABSTRACT:

Background: A mastectomy is complete removal of the breast tissue in patients diagnosed with breast cancer. The present study compared the analgesic effect of paravertebral block (TPVB) and erector spinae plane block (ESPB) in breast surgery patients.

Materials & Methods: The present study was conducted on 60 adult female patients diagnosed with breast cancer. Patients were divided into 2 groups of 30 each. Group I patients receive TPVB and group II received ESPB. **Results:** ASA grade I was seen in 20 in group I and 22 in group II and grade II in 10 in group I and 8 in group II. Duration of surgery was 172.4 minutes in group I and 170.1 minutes in group II, intra-operative fentanyl consumption was 141.5 µg in group I and 134.2 µg in group II, total post-operative morphine was 28.2 mg in group I and 26.1 mg in group II and time to first analgesic request was 6.15 hours in group I and 6.24 hours in group II. Post operative complications was nausea in 10 in group I and 8 in group II, vomiting in 4 in group I and 2 in group II and pneumothorax 5 in group I and 1 in group II. **Conclusion:** Authors found that Both TPVB and ESPB can be effectively used in reducing intra-operative and post-operative opioid consumption.

Key words: Erector spinae plane block, Mastectomy, Thoracic paravertebral block

Received: 02/04/2020

Accepted: 15/06/2020

Corresponding author: Dr. Col (Retd) Dr. Manish Gupta, Ex Classified Specialist, Army Medical Corps, 92 Base Hospital (J&K), India

This article may be cited as: Mohammad A. Comparison of paravertebral block vs erector spinae plane block in breast surgery patients. J Adv Med Dent Sci Res 2020;8(8):199-202.

INTRODUCTION

A mastectomy is defined as the complete removal of the breast tissue in patients diagnosed with breast cancer as well as a prophylaxis to reduce the risk of breast cancer in high-risk women.¹ Mastectomy is preferred in those patients in which for breast conserving therapy cannot be performed.² It is also done in patients who prefer mastectomy and for prophylactic purposes to reduce the risk of breast cancer. Post-mastectomy analgesia consists of many regional techniques. Paravertebral block (PVB) is the most effective technique for intra-operative and post-operative analgesia. Paravertebral block involve injection of local anaesthetic in a space immediately lateral to where the spinal nerves emerge from the intervertebral foramina. It is a sole anaesthetic technique for carrying out various procedures but due to

its anatomic proximity to pleura and central neuroaxial system, it is a challenging one.³

Erector spinae plane block (ESPB) has been used successfully for post-operative analgesia in breast surgeries.⁴ ESP block uses ultrasound to deposit LA deep to the 3 columns of ES muscles (iliocostalis, longissimus, spinalis), which run the length of the spine from the base of the skull to the medial crest of the sacrum. They all have attachments to the transverse processes, the level of which is dependent on the specific muscle. Overlying the ES complex are 2 further layers of muscle: the trapezius and rhomboid major.⁵ The present study compared the analgesic effect of paravertebral block (TPVB) and erector spinae plane block (ESPB) in breast surgery patients.

MATERIALS & METHODS

The present study was conducted in the department of Anesthesiology. It comprised of 60 adult female patients diagnosed with breast cancer. They were in age range of 20-50 years belonged to the American Society of Anesthesiologists' (ASA) physical status I or II. All patients were informed regarding the study and written consent was obtained. The study protocol was approved from institutional ethical committee.

Patient particular such as name, age, etc. was recorded. Patients were divided into 2 groups of 30 each. Group I patients receive TPVB and group II received ESPB. Single anaesthetist performed general anaesthesia (GA)

and regional block. All operations were done by the same surgeon. A thorough clinical examination was performed and routine blood investigations such as complete blood count, liver function tests, renal function tests, chest X-ray and electrocardiography was performed. Variables such as intra-operative fentanyl consumption (μg), total post-operative morphine, time to first analgesic request etc. was recorded. Results thus obtained were subjected to statistical analysis. P value less than 0.05 was considered significant.

RESULTS

Table I Comparison of parameters

Parameters	Group I (30)	Group II (30)	P value
ASA			
I	20	22	0.05
II	10	8	
Duration of surgery (mins)	172.4	170.1	0.71
Intra-operative fentanyl consumption (μg)	141.5	134.2	0.82
Total post-operative morphine (mg)	28.2	26.1	0.94
Time to first analgesic request (hours)	6.15	6.24	0.75

Table I, graph I shows that ASA grade I was seen in 20 in group I and 22 in group II and grade II in 10 in group I and 8 in group II. Duration of surgery was 172.4 minutes in group and 170.1 minutes in group II, intra-operative fentanyl consumption was 141.5 μg in group I and 134.2 μg in group II, total post-operative morphine was 28.2 mg in group I and 26.1 mg in group II and time to first analgesic request was 6.15 hours in group I and 6.24 hours in group II. The difference was non- significant ($P > 0.05$).

Graph I Comparison of parameters

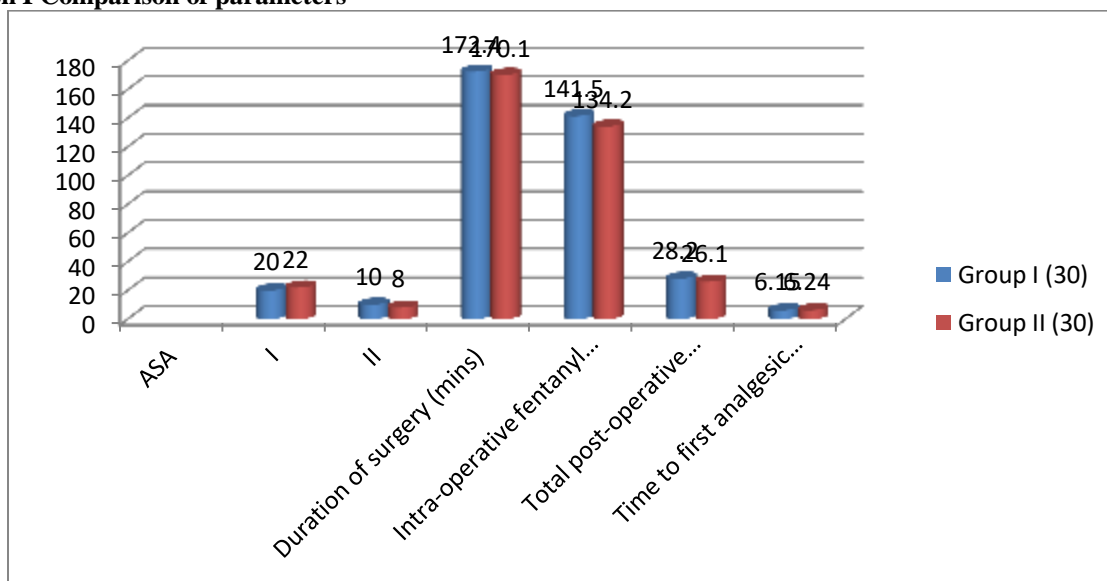
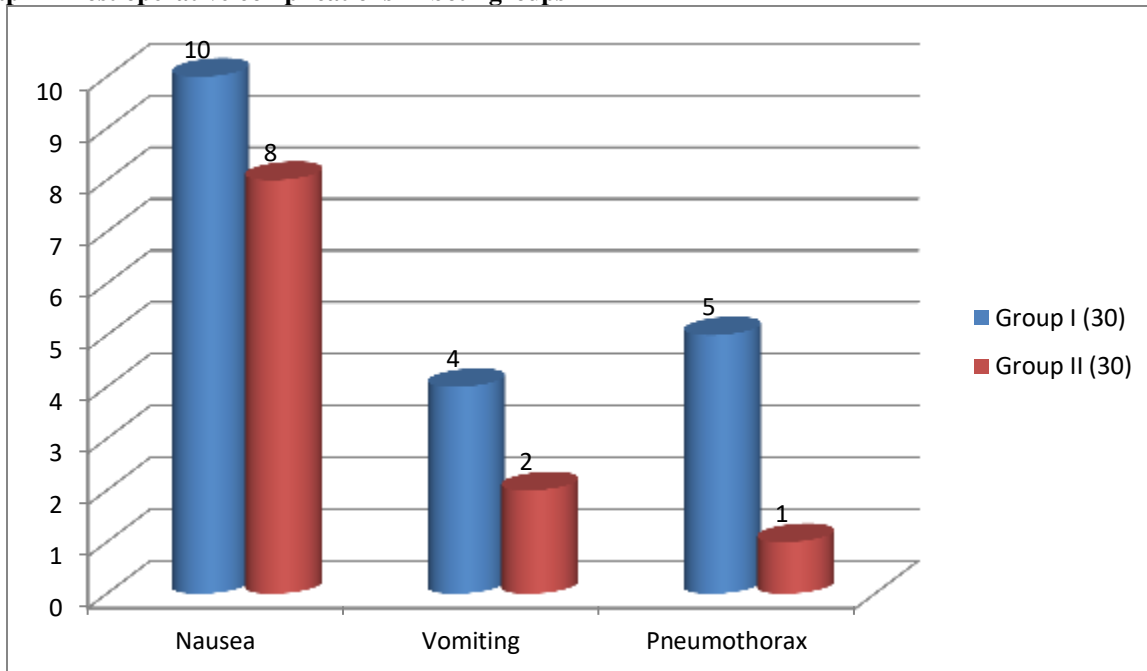


Table II Post operative complications in both groups

Complications	Group I (30)	Group II (30)	P value
Nausea	10	8	0.81
Vomiting	4	2	0.71
Pneumothorax	5	1	0.12

Table II, graph II shows that post operative complications was nausea in 10 in group I and 8 in group II, vomiting in 4 in group I and 2 in group II and pneumothorax 5 in group I and 1 in group II. The difference was non- significant (P> 0.05).

Graph II Post operative complications in both groups



DISCUSSION

A thoracic paravertebral injection of local anaesthetics results in ipsilateral somatic and sympathetic nerve block including the posterior ramus in multiple contiguous thoracic dermatomes.⁶ The spinal nerves in this space are devoid of a fascial sheath, making them exceptionally susceptible to local anaesthetics. Injecting LA into the paravertebral space resulted in an analgesic effect.⁷ This occurred through direct contact with the spinal nerve roots and the spread of LA into the epidural space.⁸ Thus, the TPVB can unilaterally cause both somatic and sympathetic nerve block. The ESPB causes the same effect. It blocks the dorsal and ventral rami of the spinal nerves as the LA diffuses anteriorly into the adjacent paravertebral and inter-costal spaces. Therefore, it is considered a peri-paravertebral regional technique.⁹ The present study compared the analgesic effect of paravertebral block (TPVB) and erector spinae plane block (ESPB) in breast surgery patients.

In this study, patients were divided into 2 groups of 30 each. Group I patients receive TPVB and group II received ESPB. El Ghamry et al¹⁰ found that

post-operative 24 hours morphine consumption and time of the first request for analgesia were comparable between both groups (P = 0.32 and 0.075, respectively). There was no significant difference in the intra-operative fentanyl consumption. There was also no significant difference in VAS between both groups over the 24 h of study. Four patients in group I developed pneumothorax with no significant differences between both groups (P = 0.114). Incidence of nausea and vomiting was comparable between both groups. All patients displayed a stable hemodynamic profile.

We found that ASA grade I was seen in 20 in group I and 22 in group II and grade II in 10 in group I and 8 in group II. Duration of surgery was 172.4 minutes in group and 170.1 minutes in group II, intra-operative fentanyl consumption was 141.5 µg in group I and 134.2 µg in group II, total post-operative morphine was 28.2 mg in group I and 26.1 mg in group II and time to first analgesic request was 6.15 hours in group I and 6.24 hours in group II.

Gürkan et al¹¹ conducted a study and found that total 24 h morphine consumption decreased by 65% in patients who received single-shot US-guided ESPB using 20 ml of 0.25% bupivacaine after breast surgery. However, there was no significant difference in pain scores between the ESPB group and the control group.

We observed that post operative complications was nausea in 10 in group I and 8 in group II, vomiting in 4 in group I and 2 in group II and pneumothorax 5 in group I and 1 in group II. Davies et al¹² compared analgesic efficacy and side-effects of paravertebral vs epidural blockade for thoracotomy and found that the incidence of PONV decreased in patients who received PVB.

CONCLUSION

Authors found that Both TPVB and ESPB can be effectively used in reducing intra-operative and post-operative opioid consumption.

REFERENCES

1. Altıparmak B, Toker MK, Uysal Aİ, Demirbilek SG. Comparison of the efficacy of erector spinae plane block performed with different concentrations of bupivacaine on postoperative analgesia after mastectomy surgery: Randomized, prospective, double-blinded trial. *BMC Anesthesiol* 2019;19:31.
2. El Mourad MB, Amer AF. Effects of adding dexamethasone or ketamine to bupivacaine for ultrasound-guided thoracic paravertebral block in patients undergoing modified radical mastectomy: A prospective randomized controlled study. *Indian J Anaesth* 2018;62:285-91.
3. Krishna SN, Chauhan S, Bhoi D, Kaushal B, Hasija S, Sangdup T, et al. Bilateral erector spinae plane block for acute post-surgical pain in adult cardiac surgical patients: A randomized controlled trial. *J Cardiothorac Vasc Anesth* 2019;33:368-75.
4. Singh S, Chowdhary N. Erector spinae plane block an effective block for postoperative analgesia in modified radical mastectomy. *Indian J Anaesth* 2018;62:148-9.
5. Takahashi H, Suzuki T. Erector spinae plane block for low back pain in failed back surgery syndrome: A case report. *J A Clin Rep* 2018;4:60.
6. Law LS, Tan M, Bai Y, Miller TE, Li YJ, Gan TJ. Paravertebral block for inguinal herniorrhaphy: A systematic review and meta-analysis of randomized controlled trials. *Anesth Analg* 2015;121:556-69.
7. Aufforth R, Jain J, Morreale J, Baumgarten R, Falk J, Wesen C. Paravertebral blocks in breast cancer surgery: Is there a difference in postoperative pain, nausea, and vomiting? *Ann Surg Oncol* 2012;19:548-52.
8. Naja Z, Lönnqvist PA. Somatic paravertebral nerve blockade incidence of failed block and complications. *Anaesthesia* 2001;56:1181-201.
9. Pace MM, Sharma B, Anderson-Dam J, Fleischmann K, Warren L, Stefanovich P. Ultrasound-guided thoracic paravertebral blockade: A retrospective study of the incidence of complications. *Anesth Analg* 2016;122:1186-91.
10. El Ghamry MR, Amer AF. Role of erector spinae plane block versus paravertebral block in pain control after modified radical mastectomy. A prospective randomised trial. *Indian J Anaesth* 2019;63:1008-14.
11. Gürkan Y, Aksu C, Kuş A, Yörükoğlu UH. Erector spinae plane block and thoracic paravertebral block for breast surgery compared to IV-morphine: A randomized controlled trial. *J Clin Anesth* 2020;59:84-8.
12. Davies R, Myles P, Graham J. A comparison of the analgesic efficacy and side-effects of paravertebral vs epidural blockade for thoracotomy a systematic review and meta-analysis of randomized trials. *Br J Anaesth* 2006;96:418-26.