

Journal of Advanced Medical and Dental Sciences Research

@Society of Scientific Research and Studies

Journal home page: www.jamdsr.com

doi: 10.21276/jamdsr

ICV 2018= 82.06

(e) ISSN Online: 2321-9599;

(p) ISSN Print: 2348-6805

Case Report

Reduction of Depressed Zygomatic Arch Fracture using Dental Extraction Forcep: A Case Report with Review of Literature

Kahamnuk Jamatia¹, Rahul Deb², David Debbarma³, Rishabh Bhanot⁴, Megha Sahu⁵, Monika Gahlawat⁶, Rahul Vinay Chandra Tiwari⁷

¹MDS (OMFS) Asst professor, Deptt of Dentistry, AGMC and GBP Hospital, Agartala;

²MDS, Consultant Oral & Maxillofacial Surgery, Agartala;

³BDS, Private Practitioner, Agartala;

⁴Consultant Oral and Maxillofacial surgeon, SRCJC hospital, Ludhiana;

⁵Fellow in GSR Institute of Craniofacial Surgery, IS Sadan, 17-1-383/55, Vinay Nagar Colony, Vinayak Nagar Colony, Saroonagar, Hyderabad, Telangana;

⁶Senior Lecturer, Department of OMFS, Maharaja Ganga Singh Dental College & Research Centre, 11 L.N.P, Hanumangarh Rd, Sri Ganganagar, Rajasthan;

⁷FOGS, MDS, Assistant Professor, Department of Oral and Maxillofacial Surgery, Sri Sai College of Dental Surgery, Vikarabad, India

ABSTRACT:

Dental surgeons can frequently come across patients of zygomatic arch fractures as inability to open mouth fully is one of the main complains of such patients. In a rural set up where the facilities of general anesthesia or proper armamentariums are not available, the reduction of zygomatic arch fractures using simple and easily available dental extraction forceps provides a simple and economically viable alternative treatment. One such Patient was operated in our clinic representing unilateral depressed zygomatic arch fracture. The patient's complaint was pain, and difficulty in mouth opening. Fracture were confirmed with computerized tomography. The fracture was reduced with upper buccal sulcus approach by dental extraction forcep. Patient achieved satisfactory maximum mouth opening immediately after reduction. Post operative SWM radiograph revealed satisfactory reduction. This procedure is cost effective, time saving, safe and effective to manage isolated zygomatic arch fractures under local anaesthesia with satisfactory outcomes.

Key words: Zygomatic arch fracture, dental extraction forceps, buccal sulcus approach.

Received: 22 August, 2019

Revised: 19 October, 2019

Accepted: 22 October, 2019

Corresponding author: Dr. Rahul Vinay Chandra Tiwari, Assistant Professor, Department of Oral and Maxillofacial Surgery, Sri Sai College of Dental Surgery, Vikarabad, India

This article may be cited as: Jamatia K, Deb R, Debbarma D, Bhanot R, Sahu M, Gahlawat M, Tiwari RVC. Reduction of Depressed Zygomatic Arch Fracture using Dental Extraction Forcep: A Case Report with Review of Literature. J Adv Med Dent Scie Res 2019;7(11):179-182.

INTRODUCTION

Isolated zygomatic arch fracture is rare in zygomaticomaxillary complex fracture, representing approximately 10% of all cases in the literature.¹⁻³

There are several conventional techniques that can be used for reducing isolated zygomatic arch fractures such as: the Gillies temporal approach, hook elevation, upper buccal sulcus technique, intranasal transantral

approach, and open reduction.^{2,4,5} Besides, many devices such as; elevators, towel, curved mosquito, different types of hooks, aqua splint and percutaneous wire suture technique were defined to immobilize the repositioned fragments.^{6,7} Although these techniques are noninvasive, treatment of zygomatic arch fractures depends on aesthetic and functional defect and the degree-types of displacement.^{1,3,5,6} However, there is limited information about the effectiveness of extraction forceps in reducing zygomatic arch fractures in the literature. The purpose of documenting this case is to present the simplicity and outcomes of reduction of isolated zygomatic arch fractures using dental extraction forceps as a reduction instrument through upper buccal sulcus technique.

CASE REPORT

A 39 years old male patient reported to our clinic with the chief complaints of pain on right side of the face and inability to open mouth properly following history of RTA due to fall from two wheeler. After primary treatment at PHC Patient didn't show any improvement so he consulted a dental surgeon at a rural private clinic, who then consulted an oral and maxillofacial surgeon for opinion. On clinical examination patient had abrasions over right zmc region, difficulty in mouth opening and depression in right zygomatic arch region which was tender on palpation(fig 1 and 2). There was no other medical comorbidities. Pre-op. mouth opening was 2.5cms (fig 3). and patient was sent to the city and Zygomatic arch fracture was confirmed with computerized tomography (CT) images (Fig 4) and classified according to Yamamoto classification system² into Type II (displacement with bone contact at all fracture lines). Patient was informed about the possible risks and benefits of the procedure and signed a detailed consent form. Taking into consideration pt.s poor economic condition and lack of infrastructure in the private dental clinic, reduction was planned under local anaesthesia using dental extraction forceps through intra oral buccal sulcus approach. After local anaesthesia, a horizontal incision was made in the free gingiva for a distance of approximately 2 cm over the zygomatic buttress extending through the mucosa, submucosa, and any buccinator muscle fibers (Figure-5). After the mucoperiosteal elevation, zygomatic arch was felt and one handle of a extraction forceps was inserted into the wound under the fractured area and advanced posteriorly, as well as superiorly (Figure-6 and 7). The depressed zygomatic arch was elevated into its proper anatomical position by the forceps with controlled force while the reduced area was palpated by the surgeon's other hand extraorally. And then, the forceps were moved back and forth to check whether the arch was in the correct position. Patient gained satisfying mouth

opening immediately of 4cms(Fig no.8). The wound area was closed with 3/0 vicryl. The patient was then discharged after the operation and suggested avoiding direct force on the operated site and not to sleep on the affected side for a period of 8 weeks. The patient maintained his moth opening after 15 days follow up with no complications such as infections, trismus and nerve damage. Postoperative radiograph was taken later in a government hospital to confirm the adequacy of zygomatic arch reduction (Figure-9). The patient was followed up for 3 months and no additive operation was necessary.

Fig no.1 frontal profile

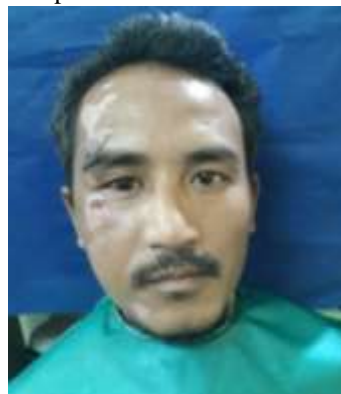

Fig no.2 depression right zygomatic arch

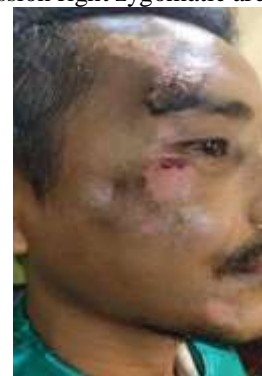

Fig no3. Pre ope mouth opening

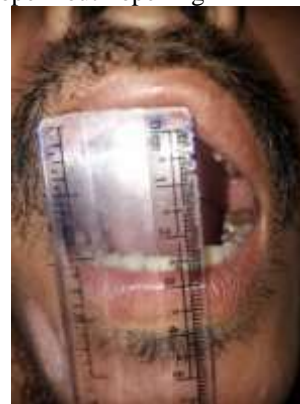

Fig no.4 CT scan showing fracture Right Zygomatic Arch

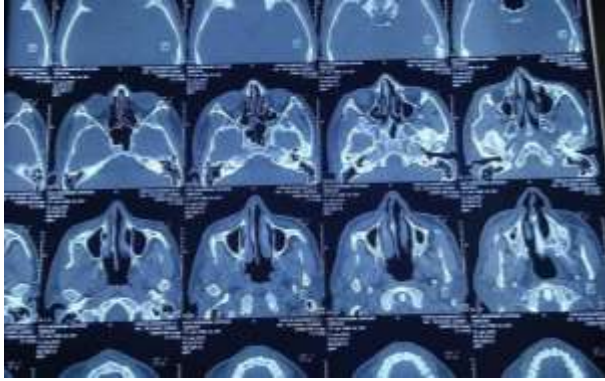


Fig no.7 extraction forcep view from lateral side

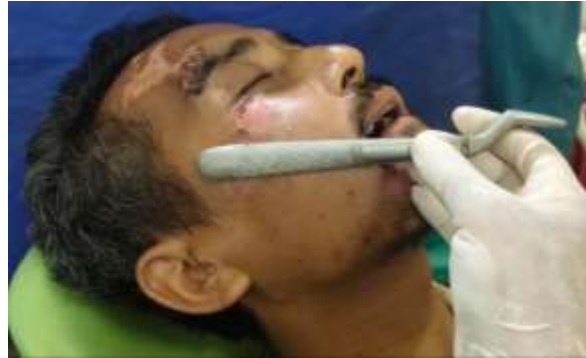

Fig no.5 Surgical Site

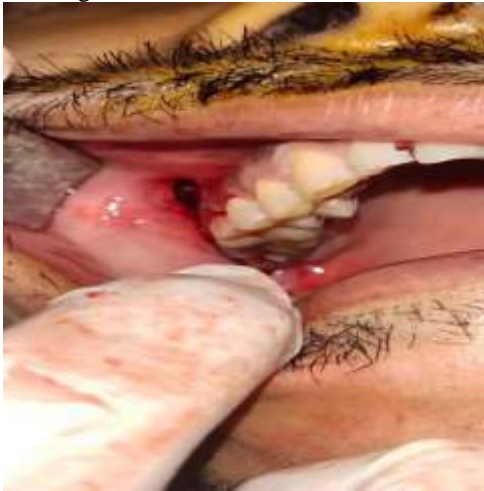

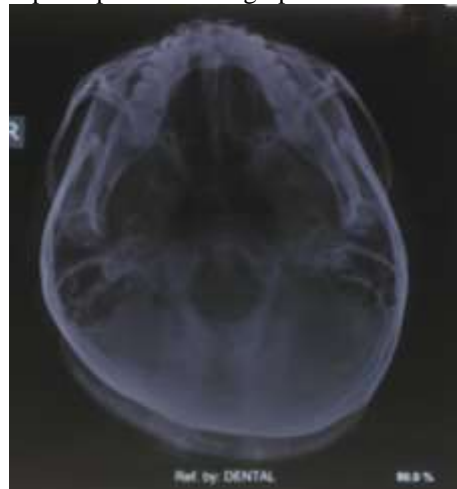
Fig no. 8 immediate post op mouth opening

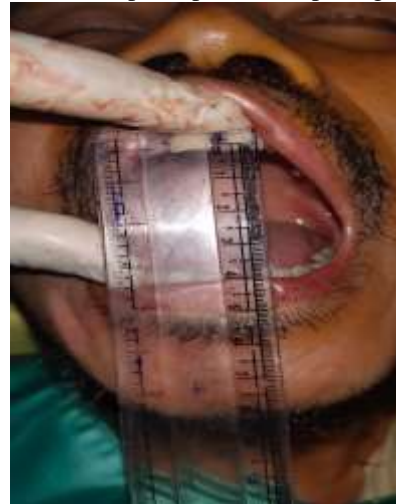

Fig no.6 Extraction Forcep during reduction

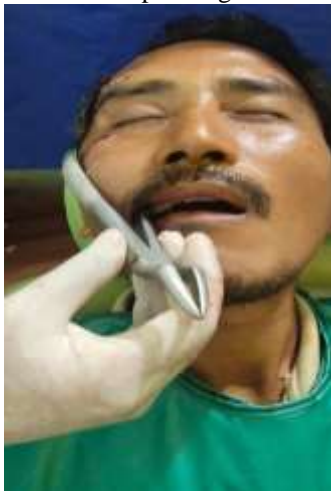

Fig no.9 post operative radiograph



DISCUSSION

Considering the economic status of the patients and available dental chair side infrastructure, sometimes we oral surgeons have to adapt to different techniques and devices that have been described by many authors concerning the evaluation and treatment of zygomatic arch fractures.³ It is of utmost importance that adequate technique and instrument in treatment of zygomatic arch fracture is selected because inadequate stabilization and reduction of zygomatic arch may result in malunion or asymmetry.^{1,8} In the present study, we used extraction forcep for reduction of depressed zygomatic arch fracture by Keens upper buccal sulcus approach. The result achieved was satisfactory without any complication. Traditionally Gilles Temporal approach has been more widely used for the treatment of zygomatic arch fracture due to several benefits such as easy to achieve, little risk of nerve damage or direct trauma to globe.³ However it also has certain disadvantages such as scar in visible area and also needs large forces to reduce the fragments.¹ Recently, the intra oral approach of Keen has become quite an effective technique in the management of zygomatic arch fractures because of advantages of no visible scar and minimal surgical procedures over the Gilles temporal approach.^{2,3,9} Courtney⁹ was of the opinion that upper buccal sulcus technique using Bristow's or Rowe's elevator was successful in elevating the depressed zygomatic complex and arch regardless of the time lag between injury and surgical reduction. Krishnan B et al⁸ treated twenty five patients with unilateral isolated zygomatic arch fractures by reduction of fractures by using a dental forceps through an upper buccal sulcus approach with pleasant results. They stated that performing this procedure under sedation or local anaesthesia in clinic setting or an emergency department makes it a highly cost-effective and time-saving tool in the armamentarium of an oral and maxillofacial surgeon. Some authors have also proposed the use of a towel for reducing depressed zygomatic arch fractures as a quick, simple and effective technique.¹⁰

Mezitis et al⁵ described the use of a curved mosquito for reducing isolated zygomatic arch fractures as a less invasive method. Different types of hooks have also been used for the reduction of those fractures.^{5,7} J shaped curved hook elevator, most frequently used, can be performed intraorally and extraorally, but it needs a preauricular stab incision and general anaesthesia and it may damage the facial nerve branches.⁷ Dong-Kyu Kim et al³ used aqua splint and suture technique for isolated zygomatic arch fractures with good facial contour and functional results. In addition, percutaneous reduction using a wire suture extraorally was described as a minimally invasive and excellent reduction method.⁶

However these techniques have a risk of weakness of facial nerve by pressure and may be more complicated compared to the other techniques.^{3,10}

Using dental extraction forceps through Keens intra oral approach method has many advantages in the management of isolated zygomatic arch fractures such as easy availability and lesser requirement of other armamentarium. Besides, the handle of Extraction forceps are blunt equipment so there is low risk of damage to soft tissues and less force is required for elevation of depressed fragment compared to using the elevators. The surgeon can also control the force and feel the reduction of fracture easily.

CONCLUSION

The use of dental extraction forceps for reduction of zygomatic arch fracture through intraoral approach is a simple technique that can be performed at any dental clinic under local anesthesia. As has been mentioned in various literatures and also seen in our case, this technique offers good functional, aesthetic and radiological outcome. Hence this can be the technique of choice for surgical treatment of simple isolated zygomatic arch fractures.

REFERENCES

1. Miloro M, Ghali GE, Larsen PE. Management of Zygomatic Complex Fracture. In: Bailey JS, Goldwasser MS, eds. *Principles Of Oral And Maxillofacial Surgery*. 2nd ed. London: BC Decker Inc, 2004; pp 445-62.
2. Yamamoto K, Murakami K, Sugiura T, Fujimoto M, Inoue M, Kawakami M, et al. Clinical analysis of isolated zygomatic arch fractures. *J Oral Maxillofac Surg* 2007; 65: 457-61.
3. Kim DK, Kim SK, Lee JH, Park CH. Aqua splint suture technique in isolated zygomatic arch fractures. *Eur Arch Otorhinolaryngol* 2014; 271: 707-11.
4. Robiony M, Tenani G, Bellini P, Salgarelli AC. Intraoral Approach for Aesthetic Restoration of Posttraumatic Zygomatic Arch Deformities. *J Craniofac Surg* 2012; 23: 1418-20.
5. Mezitis M, Stathopoulos P, Rallis G. Use of a Curved Mosquito for Reducing Isolated Zygomatic Arch Fractures. *J Craniofac Surg* 2010; 21: 1281-3.
6. Giudice A, Colangeli W, Cristofaro MG. Percutaneous reduction of an isolated zygomatic fracture using a wire suture. *Br J Oral Maxillofac Surg* 2013; 51: 201-2.
7. Zingg M, Laedrach K, Chen J, Chowdhury K, Vuillemin T, Sutter F, et al. Classification and treatment of zygomatic fractures: a review of 1,025 cases. *J Oral Maxillofac Surg* 1992; 50: 778-90.
8. Krishnan B, El Sheikh MH. Dental Forceps Reduction of Depressed Zygomatic Arch Fractures. *J Craniofac Surg* 2008; 19: 782-4.
9. Courtney DJ. Upper Buccal Sulcus Approach to Management of Fractures of the Zygomatic Complex: A Retrospective Study of 50 Cases. *Br J Oral Maxillofac Surg* 1999; 37: 464-6.
10. Hwang K, Lee SI. Reduction of zygomatic arch fracture using a towel clip. *J Craniofac Surg* 1999; 10: 439-41.