

Original Research

Efficacy of peizocision based flapless corticotomy in the orthodontic correction of class I and class II malocclusion: Rapid accelerated orthodontics

Alok Chourasia¹, Anurag Sahu²

¹Consultant Orthodontist, Atharv Dental Clinic and Orthodontic Centre, Maihar

²Consultant Orthodontist, Anurag Dental Clinic, Jabalpur.

ABSTRACT:

Background: Orthodontist as well as patients biggest challenge during orthodontic treatment is time. However for past few years researchers are making an effort to develop several surgical techniques to minimize the treatment time. Peizocision based flapless corticotomy in the orthodontic correction is minimally invasive in nature and is preferred these days. **Aim:** To assess Efficacy of peizocision based flapless corticotomy in the orthodontic correction of class I and class II malocclusion: Rapid accelerated orthodontics.

Method: A total 50 patients aged 18 to 25 in need of orthodontic treatment with a fixed orthodontic appliance were selected for the study. Patients were divided into two group study group and control group. Peizocision corticotomies were performed on patients in order to accelerate alignment for patients in the experimental group, whereas those in the control group received traditional orthodontic treatment. **Result:** Anchorage loss and canine distalization were found to be statistically significant ($p < 0.01$). The amount of distalization showed decrease duration of canine distalization. The pre- and post distalization mobility scores were not found significantly different between the two groups. **Conclusion:** Efficacy of peizocision based flapless corticotomy in the orthodontic correction of class I and class II malocclusion is considered to be effective method of treatment.

Key words: Tooth movement, surgical procedures, minimally invasive, piezosurgery.

Received: 13 March, 2019

Revised: 10 June 2019

Accepted: 12 June 2019

Corresponding author: Dr. Alok Chourasia, Consultant Orthodontist, Atharv Dental Clinic and Orthodontic Centre, Maihar

This article may be cited as: Chourasia A, Sahu A. Efficacy of peizocision based flapless corticotomy in the orthodontic correction of class I and class II malocclusion: Rapid accelerated orthodontics. J Adv Med Dent Scie Res 2019;7(8): 6-9.

INTRODUCTION:

An increasing number of patients are demanding orthodontic treatment for improved esthetics and/or a better mastication system.¹ However, patient these days prefer shorter treatment duration. Authors have suggested that patients who desire shorter time period for treatment completion due to social and psychological reasons, such treatment is possible only in conjunction with surgical procedures.^{2,3} According to literature, Harold Frost first termed the Regional Acceleratory Phenomenon. He described it as a cascade of physiologic healing events following surgical wounding of cortical bone.^{4,5}

The rate of biological orthodontic tooth movement is approximately 1 mm over 4 weeks. In regional acceleratory phenomenon rapid orthodontic tooth movement occurs along with periodontal augmentation with bone graft increases the alveolar bone and it also corrects alveolar bone dehiscences and fenestrations.⁶ Lee et al suggested that the biology associated with alveolar decortication, osteotomy and/or dental distraction techniques in relation to tooth movement.⁷ Ferguson et al reported that the onset of RAP in alveolar bone is accompanied by a burst of osteoclastic activity resulting in lower bone density and augmented osteoblastic activity.⁸ So in present study we made an attempt to study the efficacy of peizocision based

flapless corticotomy in the orthodontic correction of class I and class II malocclusion.

AIM:

To study the Efficacy of peizocision based flapless corticotomy in the orthodontic correction of class I and class II malocclusion: Rapid accelerated orthodontics.

MATERIALS AND METHODS:

This randomized controlled crossover clinical study was carried out in the department of orthodontics. Ethical committee approval was obtained from the Institutional Ethics Committee. A written informed consent was obtained from the parents of the selected children. A total of 50 patients aged 18 to 25 years in need of orthodontic treatment with a fixed orthodontic appliance were enrolled and randomly allocated to study and the control group. First premolar was extracted. After extraction, radiographic-guided micro incisions and localized piezocision corticotomies were performed in order to correct class I and class II malocclusion. All surgeries were carried out under local anesthesia (lidocaine hydrochloride 2% with epinephrine 1:100,000).

Group 1: n = 25 study group
 Group 2: n = 25 control group

Little's Irregularity Index (LII) was also calculated at monthly intervals. Randomization was performed using a software-generated list of random numbers; the recruited patients were divided into two parallel groups with a 1:1 allocation ratio. Assessor blinding was employed.

INCLUSION CRITERIA:

- 1) Patients aged 18 to 25 years with class I malocclusion,
- 2) Patients with class II malocclusion in need of orthodontic treatment.

EXCLUSION CRITERIA:

- Patients suffering from any systemic diseases.
- Physically and mentally challenged patients.

Statistical Analysis:

The values obtained during each session will be assessed, tabulated and subjected to appropriate statistical analysis.

RESULTS:

A total of 50 patients aged 18 to 25 years with class I and class II malocclusion and in need of orthodontic treatment were included in the present study. All the patients were divided in two groups based on the mode of treatment. Group 1 consisted of 25 patients undergoing piezocision treatment and group 2 consisted of 25 patients which were considered as our control group (Graph 1).

In current study for error analysis, coefficients were found to be close to 1.00. In addition, all measurements were performed to check error analyses of the tooth movements. The results ranged from .919 to .988. Table 1 represents time elapsed from canine distalization. In piezoelectric group we found that piezocision-assisted canine distalization decreased total treatment duration and anchorage loss in the molar region. Table 2 represents the amount of distalization and result showed decreased duration of canine distalization.

Our results showed that the amount of canine distalization was greater in the piezocision group than as compared to control group. Anchorage loss was measured and we found that anchorage loss for the first molars was comparatively less however the canine distalization was greater in the study group as compared to control group. The difference observed was statistically significant ($p < 0.01$). Whereas the pre- and postdistalization mobility scores were not found significantly different between the groups in present study.

GRAPH 1: DISTRIBUTION OF GROUP

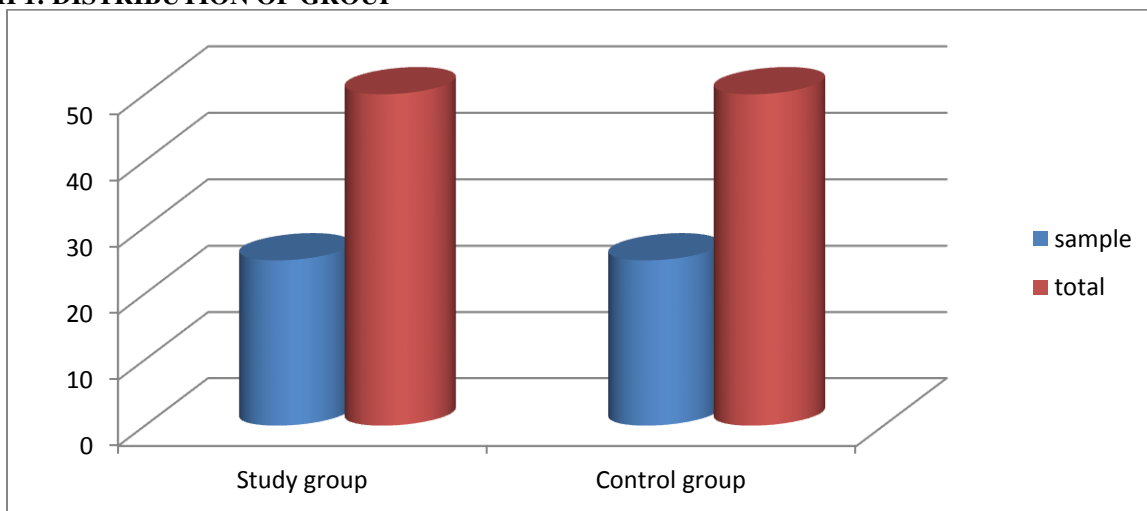


TABLE 1: TIME ELAPSED FROM CANINE DISTALIZATION

Groups	Mean	Min	Max
Study group	3.44±0.80	2.88	4.24
Control group	5.24±0.91	4.68	6.28

TABLE 2: AMOUNT OF DISTALIZATION

Groups	FIRST MONTH	SECOND MONTH
Study group	1.44±0.61	2.11±0.81
Control group	0.71±0.26	1.81±0.65

TABLE 3: ANCHORAGE LOSS OBSERVED

GROUPS	FIRST MONTH	MIN	MAX
Study group	2.01±0.61	1.58	2.44
Control group	3.01±0.39	2.86	3.46

Table 3: intra and inter group comparison of oxygen saturation between both groups

Visits	Group A	Group B	p value**
	Mean	Mean	
Screening and prophylaxis	99.8±1.2	98±1.7	-
Restoration	98.1±1.1	98.0±0.5	-
Extraction	97.0±1.3	97.0±0.5	-

DISCUSSION:

Corticotomy is considered to be effective in accelerating orthodontic treatment. The key to success in orthodontic treatment is proper case selection and careful surgical and orthodontic treatment. Corticotomy facilitated orthodontics advocated for comprehensive fixed orthodontic appliances in conjunction with full thickness flaps and labial and lingual corticotomies around teeth to be moved. Bone graft should be applied directly over the bone cuts and the flap sutured in place. Orthodontic treatment time with this technique will be reduced to one-third the time of conventional orthodontics. Authors have suggested that corticision and piezocision are some of the minimally invasive procedure.^{9,10}

In present study we compared piezocisionbased flapless corticotomy in class I and class II patients with the conventional method. In current study patients were divided in two groups each 25 patients i.e. 50% in each group of the total selected sample. In current study we found that piezocision-assisted canine distalization decreased total treatment duration and anchorage loss in the molar region. In our study we found that the amount of distalization showed decreased duration of canine distalization. Similar result was reported by Aboul-Ela et al. and Sertac Aksakalli.^{11,12}

In present study the amount of canine distalization was greater in the piezocision group than as compared to control group. Anchorage loss for the first molars was comparatively less whereas statistically significant (p<0.01) difference was observed in the canine distalization in the study group as compared to control group. The pre- and postdistalization mobility scores were not found significantly different between the groups in present study. Wilcko WM et al showed similar result in their

study. Omar Gibreal et al in their study reported that OAT was reduced by 59% in the experimental group compared to the control group, with a statistically significant difference between the two groups (P < 0.001).¹³

CONCLUSION:

Within the limits of our study we conclude that flapless piezocision technique was very effective in accelerating orthodontic tooth movement. It can be safely used as alternative method for orthodontic treatment.

REFERENCES:

1. Pilon JJ, Kuijpers-Jagtman AM, Maltha JC. Magnitude of orthodontic forces and rate of bodily tooth movement: an experimental study. *Am J Orthod Dentofacial Orthop.* 1996;110:16–23.
2. Roblee RD, Bolding SL, Landers JM. Surgically facilitated orthodontic therapy: a new tool for optimal interdisciplinary results. *CompendContinEduc Dent.* 2009; 30: 264-275. Ref.: <https://goo.gl/8wr1V5>
3. Dibart S, Sebaoun JD, Surmenian J. Piezocision: a minimally invasive, periodontally accelerated orthodontic tooth movement procedure. *CompendContinEduc Dent.* 2009; 30: 342-344, 346, 348- 350. Ref.: <https://goo.gl/dFyffb>.
4. Frost HM. The biology of fracture healing: An overview for clinicians. Part I. *ClinOrthopRelat Res.* 1989; 248: 283-293. Ref.: <https://goo.gl/FEFkAb>.
5. Frost HM. The biology of fracture healing: An overview for clinicians. Part II. *ClinOrthopRelat Res* 1989; 248: 294-309. Ref.: <https://goo.gl/Jc2t8y>.
6. Wilcko MW, Wilcko T, Bouquot JE, Ferguson DJ. Rapid orthodontics with alveolar reshaping: two case reports of decrowding. *Int J Periodontics Restorative Dent.* 2001; 21: 9-19. Ref.: <https://goo.gl/5HnJsE>.
7. Lee, W.; Karapetyan, G.; Moats, R.; Yamashita, D. D.; Moon, H. B.; Ferguson, D. J. & Yen, S. Corticotomy-

- /osteotomyassisted tooth movement microCTs differ. *J. Dent. Res.*, 87:861-7, 2008.
8. Ferguson, D. J.; Wilcko, W. M. & Wilcko, T. M. Accelerating orthodontics by altering alveolar bone density. *Good Practice*, 2:2-4, 2001.
 9. Kim SJ, Park YG, Kang SG. Effects of Corticision on paradental remodeling in orthodontic tooth movement. *Angle Orthod.* 2009;79:284-91.
 10. Dibart S, Sebaoun JD, Surmenian J. Piezocision: a minimally invasive, periodontally accelerated orthodontic tooth movement procedure. *CompendContinEduc Dent.* 2009;30:342-4. 346, 348-50.
 11. SertacAksakalli, Berra Calik, Burcak Kara, and SerefEzirganli (2016) Accelerated tooth movement with piezocision and its periodontal-transversal effects in patients with Class II malocclusion. *The Angle Orthodontist*: January 2016, Vol. 86, No. 1, pp. 59-65.
 12. Aboul-Ela SM, El-Beialy AR, El-Sayed KM, Selim EM, El-Mangoury NH, Mostafa YA. Miniscrew implant-supported maxillary canine retraction with and without corticotomy-facilitated orthodontics. *Am J Orthod Dentofacial Orthop.* 2011;139:252-259.
 13. Gibreal O¹, Hajeer MY², Brad B³. Efficacy of piezocision-based flapless corticotomy in the orthodontic correction of severely crowded lower anterior teeth: a randomized controlled trial. *Eur J Orthod.* 2019 Mar 29;41(2):188-195.
 14. Wilcko WM, Wilcko T, Bouquot JE, Ferguson DJ. Rapid orthodontics with alveolar reshaping: two case reports of decrowding. *Int J Periodontics Restorative Dent.* 2001;21:9-19.