

Original Research

Usefulness of USG in detection of gall bladder disorders

Dr. Navdeep Hooda

Assistant Professor, Department of Radiodiagnosis, Career Institute of Medical Sciences and Hospital, Lucknow, Uttar Pradesh, India

ABSTRACT:

Background: Cholecystitis is a common disorder and is usually asymptomatic. The present study assessed usefulness of USG in detection of gall bladder disorders. **Materials & Methods:** 102 cases of gall bladder disorders underwent abdominal ultrasonography. The procedure was done using different types of ultrasound units with 3.5 MHz and 5 MHz curve linear probes. **Results:** Out of 102 cases, males were 62 and females were 40. Serum bilirubin ($\mu\text{mol/L}$) was 130.4, alkaline phosphates (U/L) was 380.2, serum AST (U/L) was 74.2 and serum ALT (U/L) was 80.4. Common USG findings was wall thickening was seen in 85%, slight contraction in 52%, acute acalculous cholecystitis in 12% and pericholecystic edema in 20%. The difference was significant ($P < 0.05$). **Conclusion:** Common USG findings were wall thickening, slight contraction, acute acalculous cholecystitis and pericholecystic edema.

Key words: Alkaline phosphates, Gall bladder, USG.

Received: 15 June, 2018

Accepted: 9 August 2018

Corresponding author: Dr. Navdeep Hooda, Assistant Professor, Department of Radiodiagnosis, Career Institute of Medical Sciences and Hospital, Lucknow, Uttar Pradesh, India

This article may be cited as: Hooda N. Usefulness of USG in detection of gall bladder disorders. J Adv Med Dent Sci Res 2018;6(10):164-166.

INTRODUCTION

Pain in abdominal may be due to abnormalities in gall bladder, kidneys, pancreas, stomach, duodenum, spleen etc. Cholecystitis is a common disorder and is usually asymptomatic. Patients may show biliary colic, and often severe pain in the epigastrium or right upper quadrant, and sometimes between the scapula due to temporary obstruction of the cystic duct with a gallstone.¹

In cases of symptomatic gallstones and a negative ultrasound examination, endoscopic ultrasound is preferred. Papillomas, adenomyomas, or cholesterol polyps are benign tumors of gall bladder. Whereas malignant tumors are uncommon, cholecystectomy for patients with polyps larger than 10 mm seems warranted. If gall-bladder is not detected.²

Diagnostic ultrasound is a non-invasive technique which uses high frequency sound waves to produce tomographic images of internal body structures. It has wide application in many fields of medicine and is a valuable diagnostic technique. Ultrasonography has become the diagnostic test of choice for detecting gallstones and other diseases of the biliary system.³

Sonography of the gallbladder is performed with a handheld probe placed against the patient's skin in the right upper quadrant of the abdomen.⁴ Views are also obtained with the transducer in the region of the right anterior axillary line in a subcostal or low intercostal position. Small crystals within this probe generate short, rapid, high frequency pulses (three to five million cycles per second) which penetrate the patient's abdomen.⁵ The present study assessed usefulness of USG in detection of gall bladder disorders.

MATERIALS & METHODS

The present study comprised of 102 cases of gall bladder disorders of both genders. All selected patients were made aware of the study and their written consent was obtained.

Data such as name, age, gender etc. was recorded. All underwent abdominal ultrasonography. The procedure was done using different types of ultrasound units with 3.5 MHz and 5 MHz curve linear probes. Results thus obtained were tabulated and subjected to statistical analysis using chi square test. P value < 0.05 was considered significant.

RESULTS

Table I Distribution of cases

Total- 102		
Gender	Males	Females
Number	62	40

Table I shows that out of 102 cases, males were 62 and females were 40.

Table II Assessment of clinical features

Clinical features	Number	P value
Upper abdominal pain	82	0.01
Nausea /Vomiting	55	
Jaundice	71	
Upper abdominal mass	5	
Weight loss	9	
Itching	12	

Table II, graph I shows that common clinical features were upper abdominal pain in 82, nausea /vomiting in 55, jaundice in 71, upper abdominal mass in 5, weight loss in 9 and itching in 12 patients. The difference was significant (P< 0.05).

Graph I Assessment of clinical features

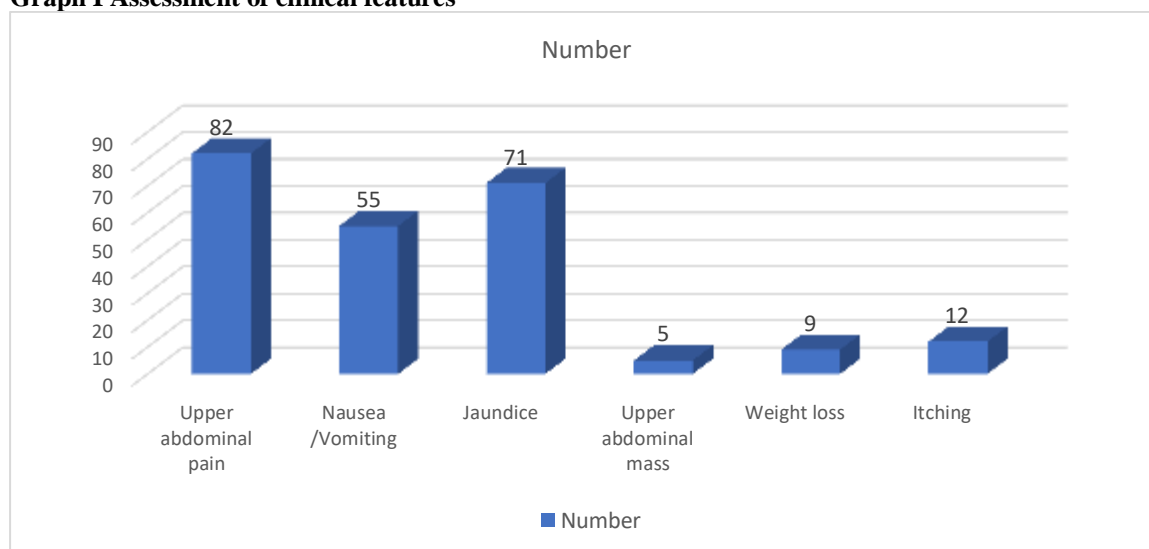


Table III Biochemical parameters

Parameters	Mean	SD
Serum bilirubin (µmol/L)	130.4	12.5
Alkaline phosphates (U/L)	380.2	114.5
Serum AST (U/L)	74.2	14.7
Serum ALT (U/L)	80.4	10.2

Table III shows that serum bilirubin (µmol/L) was 130.4, alkaline phosphates (U/L) was 380.2, serum AST (U/L) was 74.2 and serum ALT (U/L) was 80.4.

Table IV Other abnormalities detected on ultrasonography

Findings	Percentage	P value
Wall thickening	85%	0.04
Slight contraction	52%	
Acute acalculouscholecystitis	12%	
Pericholecystic edema	20%	

Table IV shows that common USG findings were wall thickening was seen in 85%, slight contraction in 52%, acute acalculouscholecystitis in 12% and pericholecystic edema in 20%. The difference was significant (P< 0.05).

DISCUSSION

Different diagnostic modalities are available for the diagnosis of gall bladder disorders. Among all, ultrasound is preferred one. It does not cause any radiation damage to patient as x rays are not used in this technique.⁶ Ultrasound is non-invasive and is not painful. Ultrasound is effective in diagnosis of cholelithiasis, pericholecystic fluid and a thickened wall of gallbladder.⁷ Ultrasound produces good images of the small ducts in the liver and the higher part of the major bile duct.⁸ A sonogram of a normal gallbladder shows the common bile duct anterior to the right portal vein and right hepatic artery. Connective tissue around the neck of the gallbladder and cystic duct areas can produce dense echoes with distal shadowing.⁹ Inexperienced ultrasound operators may mistake this shadowing for stones in the neck of the gallbladder or common bile duct. The gallbladder wall's normal thickness is up to 3 mm and produces a thin linear echo. Wall thickening from chronic inflammation or edema can be detected by ultrasound.¹⁰ The present study assessed usefulness of USG in detection of gall bladder disorders.

In present study, out of 102 cases, males were 62 and females were 40. We found that common clinical features were upper abdominal pain in 82, nausea/vomiting in 55, jaundice in 71, upper abdominal mass in 5, weight loss in 9 and itching in 12 patients. Gupta et al¹¹ found that out of 120 patients, 70 were males and 50 were females. Age group 11-20 years consisted of males (4) and females (8). Age group 21-30 years consisted of males (11) and females (9). Age group 31-40 years consisted of males (17) and females (10). Age group 41-50 years consisted of males (13) and females (8). Age group 51-60 years consisted of males (15) and females (7). Patients > 60 years consisted of males (10) and females (8). The difference was non-significant ($P > 0.05$). Out of 120 patients, 35 were diagnosed with cholelithiasis. The prevalence was 29.1%. Out of 35 patients diagnosed with cholelithiasis, males were 20 and females were 15. Other abnormalities were wall thickening (27), slightly contraction (12), enlarge gall bladder with mass (10), acute acalculous cholecystitis (14), hepatic cyst (4) and pericholecystic edema (18).

We observed that serum bilirubin ($\mu\text{mol/L}$) was 130.4, alkaline phosphates (U/L) was 380.2, serum AST (U/L) was 74.2 and serum ALT (U/L) was 80.4. We found that common USG findings were wall thickening was seen in 85%, slight contraction in 52%, acute acalculous cholecystitis in 12% and pericholecystic edema in 20%. Ghafoor et al¹² in their study the diagnostic accuracies of USG and CT scan were then compared against histopathological diagnoses. In the present study, the mean age of the patients was 60 (range: 40-80) years with female preponderance. About 40% of the gall-bladder were contracted and reduced in size and 32.5% large and distended on USG examination, while 45% of the gall-bladder were contracted and reduced in size and

25% distended and large on CT examination. Approximately 40% had irregularly thickened wall and 21.2% diffusely thickened wall on USG and 30% of gallbladder wall were diffusely thickened and 45% irregularly thickened on CT scan. The present study showed hepatic parenchymal invasion to be 22.5% on USG and 42.5% on CT scan. The sensitivity and specificity of USG in diagnosing GB carcinoma were 93.9 and 71.4% respectively. Similarly, the sensitivity and specificity of CT scan in detecting GB carcinoma were 97.1 and 83.3% respectively. The test of agreement (Kappa test) revealed an almost 90% agreement between the two procedures meaning that the two diagnostic modalities are almost comparable in diagnosing gall bladder carcinoma ($p < 0.001$).

CONCLUSION

Authors found that common USG findings were wall thickening, slight contraction, acute acalculous cholecystitis and pericholecystic edema.

REFERENCES

1. Haaga JR, Lanzieri CF, Gilkeson RC. CT and MRI Imaging of the whole body, 4th ed, Mosby: Missouri; 2003;1318-41.
2. Mondy MM, Chang MC, Bowton DL, Kilgo PD, Meredith JW, Miller PR. Prospective comparison of bronchoalveolar lavage and quantitative deep tracheal aspirate in the diagnosis of ventilator-associated pneumonia. *J Trauma* 2005; 59: 891-6.
3. Memon MA, Anwar S, Shiwani MH, Memon B. Gallbladder carcinoma: a retrospective analysis of twenty-two years experience of a single teaching hospital. *International Seminars in Surg Oncol* 2005; 6(2): 79-81.
4. Paraskevopoulos JA, Baer H, Uttigea F, Dennison AR. The role of imaging techniques in the diagnosis of primary carcinoma of the gallbladder. *Br J Surg* 1994; 81(1):15.
5. Yeh H. Ultrasonography and computed tomography of carcinoma of the gallbladder. *Radio* 1979; 133: 167-73.
6. Levy AD, Murakata LA, Rohrmann CA. Gallbladder carcinoma: radiologic-pathologic correlation. *Radiographics* 2001; 21(2): 295-314.
7. Chianakwana GU, Okafor PIS, Anyanwu SNC. Carcinoma of the gallbladder at the Nnamdi Azikiwe University teaching hospital: a 5-year retrospective study. *Nigerian J Clinical Pract* 2005; 8(1): 10-13.
8. Bach AM, Loring LA, Hann LE, Illescas FF, Fong Y, Blumgart LH. Gallbladder cancer: can ultrasonography evaluate extent of disease? *J Ultrasound Med* 1998; 17(5):303-9.
9. Courtney M. Townsend Jr. Sabiston Textbook of Surgery: The biological basis of modern surgical practice (textbook of surgery), 17th ed, WB Saunders 2004.
10. Kumaran V, Gulati S, Paul B, Pande K, Sahni P, Chattopadhyay K. The role of dual-phase helical CT in assessing resectability of carcinoma of the gallbladder. *Eur Radiol* 2002; 12(8):1993-9.
11. Gupta S, Jain AK. Ultrasonography as an imaging technique for the diagnosis of gall bladder disorders: A clinical study. *J Adv Med Dent Sci Res* 2017; 5(1):79-82.
12. Ghafoor N, Abedin N, Mohiuddin AS. Role of ultrasound and computed tomography in the evaluation of gallbladder malignancy. *Anwer Khan Modern Medical College Journal*. 2017 Aug 23; 8(2):105-11.