

ORIGINAL ARTICLE

A comparative study of primary repair versus loop ileostomy in cases of ileal perforation

Dr. Arun Kumar Pandey¹, Dr. Vibhuti Kumar Shrivastav²

¹MBBS, MS (General Surgery), Chief Medical officer, District- Baharaich, Uttar Pradesh, India;

²Senior Consultant, Anesthesiology, CIVIL Hospital Lucknow, Uttar Pradesh, India

ABSTRACT:

Background: The present study was conducted to compare primary repair versus loop ileostomy in cases of ileal perforation.

Materials & Methods: 64 confirmed cases of ileal perforation of both genders were involved. Group I patients were managed with primary repair and group II with loop ileostomy. Each group had 32 patients. **Results:** Common clinical features was fever seen in 25 in group I and 28 in group II, pain abdomen 27 in group I and 38 in group II, vomiting 12 in group I and 18 in group II, trauma 10 in group I and 12 in group II and constipation 9 in group I and 7 in group II. Common complications was wound infection 5 in group I and 2 in group II, wound dehiscence 4 in group I and 1 in group II, intra- abdominal collections 3 in group I and 0 in group II and anastomotic leak 2 in group I and 1 in group II. **Conclusion:** Loop ileostomy was preferred over primary repair in management of cases of ileal perforation.

Key words: Loop ileostomy, Ileal perforation, Dehiscence

Corresponding Author: Dr. Arun Kumar Pandey, MBBS, MS (General Surgery), Chief Medical officer, District- Baharaich, Uttar Pradesh, India

This article may be cited as: Pandey AK, Shrivastav VK. A comparative study of primary repair versus loop ileostomy in cases of ileal perforation. J Adv Med Dent Scie Res 2017;5(11):149-152.

INTRODUCTION

Gastrointestinal perforations have been surgical problem since the time immortal. Scientists have found evidence of gastrointestinal perforations in Egyptian mummies. Perforation is said to occur once a pathology which extends through the full thickness of the hollow viscus leading to peritoneal contamination with intraluminal contents. Perforation can occur anywhere in the gastrointestinal tract starting from oesophagus to the rectum.¹

Hollow viscus perforation leading to peritonitis is one of the commonest emergency surgeries conducted in a surgical practice for a case of acute abdomen. It is the second most common cause for acute abdomen following appendicitis. Perforation as a cause of acute abdomen accounts for 30-40% of the total cases of acute abdomen presenting to a surgical emergency. Among the cases of hollow viscus perforation duodenal and gastric perforations are the commonest accounting to almost 60- 80 % in some series, followed by ileal, appendicular and large bowel.²

A "non-specific" etiology is attributed to small bowel perforations when the perforation cannot be classified on the basis of clinical symptoms, gross examination, serology, culture and histopathological examination into any disease state such as enteric fever, tuberculosis or malignancy.³ These ulcers are usually single and commonly involve terminal ileum. It has been proposed that submucosa vascular embolism, chronic ischemia due

to atheromatous vascular disease or arteritis or drugs such as enteric coated potassium tablets are responsible for them.⁴

Various operative procedures were advocated by different authors, such as the following simple primary repair of perforation, repair of perforation with ileotransverse colostomy, primary ileostomy, single layer repair with an omental patch, resection and anastomosis.⁵ The present study was conducted to compare primary repair versus loop ileostomy in cases of ileal perforation.

MATERIALS & METHODS

The present study was conducted on 64 confirmed cases of ileal perforation of both genders. The enrollment of patients was done after they agreed to participate in the study and after obtaining ethical clearance.

Patients profile such as name, age, gender etc. was recorded. Patients were divided into 2 groups group I and group II. In group I, the surgical management was done as primary repair and in group II, loop ileostomy was done. In group I, primary closure was done in two layers, the inner layer closed with 3-0 poly glycolic acid (vicryl) and outer layer closed with silk 3-0. In group B loop ileostomy was done. Postoperative complications in both groups were evaluated. Results were subjected to statistical analysis. P value less than 0.05 was considered significant.

RESULTS:

Table I Distribution of patients

Groups	Group I	Group II
Procedure	Primary repair	Loop ileostomy
Number	32	32

Table I shows that group I patients was managed with primary repair and group II with loop ileostomy. Each group had 32 patients.

Table II Clinical profile in both groups

Clinical profile	Group I	Group II	P value
Fever	25	28	0.82
Pain abdomen	27	38	0.05
Vomiting	12	18	0.07
Trauma	10	12	0.91
Constipation	9	7	0.92

Table II, graph I shows that common clinical features was fever seen in 25 in group I and 28 in group II, pain abdomen 27 in group I and 38 in group II, vomiting 12 in group I and 18 in group II, trauma 10 in group I and 12 in group II and constipation 9 in group I and 7 in group II. The difference was non- significant (P> 0.05).

Graph I Clinical profile in both groups

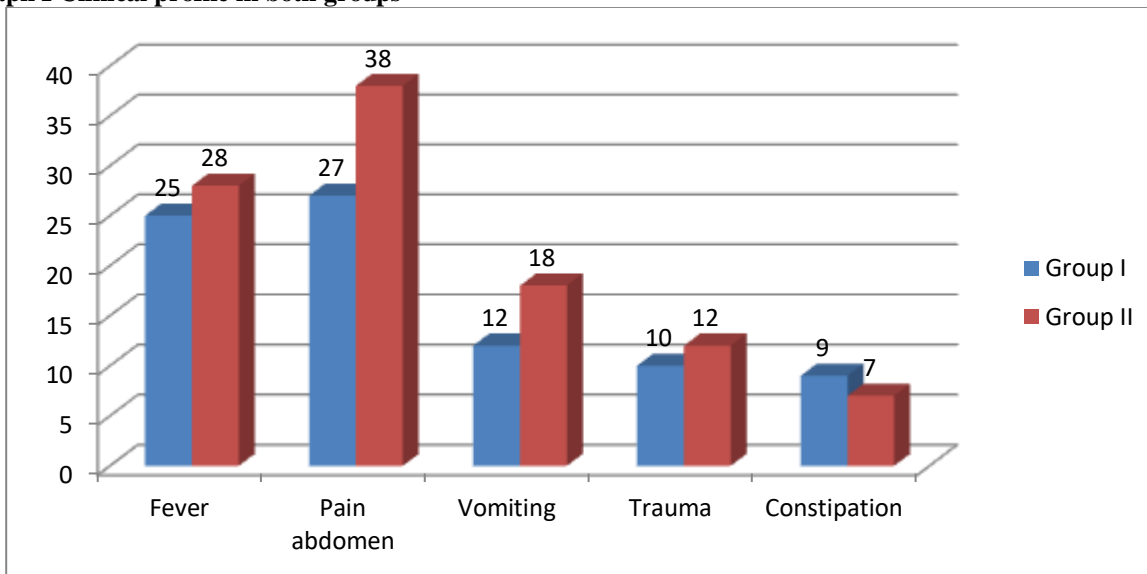
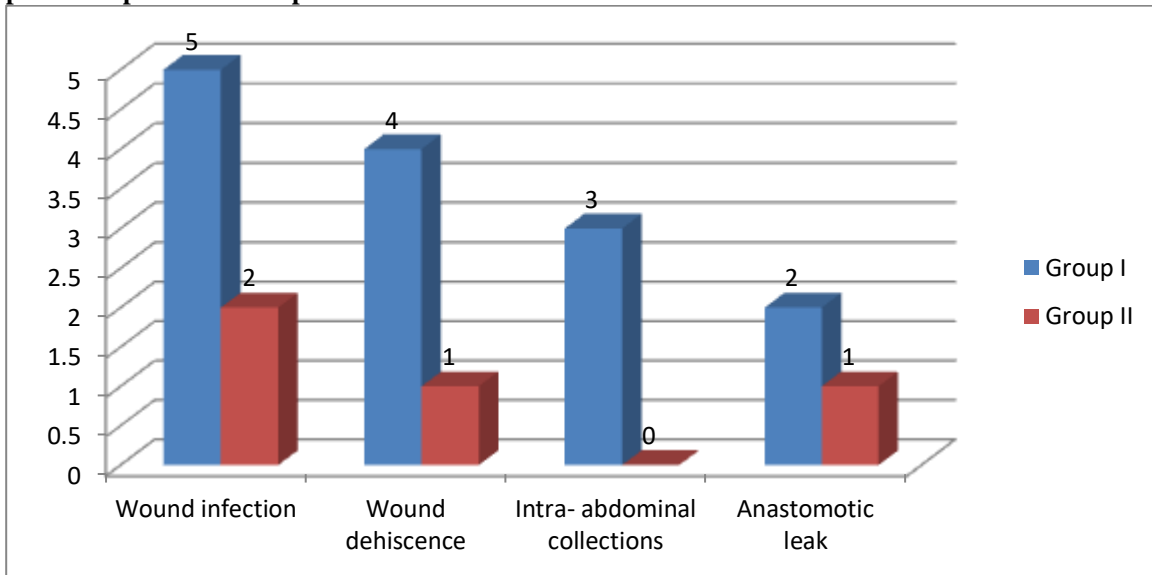


Table III Comparison of complications

Complications	Group I	Group II	P value
Wound infection	5	2	0.02
Wound dehiscence	4	1	0.03
Intra- abdominal collections	3	0	0.05
Anastomotic leak	2	1	0.09

Table III, graph II shows that common complications was wound infection 5 in group I and 2 in group II, wound dehiscence 4 in group I and 1 in group II, intra- abdominal collections 3 in group I and 0 in group II and anastomotic leak 2 in group I and 1 in group II. The difference was significant (P< 0.05).

Graph II Comparison of complications



DISCUSSION

The incidence of perforation is on the rise due to the increased prevalence of gastritis in the population and also due to the increased use of over the counter NSAIDs which abolish the gastro-protective effects of prostaglandins.⁶ The incidence of Ileal perforation is also increasing mainly due to increased number of people presenting to the emergency department and also due to better diagnosis and improved reporting of cases.⁷ Ileal perforations account for about 20 % of all cases of hollow viscus perforation. Among the causes for Ileal perforations, typhoid Ileal perforations are the commonest followed by tubercular and other etiologies.⁸

Various causes of nontraumatic ileal perforation include bacterial infections (salmonella, yersinia, and tuberculosis), viral infections (cytomegalovirus, human immunodeficiency virus), fungal infection (histoplasma), parasitic infections (A. lumbricoides, E. vermicularis, and E. histolytica), and others (Wagener’s granulomatous and drugs).⁹ In a significant number of cases the cause of perforation is not known and it is called nonspecific ileal perforation. The perforation causes gram-negative aerobic and anaerobic infection leading to peritonitis.¹⁰ The present study was conducted to compare primary repair versus loop ileostomy in cases of ileal perforation.

In this study, group I patients was managed with primary repair and group II with loop ileostomy. Each group had 32 patients. Vaidya et al¹¹ in their study sixty proven cases of ileal perforation patients admitted to Surgical Emergency were taken up for emergency surgery. Randomization was done by senior surgeons by picking up card from both the groups. The surgical management was done as primary repair (group A) and

loop ileostomy (group B). An increased rate of postoperative complications was seen in group A when compared with group B with 6 (20%) patients landed up in peritonitis secondary to leakage from primary repair requiring reoperation as compared to 2 (6.67%) in ileostomy closure. A ratio of 1: 1.51 days was observed between hospital stay of group A to group B.

We found that common clinical features was fever seen in 25 in group I and 28 in group II, pain abdomen 27 in group I and 38 in group II, vomiting 12 in group I and 18 in group II, trauma 10 in group I and 12 in group II and constipation 9 in group I and 7 in group II. Poornima et al¹² in their study a total of 136 patients presented in this period with hollow viscus perforation and out of these 64 patients had Ileal perforation alone on exploratory laparotomy. Ileal perforations account for about 20 percent of all cases of hollow viscus perforation. Emergency exploratory laparotomy was done and perforation was identified, edge biopsy was taken in all cases and the perforation was closed in two layers and resection anastomosis was done in stricture with perforation. Histopathological report was reviewed following surgery. A total of 64 patients with Ileal perforation were included in the study of which 52 were males and 12 were females accounting for 81.25 percent and 18.75 percent respectively. The causes for perforation were enteric fever (82.81%), nonspecific inflammation (9.38%), and tuberculosis (7.81%). Simple closure of the perforation (74.58%) and the remaining primary resection and anastomosis were the mainstay of the surgical management. The common pathology of Ileal perforation is Typhoid or Enteric fever, Non-specific ulcer, Tuberculosis and others. Intestinal complications of typhoid fever are quite common in developing countries. Nonspecific inflammation of the terminal ileum was other

predominant cause operative findings were similar to that of typhoid fever but no laboratory evidence of the disease was found. Intestinal tuberculosis can mimic many conditions.

In this study we observed that common complications was wound infection 5 in group I and 2 in group II, wound dehiscence 4 in group I and 1 in group II, intra-abdominal collections 3 in group I and 0 in group II and anastomotic leak 2 in group I and 1 in group II. The shortcoming of the study is small sample size.

CONCLUSION

Authors found that loop ileostomy was preferred over primary repair in management of cases of ileal perforation.

REFERENCES

1. Abdullah MS, Rassam RE, Almarzooq TJ. A study of 82 patients of non-traumatic terminal Ileal perforation in al-kindy teaching hospital. *J Fac Med Baghdad*. 2011;53(2):148.
2. Khalid S, Burhanulhuq, Bhatti A. Non-traumatic spontaneous Ileal perforation: experience with 125 cases. *J Ayub Med Coll Abbottabad*. 2014;26(4).
3. Nuhu A, Dahw S, Hamza A. Operative management of typhoid Ileal perforation in children. *African J Pediatr Surg*. 2010;7(1):9-13.
4. Mogasale V, Desai SN, Mogasale VV, Park JK, Ochiai RL, Wierzba TF. Case fatality rate and length of hospital stay among patients with typhoid intestinal perforation in developing countries: a systematic literature review. *PLOS ONE*. 2014;9(4):e93784.
5. Hosoglu S, Aldemir M, Akalin S, Geyik MF, Tacyildiz IH, Loeb M. Risk factors for enteric perforation in patients with typhoid fever. *Am J Epidemiol*. 2004;160:46-50.
6. Mukhopadhyay A, Dey R, Bhattacharya U. Abdominal tuberculosis with an acute abdomen: our clinical experience journal of clinical and diagnostic research. *J Clin Diagnost Res*. 2014;8(7):NC07- NC09.
7. Chan D, Lee KC. Perforated intestinal tuberculosis in a non-AIDS immunocompromised patient. *Am J Case Rep*. 2012;16:719-22.
8. Hatzaras I, Palesty JA, Abir F, Sullivan P, Kozol RA, Dudrick SJ, et al. Small-bowel tumors: epidemiologic and clinical characteristics of 1260 cases from the connecticut tumor registry. *Arch Surg*. 2007;142:229-35.
9. Kouame J, Kouadio L, Turquin HT. Typhoid Ileal perforation surgical experience of 64 cases. *Acta Chir Belg*. 2004;104:445-7.
10. Steven T. Prognostic factors in typhoid heal perforation: A prospective study of 53 cases. *Journal of the National Medical Association*. 2007;99:9.
11. Vaidya R, Habermann TM, Donohue JH. Bowel perforation in intestinal lymphoma: incidence and clinical features. *Ann Oncol*. 2013;24:2439-43
12. Poornima R, Venkatesh KL, Goutham MV, Nirmala, Hassan N. Clinicopathological study of Ileal perforation: study in tertiary center. *Int Surg J* 2014;4:543-9.