

## Original Research

### Evaluation of inferior alveolar canal and its variations using Cone-beam CT-scan

Vikash Sharma, Abhilasha Yadav, Shirish Dubey, Anuj Thakur, Khalid Abdul Hafiz, Rajib Rudra Paul

Dept of Oral and Maxillofacial surgery, Awadh dental college, Jamshedpur, India

#### ABSTRACT

**Background:** The knowledge of the precise location of anatomical landmarks such as mandibular foramen, Inferior alveolar canal (IAC), mental foramen and the course of the inferior alveolar neurovascular bundle is mandatory to obtain the desired outcome of different mandibular surgical procedures and overcome various surgical complications.

**Objective:** To document a clinically relevant position of the Inferior alveolar nerve (IAN) in completely dentate patients, to identify the linear relationship of the Inferior alveolar canal (IAC) to the buccal and lingual cortex (BCP/LCP) of the mandible and to the peri-apex of the teeth as well as to assess the presence and course of the anterior loop in the mental foramen region according to the gender and side, using Cone Beam Computerised Tomography (CBCT). **Material and Methods:** This cross-sectional study utilized 378 Cone Beam Computerised Tomography (CBCT) images from 232 patients (one patient may have images of both side of mandible which are counted as two separate images) to obtain quantifiable data to localize the IAC. Measurements to the IAC were made from the BCP & LCP and the root apices of the mandibular pre molars and molars. **Results:** In 15 subjects, 18 accessory mental foramina (AMF) were detected. Anterior loop in the mental region was detected in 91% of the scans. The IAC was noted to be closest to the buccal cortical plate in the region of premolars on both sides. The distance between the lingual outer cortex to outer surface of the IAC along lingual side, distance between buccal outer cortex to outer surface of the IAC along buccal side, distance between the peri-apex to the superior surface of IAC were recorded to assess accurately the position of the IAN within the IAC. **Conclusion:** With increasing demand for accurate preoperative assessment and planning prior to surgeries of this region, cross-sectional images such as from CBCT may be utilized for obtaining more information on the appearance, location and course of the IAC, and its relation to other anatomical structures in the jaw bone including the apex of the tooth.

**Key words:** Cone beam computed tomography, Inferior alveolar canal, Inferior alveolar nerve, mental foramen, accessory mental foramina.

Received: 14 July, 2018

Revised: 16 August, 2019

Accepted: 18 August, 2019

**Corresponding Author:** Dr. Vikash Sharma, Dept of Oral and Maxillofacial surgery, Awadh Dental College, Jamshedpur, India.

**This article may be cited as:** Sharma V, Yadav A, Dubey S, Thakur A, Hafiz KA, Paul RR. Evaluation of inferior alveolar canal and its variations using Cone-beam CT-scan. J Adv Med Dent Scie Res 2019;7(9):153-160.

#### INTRODUCTION:

The inferior alveolar neurovascular bundle containing the inferior alveolar nerve (IAN) is located in the IAC of the lower jaw and leaves the canal from the mental foramen in the anterior wall of the premolar region of the alveolar bone. The IAN forms the anterior loop of the mandibular canal in the anterior region of the mental foramen and splits into two nerve branches: mental and incisive [1].

The considerable variation in the course, the shape, curve, and direction of the nerve as well as the terminal

segment of IAN complicates the regional anatomy. Hence, it is often difficult to predict the exact position of the nerve, thus impeding a proper pre-operative planning [2]. The knowledge of the precise location of the above anatomical landmarks such as mandibular foramen, IAC and mental foramen and the course of mandibular neurovascular bundle is mandatory to obtain the desired outcome of different mandibular surgical procedure and overcome various surgical complications [3].

Risk of inadvertent IAN injury is associated with various surgical interventions in the area including sagittal split osteotomies, dental implant insertion, bone grafting or placement of fixation screws. It has been reported that IAN damage may cause sensory deficits up to 8.3% to 77.8% depending on the type of surgery [4].

The evaluations of accessory mental foramen (AMF) are also clinically important as they may reduce the rates of haemorrhage, post-operative pain and paraesthesia risk in surgical procedures [5].

Previous attempts to describe the IAN anatomy have significant limitations. Cadaver findings cannot be translated to patient population owing to differences in age or disease. Skull based studies lack demographic data or use clinically inconsistent and anatomically irrelevant landmarks or include edentulous mandibles [4].

Use of two dimensional imaging modalities and computed tomograms has their own limitations. Conventional radiographs have limited reproducibility, magnifications and distortion and only represent a two dimensional position of the canal [6].

Cone beam computed tomography is a new accurate modality of 3D reconstruction of the imaging of the dental and maxillofacial structure without any superimposition or magnification. It produces high resolution, artefact-free, non-magnified and undistorted 3D images of the maxillofacial anatomy that can be reformatted in any desired plane for interactive viewing and image manipulation. The radiation dose is significantly less than that of conventional medical grade CT Scans [7].

All of the above reasons make this study extremely clinically significant.

Thus, the aim of this study was to document the clinically relevant position of the IAN in completely dentate patients- normal variations of mandibular and mental foramen, IAC and AMF position and to identify the linear relationship of canal to buccal and lingual cortex and to the periapex of the molar teeth as well as to assess presence and course of the anterior loop in the mental foramen lesion according to the gender and using the CBCT.

#### **MATERIALS AND METHODS:**

This cross-sectional study was conducted on 378 CBCT images - the data collected from a private CBCT centre in Ahmedabad. All the CBCTs were taken by same trained personnel in the same machine (Newtom Giano), at the same settings. The said data was then analysed in the Dept of Anatomy at Dr MK Shah Medical College and Research Centre, Ahmedabad, with the help of the Dept of Maxillofacial Surgery, Govt Dental College & Hospital, Ahmedabad.

Using the axial, coronal and sagittal sections, the exact location of the position of the IAC and AMF if present, was identified for the study. Linear measurements were made in cross-sections, as depicted in Fig. 1.

#### **INCLUSION CRITERIA:**

1. Patients with complete sets of teeth.
2. Absence of radiological evidence of skeletal/dental malocclusion that could have altered the position of mandibular molars and premolars or IAN.
3. Radiographically completely corticized IAN canal bilaterally.

#### **EXCLUSION CRITERIA:**

1. Patients with evidence of bone disease, relevant drug consumption, skeletal asymmetries or trauma, congenital disorders and pathological disorders of the mandible as well as syndromic patients or any previous surgery which could change the position of the mandibular canal.
2. Low quality images, e.g. ones that contained scattering or insufficient accuracy of bony borders.

The measurements were: (figure 1)

- Distance between the lingual outer cortex to outer surface of the IAC along lingual side.
- Distance between buccal outer cortex to outer surface of the IAC along buccal side.
- Distance between the peri-apex to the superior surface of IAC.

Also studied were:

- Presence or absence of anterior loop of mental nerve.
- Distance from medial margin of mental foramen to proximal edge of anterior loop.
- Presence or absence of AMF.
- Mean distance of AMF from mental foramen.

All the above parameters were calculated in males, females and right and left side and along the second premolar, first molar and second molar of the mandible.

#### **RESULTS:**

A total of 378 CBCT scans from 232 numbers of subjects were studied. In these subjects 110 were male and 122 were females, aged 15-64 years, with mean age of 31.6 years and 34 years. The number of right side mandible scans was 190 and left side was 188.

In 15 subjects, 18 AMF were detected, so its prevalence was 6.46%. 9 of these subjects were male with mean age of 34.6 years and 6 were females with mean age of 35.2 years. Bilateral AMF were present in 2 females and 1 male subject. Mean distance of AMF from Mental Foramen, gender wise and side wise is shown in Table 1. Significant differences were found in the anatomic variation of Mental Foramen regarding gender ( $P=0.046$ ) but not in case of side [left( $p=0.228$ ) and right side ( $p=0.191$ )].

Anterior loop in the mental region was detected in 91% (343) of the scans. Prevalence of anterior loop in females 188 out of 199 scans (94.47%) was found higher than found in males, 155 out of 179 (77.88%).

The mean length from the medial margin of the Mental Foramen to the proximal edge of the Anterior Loop ranged from 2.6 to 3.6 mm (mean 3.15 mm). Anterior loop on the right side was found in 174 out of 190 cases (91.6%) and on the left side in 171 out of 188 cases (89.9%). The prevalence of anterior loop regarding gender in the left and right side is presented in table 2. There were no significant difference in the prevalence of anterior loop regarding gender and both sides of the mandible ( $p=0.215$  &  $p=0.167$ ).

The IAC was noted to be closest to the buccal cortical plate in the region of the premolars on both sides with the mean distance of 2.83 mm [Table 5]. The canal courses toward the LCP (lingual cortical plate) and the inferior border of mandible (IBM) as it moves posterior toward the distal root of the second molars. Mean distance from the LCP to the canal at the level of the molars was 2.73 mm [Table.4].

The canal was also closest to the distal root of the second molar. The roots of the second molar were in direct contact with the IAC in 23.5% of the cases on the right side and 22.6% of the cases on the left side.

There was a statistically significant variance ( $P=0.042$ ) between gender wise comparison of the linear distance between the lingual outer cortex to the outer surface of the IAC along lingual side, distance between buccal outer cortex to outer surface of the canal along buccal side and the distance between the periapex to the superior surface of the canal, but side wise, no such statistically significant difference was found ( $p=0.122$ ). Measurements were recorded by two observers and repeated by interval of one week. Repeated evaluation and measurements indicated no significant intra-observer ( $p=0.142$ ) or inter-observer ( $p=0.138$ ) differences in their evaluations and measurements.

Table 1: Accessory Mental Foramen

Gender	Number of AMF	Mean age	Mean distance between MF and AMF on right side in mm	Mean distance between MF and AMF on left side in mm
Male	9	34.6	3.6 ± 1.2 mm	3.78 ± 0.9
Female	6	35.2	2.5 ± 0.9	2.4 3± 1

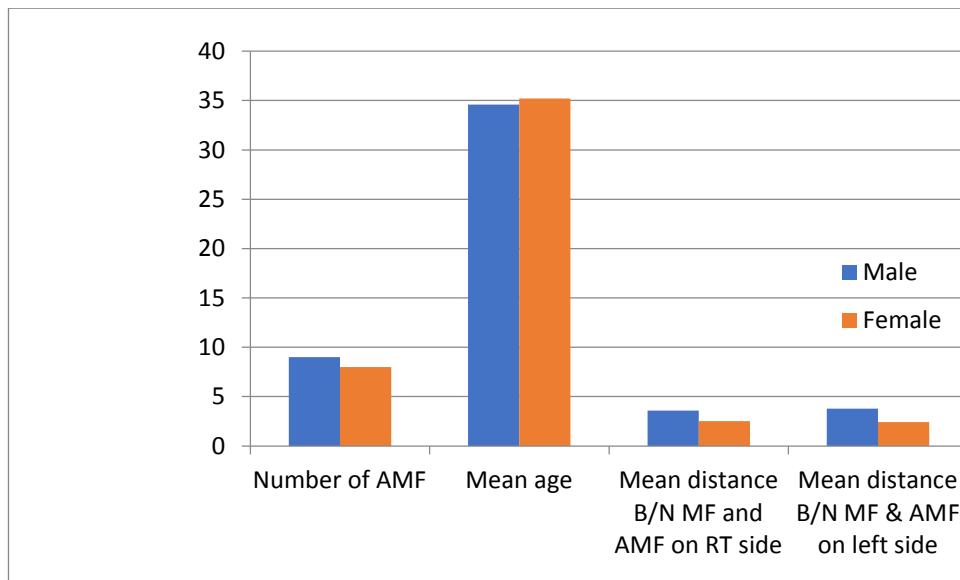


Table 2: Mean (in mm) Values of Distance from medial margin of mental foramen to proximal edge of anterior loop according to gender and side.

	Right		Left	
	Male	Female	Male	Female
Mean Length from the medial margin of the mental foramen to anterior loop	3.22	3.15	3.28	3.26

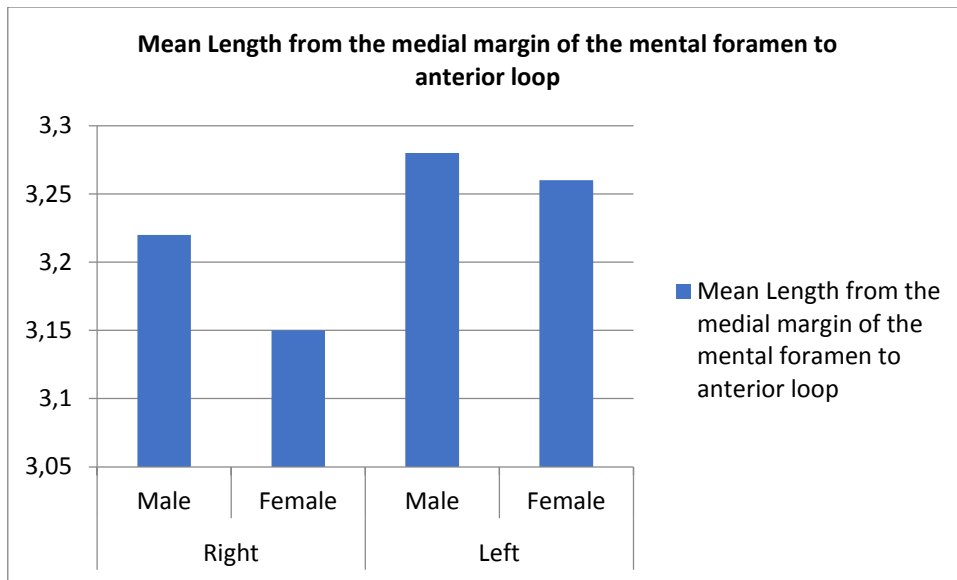


Table 3: Mean Distance (in mm) between buccal outer cortex to outer surface of the IAC along buccal side.

Region	Male (n=110)		Female (n=122)	
	Right	Left	Right	Left
2 <sup>nd</sup> Premolar	3.1	2.9	2.7	2.6
1 <sup>st</sup> Molar	5.2	5.57	4.85	4.94
2 <sup>nd</sup> Molar	5.64	6.02	4.93	5.03

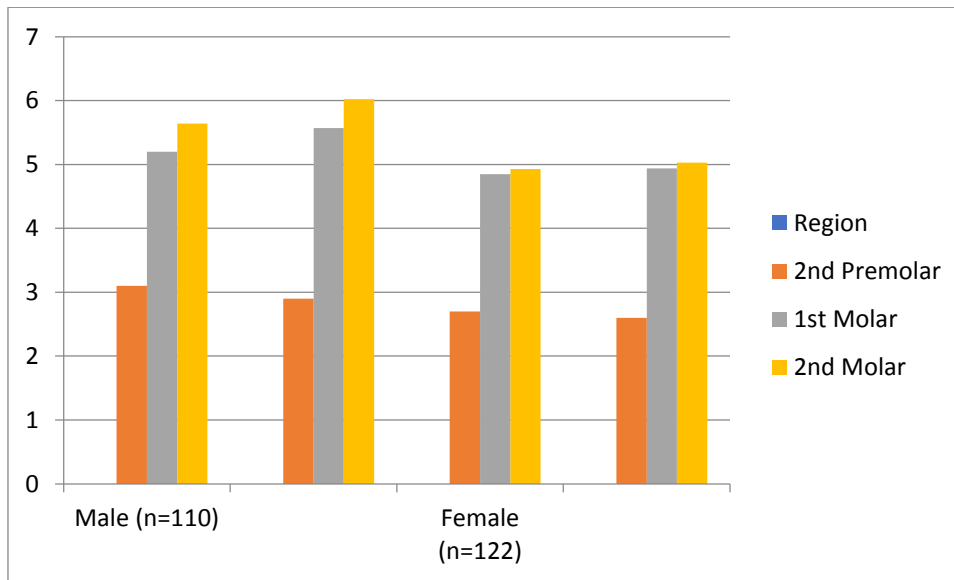


Table 4 Mean Distance (in mm) between the lingual outer cortex to outer surface of the IAC along lingual side.

Region	Male (n=110)		Female (n=122)	
	Right	Left	Right	Left
2 <sup>nd</sup> Premolar	4.3	4.5	3.9	3.7
1 <sup>st</sup> Molar	3.42	3.21	3.17	3.03
2 <sup>nd</sup> Molar	2.78	3.02	2.34	2.78

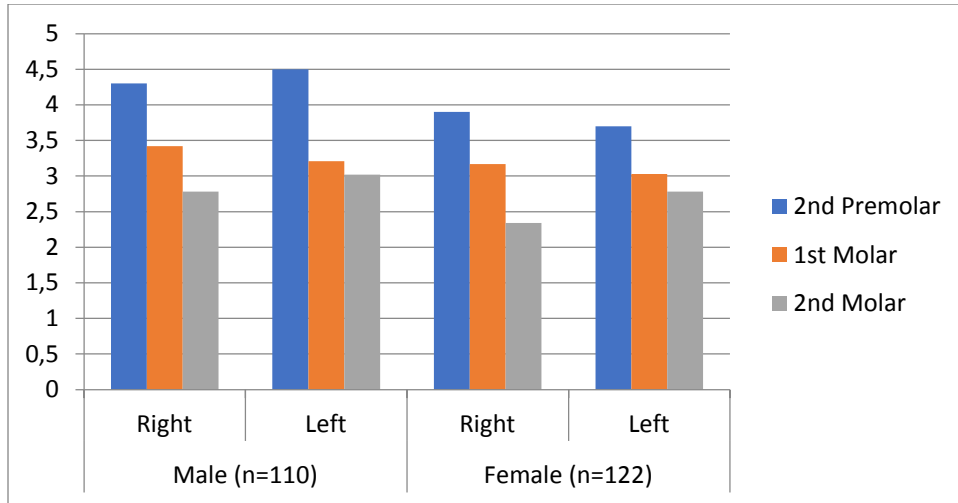


Table. 5: Mean Distance (in mm) between the peri-apex to the superior surface of IAC

Region	Male (n=110)		Female (n=122)	
	Right	Left	Right	Left
2 <sup>nd</sup> Premolar	5.9	5.8	5.65	5.5
1 <sup>st</sup> Molar	5.79	5.75	5.54	5.34
2 <sup>nd</sup> Molar	5.95	5.83	5.67	5.58

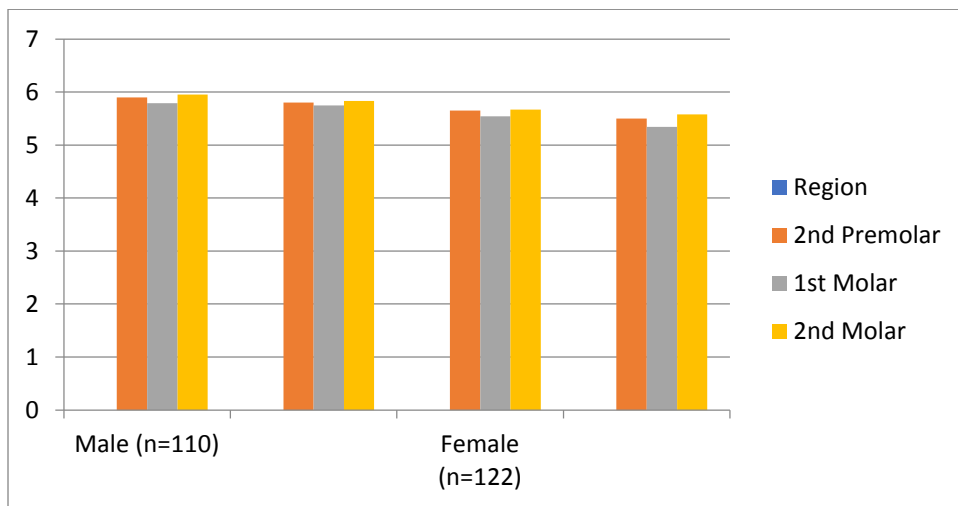


Table 6: Comparison between the findings of the present study and other similar studies.

Studies	Total Subjects	Subjects having accessory mental foramina	Percentage
Present	232	15	6.46%
Naitoh et al	365	37	10.13%
Katakami et al	150	17	11.33%
Munetaka N et al	157	11	7%
A. kalender et al	386	25	6.5%

Studies	Total subjects	Subjects having anterior loop	Percentage	Mean distance from mental foramen
Present	376	343	91%	3.15mm
HakanEren et al	328	282	86%	3.14mm
Uchida Y et al	96	87	84%	-
Apostolakis et al	93	52	48%	0.89mm
Edurada h l et al	500	208	41.6%	1.1mm

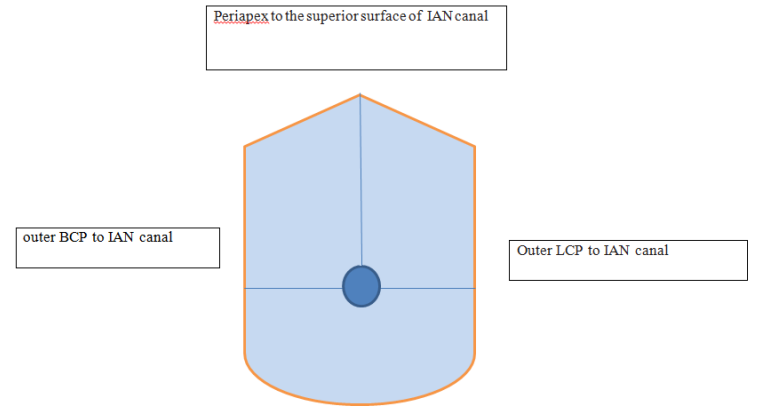


Figure 1: schematic representation of various parameters.

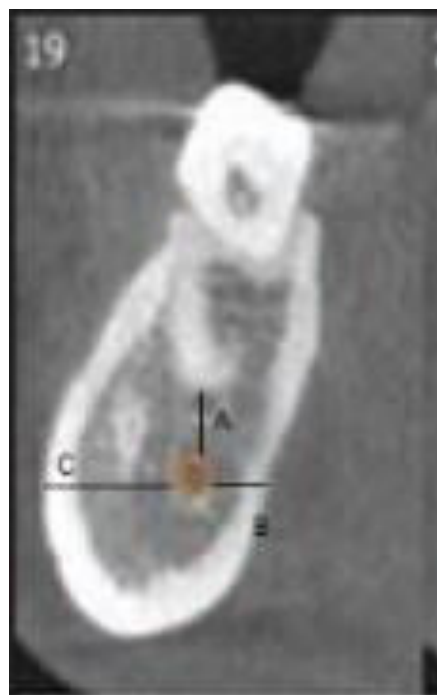

Figure 2.

- A- Distance between the peri-apex to the superior surface of IAN canal.
- B- Distance between lingual outer cortex to lingual outer surface of IAN canal.
- C- Distance between buccal outer cortex to outer to buccal outer surface of IAN canal.

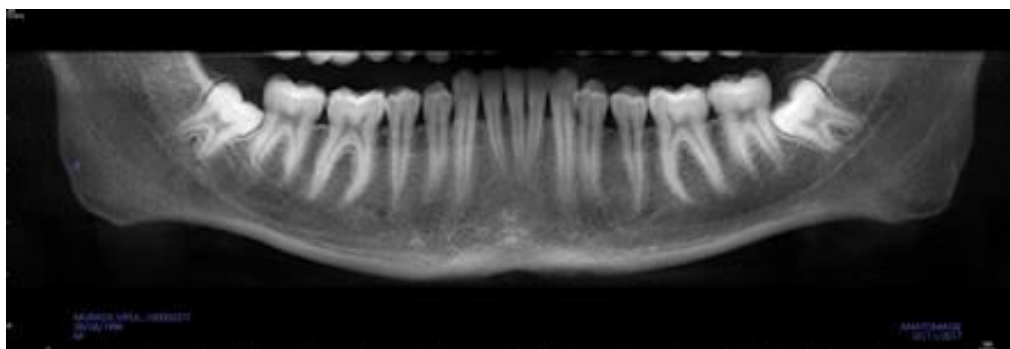


Figure 3. 2D reconstruction Mandible

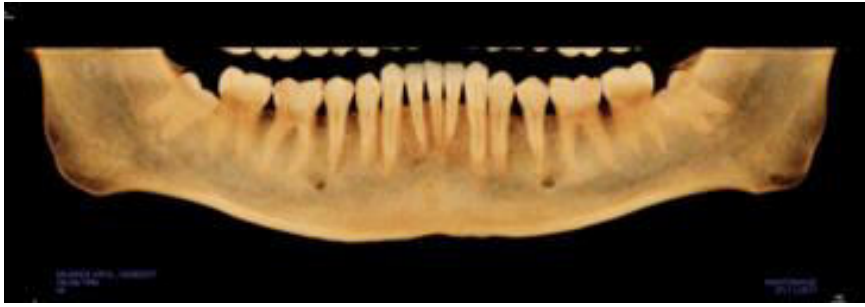

Figure 4. 2D reconstruction Mandible negative image

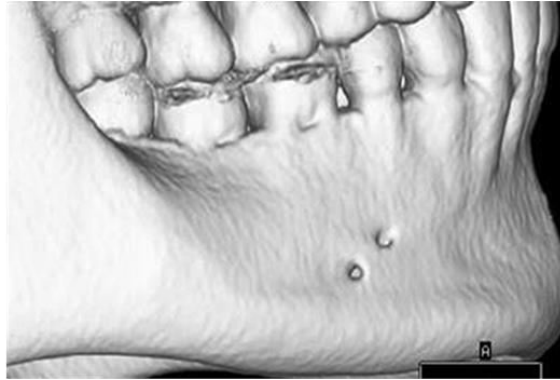


Figure 5: Accessory Mental Foramina.

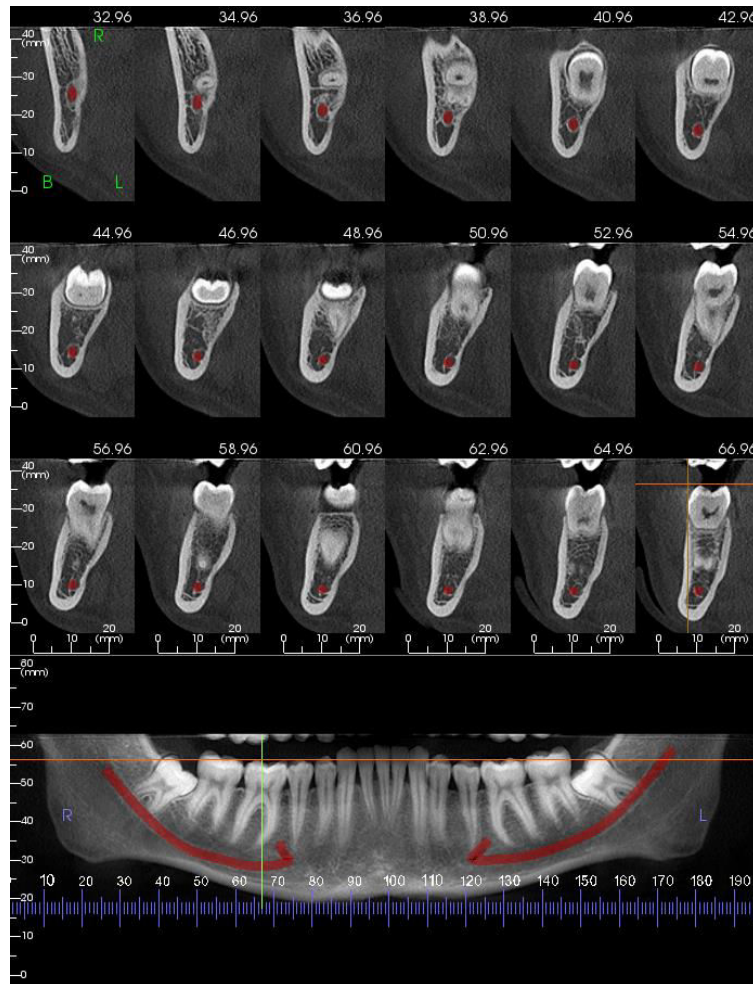


Figure 6: Anterior loop, IMC and IMN.

## DISCUSSION

Naitoh et al [5] compared the identification of an accessory mental foramen in panoramic radiographs and in reconstruction images (CBCT). After examining the 365 patients, the authors detected 37 AMF with the aid of CBCT and only 18 accessory mental foramina on panoramic radiographs. Katakami et al.[8], in a study of 150 patients, observed the presence of 17 AMF by CBCT. On the basis of these findings, the present study agreed with literature as 18 AMF were detected in 15 subjects, so its prevalence was 6.46%.

Apostolakis et al showed that, anterior loop could be identified in 48% of the cases with a mean length of 0.89mm [9]. The present study is not in agreement with their study as anterior loop in the mental region was detected in 91% (343) of the scans and the mean length from the medial margin of the mental foramen to the anterior loop proximal edge ranged from 2.6 to 3 mm (mean 3.15mm) The difference could be because of more detailed evaluation of anterior loop and measurement. However the results are in the line of some other studies like Hakan Eren et al and Parina F et al (Table 6).

The study shows that the lingual cortex is thicker at the first molar level, while the buccal cortex is much thicker at the second molar level. This probably could be due to consistent remodelling owing to the oral musculature attachments in the region. The mylohyoid line that serves to attach the mylohyoid musculature is oriented at higher position in 2<sup>nd</sup> molar region than 1<sup>st</sup> molar region, thus explaining the greater thickness of lingual cortex at the first molar level. On the buccal surface, the attachment of the masseter at the 2<sup>nd</sup> Molar region causes the greater thickness there. The canal was closest to the second molar roots in 61.6% of the cases, on average.

The difference between the right side and the left side was not remarkable, indicating that the right and left halves are mostly symmetrical. But in the literature the right half value is noted to be slightly higher than the left half values.

## CONCLUSION:

With the increasing demand for accurate preoperative assessment and planning prior to surgeries of these region, cross-sectional images such as CBCT may be utilized for more information on the appearance, location and course of the canal and their relation to other anatomical structures in the jaw bone including the apex of the tooth. CBCT provides an effective tool for pre-surgical evaluation of the neurovascular structures and its variations. This study will be helpful to get rid of iatrogenic injuries which tend to occur during the surgical

procedure of this region, as the presence of anatomical variation is frequently neglected.

However, the sample size (number of images) taken for this study was small and that too from a single private CBCT center. Thus, the results may not be the same for general population. Also results were correlated on the basis of gender and side but they were not correlated with occlusal load and habits of patients, as the patients were not contacted primarily. Both these factors could have affected the alveolar height and mandibular cortical width by activating the periodontal ligament and musculature involved. Systemic conditions of any patient also were not known. Hence, further studies could be done in this direction for more refinements of the results.

## REFERENCES

1. Juodzbalys G, Wang HL, Sabalys G. Anatomy of mandibular vital structures. Part II: Mandibular incisive canal, mental foramen and associated neurovascular bundles in relation with dental implantology. *J Oral Maxillofac Res* 2010.
2. Levine MH, Goddard AL, Dodson TB. Inferior alveolar nerve canal position: A clinical and radiographic study. *J Oral Maxillofac Surg* 2007; 65: 470-4.
3. Turkyilmaz, I. Implant Dentistry—A Rapidly Evolving Practice. In Tech, Europe, 2011, 3-18
4. Gerlach NL, Meijer GJ, Mall TJ, Mulder J, Rangel FA, Borstlap WA, *et al.* Reproducibility of 3 different tracing methods based on cone beam computed tomography in determining the anatomical position of the mandibular canal. *J Oral Maxillofac Surg* 2010; 68: 811-7.
5. Naitoh, M., Yoshida, K., Nakahara, K., Gotoh, K. and Arijji, E. Demonstration of the Accessory Mental Foramen Using Rotational Panoramic Radiography Compared with Cone-Beam Computed Tomography. *Clinical Oral Implants Research*, 2011; (22): 1415-1419.
6. Yu I, Wong Y. Evaluation of mandibular anatomy related to sagittal split ramus osteotomy using 3-dimensional computed tomography scan images. *International journal of oral and maxillofacial surgery*. 2008;37:521-8.
7. Patel S, Dawood A, Ford TP, Whaites E. The potential applications of cone beam computed tomography in the management of endodontic problems. *IntEndod J* 2007;40:818-30
8. Katakami K, Mishima A, Shiozak iK, Shimoda S, Hamada Y, Kobayashi K. Characteristics of accessory mental foramina observed on limited cone-beam computed tomography images. *J Endod*. 2008;34:1441-5.
9. Apostolakis D, Brown JE. The anterior loop of the inferior alveolar nerve: prevalence, measurement of its length and are commendation for interforaminal implant installation based on cone beam CT imaging. *Clin Oral Implants Res*. 2012;23:1022-30