

## Original Article

### Retrospective Evaluation of the Chest Radiographic Manifestations of Legionnaires' Disease

Apurva Vohra

Associate Professor, Department of Radiology, Ananta Institute of Medical Sciences and Research Center, Rajsamand, Rajasthan, India

#### ABSTRACT:

**Background:** Legionnaires' disease has a false but enduring status as an exotic plague. Legionellosis classically presents as two distinct clinical entities, Legionnaires' disease, a severe multisystem disease involving pneumonia, and Pontiac fever, a self-limited flu-like illness. Hence; we conducted the present retrospective study to assess the radiographic findings in patients with Legionnaires' disease. **Materials & methods:** The present study included retrospective assessment of Chest Radiographic Manifestations of Legionnaires' Disease. The present study included evaluation of reports and data of patients that were diagnosed with pneumonia or pneumonia-like disease and were referred for further investigations for confirming the diagnosis. Chest X-ray reports of all the patients were obtained from the records. Abnormalities present, were described as patchy, confluent or interstitial. We also recorded the data for the presence or absence of pleural effusion and cavitations. All the results were analyzed by SPSS software. **Results:** A total of 50 patients with diagnosis of Legionnaire's disease were included in the present study. Positive findings are seen in 84 percent of the patients. Patchy pattern of distribution was the predominant pattern seen in 62 percent of the patient population, followed by interstitial and confluent pattern. Unilobar involvement was seen in 50 percent of the patients. **Conclusion:** Patients with Legionnaire's disease exhibit a variety of radiographic manifestation varying from patchy distribution to interstitial or mixed pattern.

**Key words:** Chest radiograph, Legionnaire's disease

Received: 20 November 2017

Revised: 30 November 2017

Accepted: 12 December 2017

**Corresponding author:** Dr. Apurva Vohra, Associate Professor, Department of Radiology, Ananta Institute of Medical Sciences and Research Center, Rajsamand, Rajasthan, India

**This article may be cited as:** Vohra A. Retrospective Evaluation of the Chest Radiographic Manifestations of Legionnaires' Disease. J Adv Med Dent Sci Res 2018;6(1):138-141.

## INTRODUCTION

Legionnaires' disease has a false but enduring status as an exotic plague. In reality, this disease is a common form of severe pneumonia, but these infections are infrequently diagnosed. Failure to diagnose Legionnaires' disease is largely due to a lack of clinical awareness.<sup>1-3</sup> In addition, legionellae, the bacteria that cause this disease, are fastidious and not easily detected. Legionellosis classically presents as two distinct clinical entities, Legionnaires' disease, a severe multisystem disease involving pneumonia, and Pontiac fever, a self-limited flu-like illness.<sup>4-6</sup> Additionally, many persons who seroconvert to Legionella will be entirely asymptomatic. It is not possible to clinically distinguish patients with Legionnaires' disease from patients with other types of pneumonia.<sup>7-9</sup>

Hence; we conducted the present retrospective study to assess the radiographic findings in patients with Legionnaires' disease.

## MATERIALS & METHODS

The present retrospective study was planned in the department of radio-diagnosis of the medical institute and included retrospective assessment of Chest Radiographic Manifestations of Legionnaires' Disease. Ethical approval was obtained from the ethical committee of the institution and written consent was obtained from them after explaining in detail the entire research protocol. The present study included evaluation of reports and data of patients that were diagnosed with pneumonia or pneumonia-like disease and were referred for further investigations for confirming the diagnosis. Confirmation of the diagnosis of Legionnaires' disease in all the patients was done based on the presence of following parameters:

- Isolation of Legionella from the culture of respiratory specimens of the patients,

- Legionella antibody titre rising to the four fold value,
- Presence of Legionella antigen in urine

We obtained the chest X-ray reports of all the patients, from the records, at initial presentation of the disease. Abnormalities present, were described as patchy, confluent or interstitial. We also recorded the data for the presence or absence of pleural effusion and cavitations. Separate reviewers were employed for evaluating the chest X-rays. All the results were analyzed by SPSS software. Chi-square test was used for assessment of level of significance.

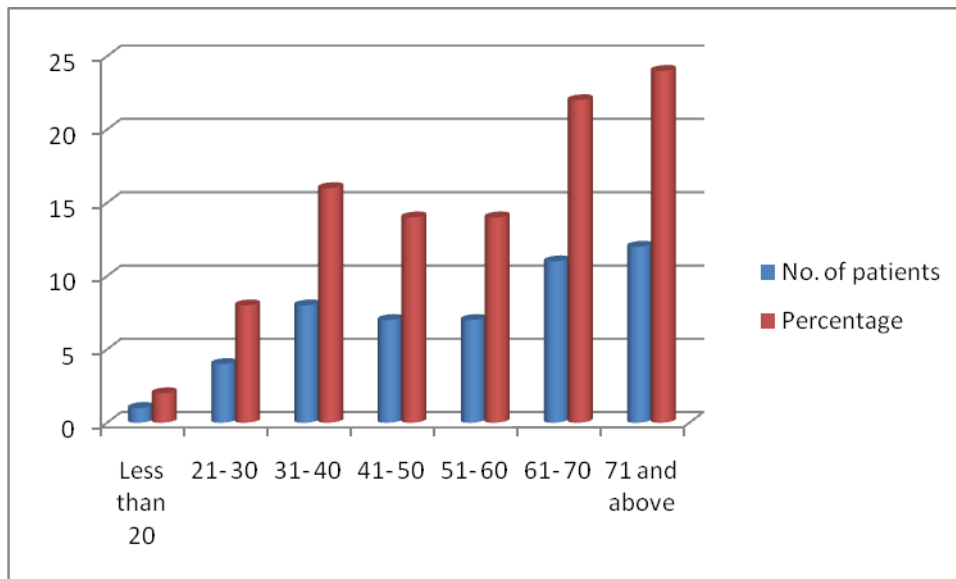
**RESULTS**

A total of 50 patients with diagnosis of Legionnaire's disease were included in the present study (Table 1). Majority of these patients (46%) belonged to the age group of more than 60 years. 28% of the patients belonged to the age group of 41 to 60 years. Chest radiographic findings of Legionnaire's disease patients in the present study are shown in Table 2. Positive findings are seen in 84 percent of the patients. Patchy pattern of distribution was the predominant pattern seen in 62 percent of the patient population, followed by interstitial and confluent pattern. Unilobar involvement was seen in 50 percent of the patients.

**Table 1:** Demographic details of all the patients with Legionnaire's disease

Age group (years)	No. of patients	Percentage
Less than 20	1	2
21- 30	4	8
31- 40	8	16
41- 50	7	14
51- 60	7	14
61- 70	11	22
71 and above	12	24
<b>Total</b>	<b>50</b>	<b>100</b>

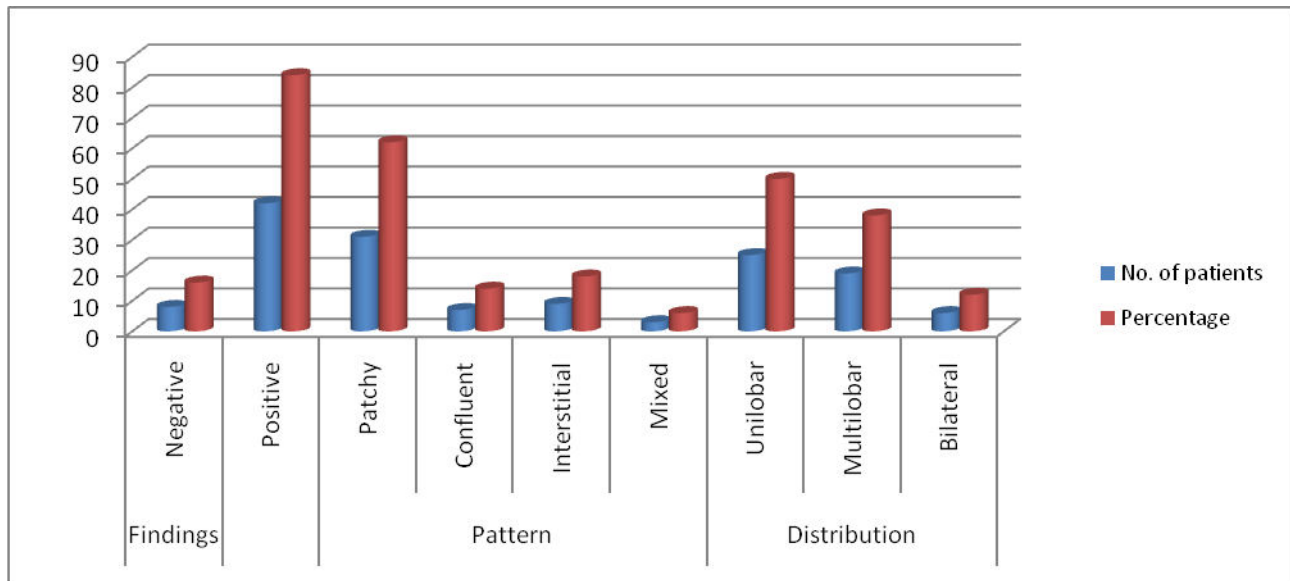
**Graph 1:** Demographic details of all the patients with Legionnaire's disease



**Table 2:** Chest radiographic findings of Legionnaire's disease patients in the present study

Parameter		No. of patients	Percentage
<b>Findings</b>	Negative	8	16
	Positive	42	84
<b>Pattern</b>	Patchy	31	62
	Confluent	7	14
	Interstitial	9	18
	Mixed	3	6
<b>Distribution</b>	Unilobar	25	50
	Multilobar	19	38
	Bilateral	6	12

**Graph 2:** Chest radiographic findings of Legionnaire's disease patients



**DISCUSSION**

In the present study, we observed that Legionnaire's disease occurred mostly in patients above 50 years of age. We observed positive findings in 84 percent of the patient population. Patchy distribution pattern was the most common pattern observed while unilobar distribution was most commonly seen. Tan MJ et al studied the serial radiographic manifestations of Legionnaire's disease from the initial presentation on admission to recovery using strict criteria for the diagnosis of infection. They prospectively studied the chest radiographs of patients hospitalized with a diagnosis of community-acquired pneumonia in Summit County, Ohio between November 1990 and November 1992. Forty-three patients fulfilled strict criteria for legionellosis. The diagnosis of infection was based on the criteria of "definite" diagnosis as defined by the Ohio Community-Based Pneumonia Incidence Study Group report. The criteria included the isolation of the microorganism, the presence of a significant antibody rise, or the presence of Legionella antigen in the urine. Forty of 43 patients had admission radiographs interpreted as compatible with pneumonia. In spite of appropriate antimicrobial therapy, worsening of the infiltrates was found in more than half of the patients within the first week. Twenty-seven patients were observed to have pleural effusion during the course of hospitalization: 10 effusions were found on admission, another 14 developed during the first week, and 3 new effusions were discovered after the first week. Cavitation was found in only one patient. None of the patients had apical involvement. This study confirmed previous reports using less stringent etiologic diagnosis criteria that chest radiographic findings in Legionnaire's disease are not specific. Even with appropriate therapy, more than half of the patients will have worsening of the infiltrates during the first week. Pleural effusion is common among our patients, and it is frequently detected during the serial radiographic studies during the first week of hospitalization.<sup>9</sup> Zhang Z et al explored the chest

radiographic characteristics of community-acquired Legionella pneumonia in the elderly. Serial chest radiographs obtained in 34 patients hospitalized with serologically proven Legionella pneumonia were retrospectively reviewed. Chest X-ray features of an aged group of  $\geq 65$  years were assessed and compared with a non-aged group of  $<65$  years old with regard to initial patterns and distributions of pulmonary abnormalities, accompanying signs, and progression. The most common initial presentation was a patchy alveolar infiltrate involving a single lobe, most often the lower lobe. There was no middle or lingular lobe involvement in the aged group patients, but bilateral pleural effusion was significantly more common in this group. In the aged group patients, radiographic progression following adequate therapy, despite a clinical response, was more often noted and the radiographs were less likely to have returned to the pre-morbid state at discharge, but the differences were not significant between the two groups. The discrepancy between imaging findings and clinical symptoms seems more prominent in community-acquired Legionella pneumonia in the elderly.<sup>10</sup>

Kim KW et al described the chest radiographic and computed tomographic (CT) findings of legionella pneumonia. Serial chest radiographs and CT scans obtained in 12 patients with serologically proven Legionella pneumophila pneumonia were retrospectively reviewed. Chest CT findings were analyzed with regard to patterns and distributions of pulmonary abnormalities. Nine of the 12 patients were in an immunocompromised state, that is, steroid therapy (n = 8) and myelodysplastic syndrome (n = 1), and 6 of the 8 steroid users were on high-dose steroid. All patients showed multilobar or multisegmental pulmonary infiltrates on CT scans. The CT findings were categorizable as; predominantly airspace consolidations (n = 6), mixed lesions with lobular consolidation and ground-glass opacity (GGO) (n = 3), and pure GGO lesions (n = 2). Five of the 6 patients on high-dose steroid therapy had lobar consolidations

with (n = 4) or without a cavity (n = 1), and 1 patient had a mixed lesion. The most common CT findings in legionella pneumonia were multilobar or multisegmental consolidation and GGO. Cavitory lobar consolidation occurred commonly in patients on high-dose steroid therapy.<sup>11</sup>Yagyu H et al evaluated mild Legionella pneumonia (LP) by chest CT, and clinical features. In June 2000, an outbreak of LP occurred in Japan. Eight patients with mild LP (seven men, one woman; mean age 55.9 years) had fevers of more than 38 degrees C, but respiratory symptoms were observed only in four. Chest CT was performed before starting an appropriate treatment. CT images were assessed by the distribution of ground-glass opacity (GGO), consolidation, and the existence of pleural effusion. Chest CT findings: multiple segments were affected in all of the patients, (pleural effusion in three, peripheral lung consolidation in seven, and GGO in seven). GGO was located around the consolidation in six patients. Mild LP may present as fever without respiratory symptoms. Chest CT findings of mild LP are bilateral, multiple affected segments and peripheral lung consolidation with GGO.<sup>12</sup>

### CONCLUSION

From the above results, the authors concluded that patients with Legionnaire's disease exhibit a variety of radiographic manifestation varying from patchy distribution to interstitial or mixed pattern. However; future studies are recommended for better results.

### REFERENCES

1. Fraser DW, Tsai TR, Orenstein W, et al. Legionnaires' disease: description of an epidemic of pneumonia. *N Engl J Med* 1977; 297: 1189–97.
2. Edelstein PH. Legionella. In: Versalovic J, Carroll KC, Funke G, Jorgensen JH, Landry ML, Warnock DW, eds. *Manual of clinical microbiology*, 10th edn. Washington, DC: American Society of Microbiology Press, 2011: 770–85.
3. Jarraud S, Descours G, Ginevra C, Lina G, Etienne J. Identification of legionella in clinical samples. *Methods MolBiol* 2013; 954: 27–56.
4. Doebbeling BN, Wenzel RP. The epidemiology of Legionella pneumophila infections. *SeminRespir Infect* 1987; 2: 206–21.
5. Lück C, Fry NK, Helbig JH, Jarraud S, Harrison TG. Typing methods for legionella. *Methods MolBiol* 2013; 954: 119–48.
6. Joly JR, McKinney RM, Tobin JO, Bibb WF, Watkins ID, Ramsay D. Development of a standardized subgrouping scheme for Legionella pneumophilasero group 1 using monoclonal antibodies. *J ClinMicrobiol* 1986; 23: 768–71.
7. Helbig JH, Kurtz JB, Pastoris MC, Pelaz C, Lück PC. Antigenic lipopolysaccharide components of Legionella pneumophila recognized by monoclonal antibodies: possibilities and limitations for division of the species into serogroups. *J ClinMicrobiol* 1997; 35: 2841–45.
8. Dournon E, Bibb WF, Rajagopalan P, Desplaces N, McKinney RM. Monoclonal antibody reactivity as a virulence marker for Legionella pneumophilaserogroup 1 strains. *J Infect Dis* 1988; 157: 496–501.
9. Tan MJ1, Tan JS, Hamor RH, File TM Jr, Breiman RF. The radiologic manifestations of Legionnaire's disease. The Ohio Community-Based Pneumonia Incidence Study Group. *Chest*. 2000 Feb;117(2):398-403.
10. Zhang Z1, Liu X2, Chen L3, Qiu J3. Chest radiographic characteristics of community-acquired Legionella pneumonia in the elderly. *Chin Med J (Engl)*. 2014;127(12):2270-4.
11. Kim KW et al. Chest computed tomographic findings and clinical features of legionella pneumonia. *J Comput Assist Tomogr*. 2007 Nov-Dec;31(6):950-5.
12. Yagyu H1, Nakamura H, Tsuchida F, Sudou A, Kishi K, Oh-ishi S, Matsuoka T. Chest CT findings and clinical features in mild Legionella pneumonia. *Intern Med*. 2003 Jun;42(6):477-82.

**Source of support:** Nil

**Conflict of interest:** None declared

This work is licensed under CC BY: *Creative Commons Attribution 3.0 License*.