

CASE REPORT

ESTHETIC REHABILITATION OF SEVERELY DECAYED PRIMARY INCISORS USING GLASS IMPREGNATED FIBRE POST AS POST AND CORE: A TREATMENT OPTION

Ajay K. Kapoor¹, Seema Thakur², Parul Singhal³, Deepak Chauhan⁴, Cheranjeevi Jayam⁴

¹Post graduate Student, ²Professor & Head, ³Assistant Professor, ⁴Senior Lecturer, Department of Paediatric and Preventive Dentistry H.P.G.D.C. Shimla

ABSTRACT:

Introduction: Restoration of primary incisors, which have been severely damaged by extensive caries or trauma, is a difficult task for the Pediatric dentist. Primary teeth dictate the physical appearance, and their structural affects leads to loss of esthetics compromised mastication, poor phonetics, development of aberrant habits, neuromuscular imbalance, and difficulty in socio- psychological adjustment of the child. **Case description:** This Case Report discusses the restoration of severely decayed primary maxillary incisors using composite resin restoration reinforced with Glass impregnated post in anterior teeth in a 4 years old male patient. **Discussion:** The use of intracanal posts in endodontically treated teeth improves the retention of a eventual restoration. The use of impregnated fiber glass post together with flowable composite offers an alternative where all components are bonded together to form a firmly attached restoration. **Conclusion:** The technique of using glass impregnated composite resin as post and core has shown promising results and has presented Pediatric dentists with an additional treatment option.

Keywords: Esthetic rehabilitation, Early childhood caries, Fibre posts.

Corresponding author: Dr. Ajay K. Kapoor, Post graduate Student, Department of Paediatric and Preventive Dentistry H.P.G.D.C. Shimla, Himachal Pradesh pin code- 171001

This article may be cited as: Kapoor AK, Thakur S, Singhal P, Chauhan D, Jayam C. Esthetic rehabilitation of severely decayed primary incisors using glass impregnated fibre post as post and core: A treatment option. J Adv Med Dent Scie Res 2017;5(1):142-145.

Access this article online

Quick Response Code



Website: www.jamdsr.com

DOI:

10.21276/jamdsr.2017.5.1.32

INTRODUCTION

Dental caries and trauma are predominant cause for tooth loss in primary dentition. Early child hood caries (ECC) is a rapidly developing and progressing type of dental caries with distinctive pattern most commonly involving maxillary central incisors, lateral incisors and the maxillary and mandibular 1st primary molars. ¹ In extreme cases, ECC can even lead to complete loss of the crown structure. ²

In the last few decades, the new materials like polycarbonate crowns, strip crowns, art glass crowns, veneered stainless steel crown were introduced which restore the carious teeth with sufficient tooth structure. In cases where the teeth are severely damaged with loss of crown structure, these materials fail to withstand the occlusal forces. ³ The use of an intracanal post in endodontically treated teeth improves the retention for a longer-lasting restoration. A wide range of materials can be used for this purpose, such as resin composite, metal,

biologic and prefabricated posts, orthodontic wire posts, and, recently, omega-shaped stainless steel wire posts ⁴.

A case of 4 year old child is being presented here who had lost most of the coronal tooth structure of his upper anterior teeth due to ECC. The treatment was done by pulpectomy followed by placement of glass fiber post in canal and building of coronal part with crown buildup technique using composite resin material.

CASE REPORT

A 4 year old male child presented to the Department of Pediatric and Preventive Dentistry, H.P. Government Dental College, Shimla (Himachal Pradesh) with the chief complaint of decayed upper front teeth.

The prenatal, natal, post natal and medical history were noncontributory. Diet patterns showed that child was fed cariogenic food frequently. The history of night time bottle feeding was present till 3 years of age. This was the

patient's first dental visit, and oral hygiene was neglected with fair maternal oral hygiene.

On clinical examination 51, 52, 61, 62, 53, 54, 55, 63, 64, 75, and 85 were carious. The remaining tooth structure of maxillary anterior teeth were found to be firm, with an extension of the remaining crown of 1 mm above the gingival margin (Fig. 1). The treatment plan was explained to the child's parents along with, its advantage and drawbacks, other treatment option and consequence if treatment was not carried out.

Based on clinical and radiological findings the treatment plan was divided into the following two steps:

1. Restorative and Endodontic Phase.

In first visit all the active carious lesions were restored with GIC. Gross carious lesions were removed with a no. 330 round carbide steel bur. The pulp chamber was opened & for working length determination Intraoral periapical radiograph was taken, pulp tissue was extirpated using K-files (Mani INC, Tochigi, Japan). After copious irrigation, the root canals were dried using paper points. A thick mix of zinc oxide eugenol paste (Deepak Enterprise, Mumbai, India) was then condensed with hand pluggers (Mani INC, Tochigi, Japan) into the canal (Fig. 2) by careful isolation using cotton rolls and saliva ejectors as teeth under treatment do not had enough crown structure for rubber dam application.

Endodontic treatment of 54 and 64 were completed in subsequent visits followed with GIC (Fuji 2, GIC Corp, Tokyo, Japan) restoration and stainless steel crown (Kids crown, Shin Heung, Republic of Korea) (Fig. 3 & 4).

2. Phase two: esthetic rehabilitation

The post space was prepared in anterior teeth during second appointment by removing approximately 4 mm of Zinc oxide eugenol (Deepak Enterprise, Mumbai, India) material using slow moving thin straight fissure bur and post space radiograph was taken. A 1 mm base of glass ionomer cement (Fuji 2, GIC Corp, Tokyo, Japan) were placed to isolate the obturated material from the rest of post space (Fig.5). GIC sticking to walls of root canal was removed using sharp spoon excavator. For each canal a glass fiber post (Interlig, Angelus Brasil) (Fig. 6) of corresponding size was trail fit and adjusted to 3 mm into the canal and 2 mm outside the canal by measuring the post length upto 5mm. Prepared cavity was acid etched for 15 sec with a 37% phosphoric acid gel, rinsed, dried and two coats of a dentin adhesive single bond (Adper™, 3M ESPE) were applied with micro brush. The tip of flowable composites was placed 2-3 mm below the CEJ and the composite was injected. The glass post was inserted into the canal and light cured. The coronary portion of the fiber post was completely restored using resin composite (Fig.7). After checking the occlusion and the removal of any occlusal interference, final finishing and polishing of the restoration was performed thus restoring a new smile of the child (Figs.9). Following completion of restoration of

51, 52, 62 and 62 intra oral periapical radiograph was taken (Fig. 8). Fluoride varnish therapy was also given, along with dietary counseling, care of the restorations and importance of maintenance of good oral hygiene as well as the importance of periodic dental visits (3,6,12 months follow-up) for preservation of the primary dentition was described to the patient and parents. (Fig. 10)

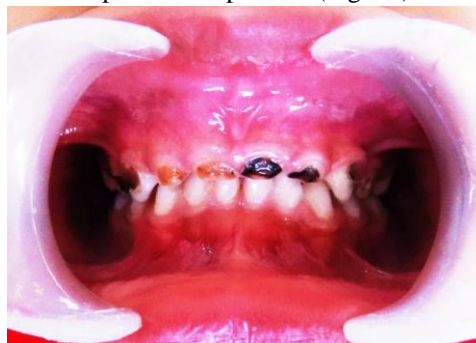

Figure 1: Preoperative intraoral photograph frontal view

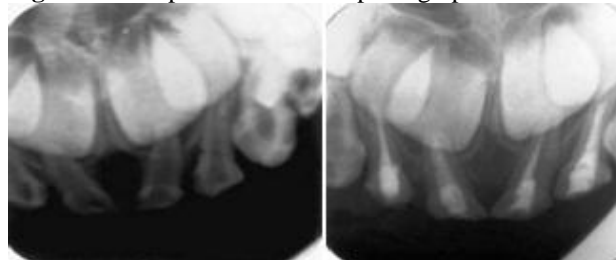


Figure 2: Preoperative and Postoperative intraoral periapical radiograph of 51, 52, 61, 62.

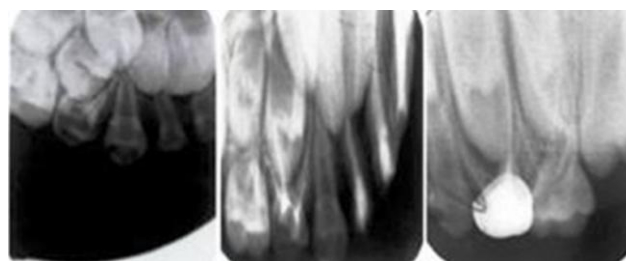


Figure 3: Preoperative and Postoperative intraoral periapical radiograph of 54

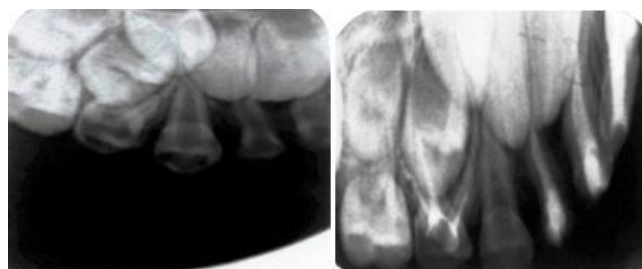


Figure 4: Preoperative and intraoral periapical radiograph of 64

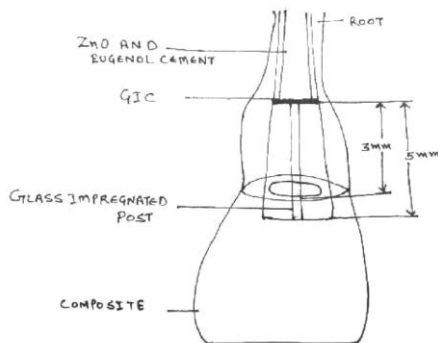


Figure 5: Figure of plan for construction of restoration.

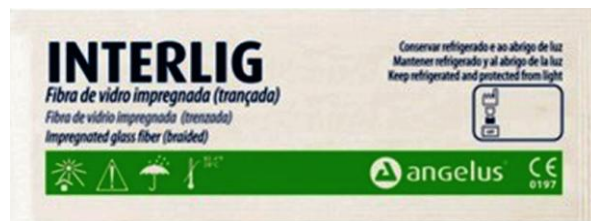

Figure 6: Glass impregnated post used

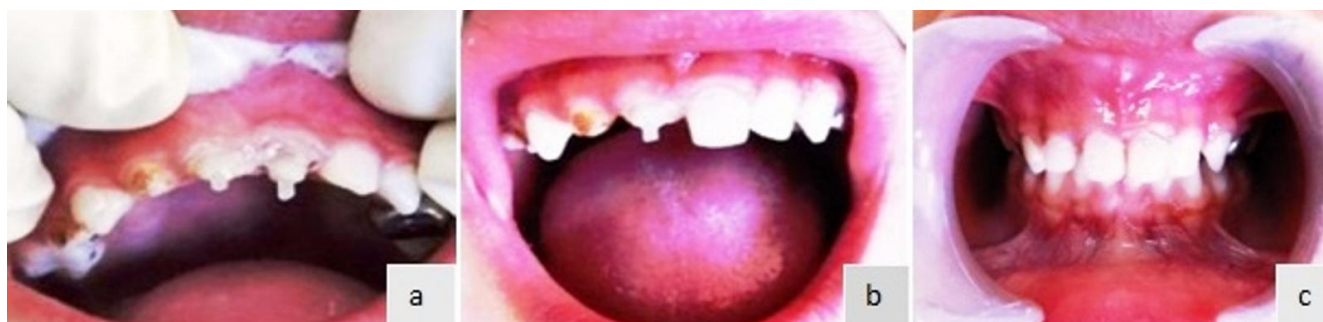

Figure 7: Placement and curing of Glass impregnated post into root and esthetically completed restoration canals

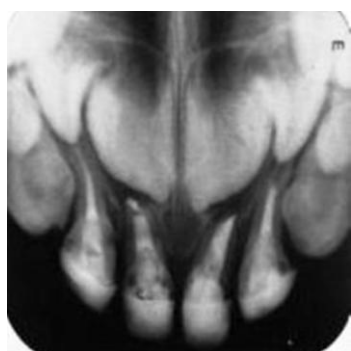

Figure 8: Postoperative radiograph after glass post insertion of 51,52,61,62.

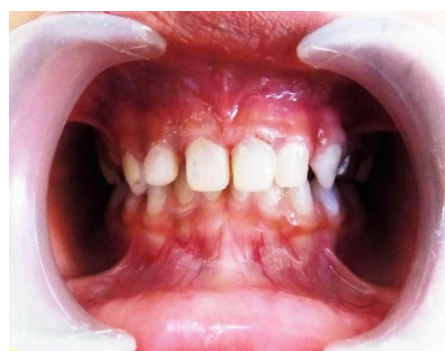

Figure 10: Esthetic smile of the patient 6 month follow up

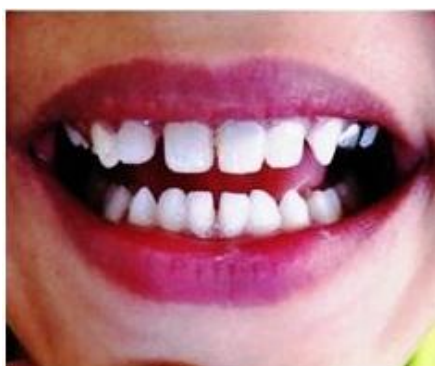

Figure 9: Esthetic smile of the patient established

DISCUSSION

Restoration of deciduous anterior and posterior teeth with severe loss of coronal structure is a challenging task for the dentists. The main aim is to avoid extraction of these teeth and restore them so that child is able perform normal masticatory function, and good esthetics is maintained. The use of intracanal posts in endodontically treated teeth improves the retention of a eventual restoration. In the past, alpha or omega shaped orthodontic wires⁵, stainless steel prefabricated posts⁶, natural teeth from a tooth bank have been used⁷. Prefabricated posts are fast, cheap, and easy to use, but they do not consider the individual shape of the root canal. Although metal posts are indicated for primary

teeth but because of their color metal post do not meet the esthetic requirement and may cause problems during the course of natural exfoliation.⁴ Composite post provides acceptable esthetics, however, there is risk of loss of retention owing to polymerization shrinkage⁸.

The use of fiberglass post together with flowable composite and bonding agent offers an alternative where all components are bonded together to form a firmly attached restoration unit. This technique utilizes the coronal portion of the root, which is the strongest part of the root to transmit any functional stresses and may add to success.⁹

In this case the restoration showed good retention and marginal adaptation at 12 month follow up. Various studies also shows that fiberglass posts exhibit better retention and marginal adaptation than omega shaped stainless steel wire.^{10,11}

The direct restorative technique used in this report is an easy to perform single sitting procedure without any additional laboratory processes. The core length of the intra canal post system is equal to the recommended length of 3mm for deciduous teeth occupying the cervical one-third of the canal to avoid interfering with the process of primary tooth root resorption and permanent tooth eruption.¹²

In cases with multiple severe decayed primary anterior teeth, especially in smaller children with rampant caries, the presented technique is simple, economical and easy to execute and practical for all dentists.

REFERENCES

1. Schwartz SS, Rosivack RG, Michelotti P. A child's sleeping habit as a cause of nursing caries. *J. Dent Child* 60:22-25, 1993.

- Richardson BD, Cleaton –Jones PE. Nursing bottle caries. *J pediatric Dent* 1977; 60:748-749.
- Rashmeet Walia et al Rehabilitating Grossly Decayed Primary Anterior Teeth: How and Why? *International Journal of Oral Health Dentistry*, October – December 2015;1(4):187-189.
- Metha, Gulati A, Basappa N, Raju OS. Esthetic rehabilitation of severely decayed primary incisors using glass fiber reinforced composite: a case report. *J Dent Child* 2012;79:1.
- Mathias RS, Kramer PF, Imperato JCP, Guedes-Pinto AC. Operative and restorative dentistry. Guedes-pinto AC. *Pediatric dentistry*. 1st ed. Sao Paulo: Santos; 1997.p. 569-607.
- Cintron CI. Esthetics in pediatric dentistry. *N Y State Dent J* 1995;61:30-3.
- Sahana S, Vasa AAK, Sekhar R. Esthetic crowns for primary teeth: a review. *AnnEssences Dent* AprileJune 2010;II(Issue 2).
- Shah S, Bargale S, Anuradha KVR, Patel N. Posts in Primary Teeth-A Sile for Better Smile. *J Adv Med Dent Scie Res* 2016;4(1):58-64.
- Motisuki C, Araraquara,, Santos-Pinto L, Giro EM. Restoration of severely decayed primary incisors using indirect composite resin restoration technique. *Int J of Paediatr Dent* 2005 Jul;15(4):282-286.
- Sharaf AA. The application of fiber core post in restoring badly destroyed primary incisors. *J Clin Pediatr Dent* 2002 Spring;26(3):217-224.
- Subramaniam P , Babu KL, Sunny R. Glass fiber reinforced composite resin as an intracanal post— a clinical study. *J Clin Pediatr Dent* 2008 Spring;32(3):207-210.
- Eshghi A, Esfahan RK, Khoroushi M. A simple method for reconstruction of severely damaged primary anterior teeth. *Dent Res J* 2011;8:221–5.

Source of support: Nil

Conflict of interest: None declared

This work is licensed under CC BY: **Creative Commons Attribution 3.0 License.**