

Original Research

Determination of oral solifenacin succinate in glaucoma paradox during overactive bladder treatment- A clinical study

Dr. Pratipal Singh¹, Dr. Poonam Singh²

¹Associate Professor, Department of Surgery, Hind Institute of Medical Sciences, Safedabad Barabanki U.P., India;

²Assistant professor, Department of Ophthalmology, Hind Institute of Medical Sciences, Ataria Sitapur, U.P., India

ABSTRACT:

Background: The present study was conducted to determine the effect of oral solifenacin succinate in glaucoma paradox during overactive bladder treatment. **Materials & Methods:** The present study was conducted on 60 patients of overactive bladder and 40 healthy females. Patients were divided into 2 groups. Group I were given oral 5 mg solifenacin succinate/day. Group II comprised of urogynecologically healthy age-matched consecutive subjects with no history of ocular disease. Fundus examination using a 90-diopter lens was performed in all subjects on day 0 and 30th. **Results:** The mean IOP on day 0 in group I was 16.46 mm Hg and in group II was 15.30 mm Hg and on 31st day was 16.42 mm Hg and 15.72 mm Hg in group I and II respectively. The difference was non- significant ($P < 0.05$). **Conclusion:** Authors found that treatment with solifenacin succinate in females with OAB had no clinically significant effect on intraocular pressure values

Key words: Anticholinergics, Glaucoma, Solifenacin succinate.

Received: August 15, 2020

Accepted: October 25, 2020

Corresponding author: Dr Poonam Singh, Assistant professor, Department of ophthalmology, Hind institute of medical sciences, Ataria Sitapur, U.P., India

This article may be cited as: Singh P, Singh P. Determination of oral solifenacin succinate in glaucoma paradox during overactive bladder treatment- A clinical study. J Adv Med Dent Sci Res 2020;8(11):130-133.

INTRODUCTION

Overactive bladder (OAB) is a common disorder with a negative effect on the quality of life. OAB is identified as urge incontinence alone or together with urinary incontinence, accompanied by frequent urination and nocturia. Anticholinergics are the preferred treatment. The objective of medicinal therapy is to decrease unpreventable or unexpected detrusor contractions and the contraction frequency by blocking the muscarinic receptors and stopping the spontaneous muscle activity in the filling phase.¹ Untreated OAB, particularly in patients with urge incontinence, eventually has a negative impact on health-related quality of life.²

Although OAB and glaucoma are common, with an individual and coexistent prevalence higher in the elderly, the instructions provided with anticholinergics often state that the generalized term 'glaucoma' is a contraindication, without specifying the mechanism of

drug-induced angle-closure glaucoma. This statement is confusing to both clinicians and patients, and deprives many patients with OAB and a history of glaucoma of the most suitable drug treatment.³

The anticholinergics have been suggested in theory to induce angle-closure glaucoma by narrowing the angle of the anterior chamber, by pupillary dilatation, and by forward movement of the iris-lens diaphragm.⁴ Treatment for OAB usually begins with lifestyle modifications (weight loss and dietary changes) and behavioral therapy (bladder training and pelvic muscle exercises).⁵ Pharmacotherapy is the second-line treatment for OAB. Anticholinergic drugs (such as oxybutinin, tolterodine, and solifenacin) have been among the main treatment options for many years.⁶ The present study was conducted to determine the effect of oral solifenacin succinate in glaucoma paradox during overactive bladder treatment (OAB).

MATERIALS & METHODS

The present study was conducted in the department of Ophthalmology & Urology on 60 patients of overactive bladder and 40 healthy females. Patients were informed regarding the study and their written consent was obtained. Ethical clearance was obtained before starting the study. The diagnosis of OAB was made at the urogynecology department following detailed gynecological examination.

Demographic profile such as name, age, gender etc. was recorded. Patients were divided into 2 groups. Group I were given oral 5 mg solifenacin succinate/day. Group

II comprised of urogynecologically healthy age-matched consecutive subjects with no history of ocular disease besides refractive errors and presbyopia, an IOP ≤ 21 mmHg and a normal optic disc appearance. A complete ophthalmological examination with best corrected Snellen visual acuity testing, slit-lamp examination and dilated fundus examination using a 90-diopter lens was performed in all subjects on day 0 and 30th. Results thus obtained were used for statistical analysis. P value less than 0.05 was considered significant.

RESULTS:

Table I Distribution of patients

Groups	Group I	Group II
Drug	5 mg/day solifenacin succinate	Healthy (Control)
Number	60	40

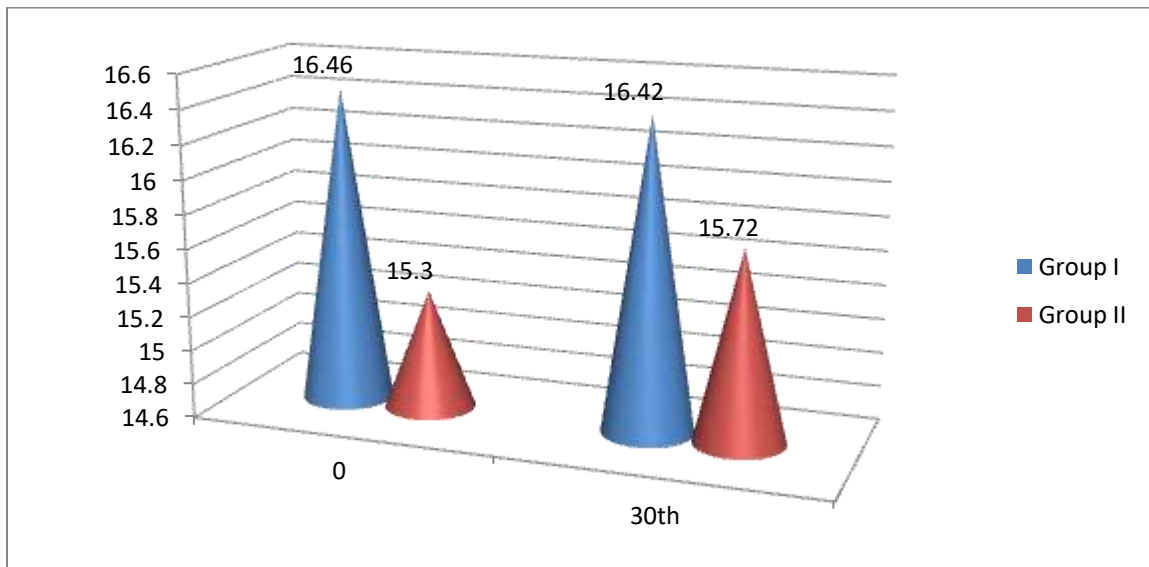
Table I shows that group I (60) consisted of the female patients were given 5 mg/day solifenacin succinate and group II (40) comprised of urogynecologically healthy age-matched subjects.

Table II Determination of intraocular pressure (IOP) in both groups

Days	Group I (mm Hg)	Group II (mm Hg)	P value
0	16.46	15.30	0.15
30 th	16.42	15.72	0.20

Table II, graph I shows that mean IOP on day 0 in group I was 16.46 mm Hg and in group II was 15.30 mm Hg and on 31st day was 16.42 mm Hg and 15.72 mm Hg in group I and II respectively. The difference was non-significant (P < 0.05).

Graph I Determination of intraocular pressure (IOP) in both groups



DISCUSSION

Glaucoma is a heterogeneous group of diseases that have in common a characteristic optic neuropathy and visual-field defects, for which elevated intra-ocular pressure is the major risk factor.⁷ There are two major types of glaucoma primary open-angle glaucoma and angle closure glaucoma. Primary open-angle glaucoma is the most common type of glaucoma. It happens gradually, where the eye does not drain fluid as well as it should (like a clogged drain). As a result, eye pressure builds and starts to damage the optic nerve.⁸ This type of glaucoma is painless and causes no vision changes at first. Angle-closure glaucoma results from narrowing or closure of the anterior chamber caused by the forward bowing of the iris, thus obstructing outflow of aqueous humor through the trabecular meshwork/Schlemm's canal system.⁹ Anticholinergic drugs are the most effective agents currently available to control OAB symptoms. As parasympathetic cholinergically mediated innervation is the predominant stimulus for bladder contraction, anticholinergics can improve frequency, urgency and urge incontinence by blocking receptors of the detrusor muscle.¹⁰ The present study was conducted to determine the effect of oral solifenacin succinate in glaucoma paradox during overactive bladder treatment (OAB).

In present study, group I (60) consisted of the female patients were given 5 mg/day solifenacin succinate and group II (40) comprised of urogynecologically healthy age-matched subjects. Kato et al¹¹ used a self-description questionnaire in 417 urologists for patients with an OAB and glaucoma. Of the 155 respondents, 76 (49%) routinely enquired about a history of glaucoma before prescribing anticholinergics, and 45 (29%) routinely referred patients with such a history to ophthalmologists. To treat patients with OAB and glaucoma, 102 (66%) would prescribe anticholinergics if permission were available from the ophthalmologist, 33 (21%) chose other treatments and 17 (11%) abandoned treatment. Forty-nine urologists (32%) were currently prescribing anticholinergics to patients with glaucoma. As to knowledge about glaucoma, 132 (85%) urologists knew that there were two types of glaucoma and 98 (63%) knew about laser iridotomy. The proportion of urologists who knew of the two types of glaucoma and asked patients for this information was significantly higher in university than in general hospitals ($P < 0.05$).

We found that mean IOP on day 0 in group I was 16.46 mm Hg and in group II was 15.30 mm Hg and on 31st day was 16.42 mm Hg and 15.72 mm Hg in group I and II respectively. The difference was non-significant ($P < 0.05$). Sekeroglu et al¹² included 60 female patients with a clinical diagnosis of OAB in whom use of oral solifenacin succinate 5 mg/day (group I) and 20 age-matched healthy female subjects (group II) underwent

complete ophthalmological examination, including IOP measurement at the beginning of the oral treatment and after 4 weeks. No statistically significant change was detected in the IOP (from 16.05 ± 2.30 mmHg to 16.30 ± 2.25 mmHg at the 4th week in group I, $p = 0.160$; from 15.60 ± 2.14 mmHg to 15.60 ± 2.09 mmHg at the 4th week in group II, $p = 0.864$) of the eyes in both groups.

Turkoglu et al¹³ investigated the effect of solifenacin succinate on intraocular pressure (IOP) and dry eye in patients with overactive bladder (OAB) on 93 female OAB patients with a mean age of 48.59 ± 11.28 years (range 19–75 years). Solifenacin succinate (5 mg/day) was started orally. All procedures were repeated at the 4- and 12-week follow-up, and the effects and side effects were documented. No statistically significant difference was observed in IOP ($p = 0.282$, $p = 0.189$) and tear secretion ($p = 0.122$, $p = 0.071$) values from the baseline (day 0) to the 12th week in OAB patients using solifenacin succinate. Solifenacin succinate treatment was terminated in 3 patients owing to dry eye in 1 patient, increased IOP in 1 patient, and systemic side effects in 1 patient. Constipation and dry mouth at various rates were the most common systemic side effects observed. Solifenacin succinate is useful in eliminating OAB symptoms in female patients, but can cause systemic side effects. It had no significant side effects on tear secretion (Schirmer I) and IOP. Authors concluded that solifenacin succinate could be reliably used in pure OAB patients without comorbidity in terms of dry eye and IOP.

The limitation of the study is small sample size.

CONCLUSION

Authors found that treatment with solifenacin succinate in females with OAB had no clinically significant effect on intraocular pressure values.

REFERENCES

1. Ouslander JG, Blaustein J, Connor A et al. Pharmacokinetics and clinical effects of oxybutynin in geriatric patients. *J Urol* 1988; 140(1): 47–50.
2. Altan-Yaycioglu R, Yaycioglu O, Aydin Akova Y et al. Ocular side-effects of tolterodine and oxybutynin, a single-blind prospective randomized trial. *Br J Clin Pharmacol* 2005; 59(5):588–592.
3. Frischmeyer KJ, Miller PE, Bellay Y et al. Parenteral anticholinergics in dogs with normal and elevated intraocular pressure. *Vet Surg* 1993; 22(3):230–234.
4. Homma Y, Kakizaki H, Gotoh M et al. Epidemiologic survey on urination. *J Jpn Neurogenic Bladder Soc* 2003; 14:266–277.
5. Tripathi RC, Tripathi BJ, Haggerty C. Drug-induced glaucomas: mechanism and management. *Drug Saf* 2003; 26(11):749–767.
6. Garely AD, Kaufman JM, Sand PK et al. Symptom bother and health-related quality of life outcomes following solifenacin treatment for overactive bladder: the VESiCare

- Open-Label Trial (VOLT). *Clin Ther* 2006; 28(11):1935–1946.
7. Sung VC, Corridan PG. Acute-angle closure glaucoma as a side-effect of oxybutynin. *Br J Urol* 1998; 81(4):634–635.
 8. Iwase A. The prevalence of glaucoma in Japan. *Ganka* 2003; 45: 733–739.
 9. Milsom I, Abrams P, Cardozo L et al. How widespread are the symptoms of an overactive bladder and how are they managed? A population-based prevalence study. *BJU Int* 2001; 87: 760–6.
 10. Andersson KE. Antimuscarinics for treatment of overactive bladder. *Lancet Neurol* 2004; 3(1):46–53
 11. Kato K, Yoshida K, Suzuki K, Murase T, Gotoh M. Managing patients with an overactive bladder and glaucoma: a questionnaire survey of Japanese urologists on the use of anticholinergics. *BJU international*. 2005 Jan;95(1):98-101.
 12. Sekeroglu MA, Hekimoglu E, Petricli İS, Tasci Y, Dolen I, Arslan U. The effect of oral solifenacin succinate treatment on intraocular pressure: glaucoma paradox during overactive bladder treatment. *International urogynecology journal*. 2014 Nov 1;25(11):1479-82.
 13. Turkoglu AR, Yener NP, Coban S, Guzelsoy M, Demirbas M, Demirci H. Changes in intraocular pressure and tear secretion in patients given 5 mg solifenacin for the treatment of overactive bladder. *International urogynecology journal*. 2017 May 1;28(5):777-81.