

## Original Research

### Incidence of Middle Mesial Canals Based On Distance between Mesial Canal Orifices in Mandibular Molars: Cone- Beam Computed Tomographic Analysis

Dr. Priti Mishra<sup>1</sup>, Dr. Yogesh Kumar Sahu<sup>2</sup>, Dr. Ravi Malik<sup>3</sup>, Dr. Abhishek Pal<sup>4</sup>, Dr. Shruti Sharma<sup>5</sup>, Dr. Rashmi Tamrakar<sup>6</sup>

1. Postgraduate Student, Department of Conservative and Endodontics, Maitri Dental College, Anjora, Durg, Chhattisgarh.
2. Professor, Department of Conservative and Endodontics, Maitri Dental College, Anjora, Durg, Chhattisgarh.
3. Consultant Prosthodontics & implantologists, Malik Dental Clinic and implant Centre, Raipur, Chhattisgarh.
4. Senior Lecturer, Department of Conservative and Endodontics, Maitri Dental College, Anjora, Durg, Chhattisgarh.
5. Senior Lecturer, Department of Conservative and Endodontics, Maitri Dental College, Anjora, Durg, Chhattisgarh.
6. Lecturer, Department of Conservative and Endodontics, Maitri Dental College, Anjora, Durg, Chhattisgarh.

#### ABSTRACT:

**Introduction:** This study evaluated the presence of midmesial canals (MMCs) in a random sample of mandibular molars and the relationship of the intracanal distance between mesiobuccal and mesiolingual canal orifices. **Methods:** fifty extracted mandibular molars were divided into sample of 5 teeth, mounted in modeling wax before cone beam computed tomographic imaging. The teeth and the CBCT images were interpreted for the presence of MMCs and the mesial intracanal distance. CBCT software measured the distance between the buccal of the MB canal to the lingual of the ML canal at the pulpal floor to determine the average length between the canals. **Results:** 8 distinct MMCs were seen on CBCT images (incidence of 16%). 20 had ambiguous broad isthmus between the MB and ML canal orifices. MMCs were present at the furcation level but merged with the MB and ML canal toward the apex in 6 of 8 teeth with distinct MMCs (87.5%). The mean distance between the MB and ML canals in teeth with MMCs was 3.4mm, and the mean distance was 3.6 mm for teeth without MMCs. The results of the independent sample t test showed no statistically significant difference in the mesial intracanal distance in teeth with and without MMCs ( $p>0.05$ ). **Conclusions:** The incidence of MMCs in mandibular molars appears consistent with the literature. However, there does not appear to be a statically significant difference in the mesial intracanal distance in teeth with and without MMCs. Visualization of MMCs on CBCTs may be subjective. There does not appear to be a co-relation between the presence of MMCs and an increased or decreased mesial intracanal distance.

**Key words:** Cone- beam computed tomography; mandibular molars; midmesial canal

Received: 12 September, 2020

Accepted: 12 November, 2020

**Corresponding Author:** Dr Priti Mishra, Postgraduate Student, Department of Conservative and Endodontics, Maitri Dental College, Anjora, Durg, Chhattisgarh.

**This article may be cited as:** Mishra P, Sahu YK, Malik R, Pal A, Sharma S, Tamrakar R. Incidence of Middle Mesial Canals Based On Distance between Mesial Canal Orifices in Mandibular Molars: Cone- Beam Computed Tomographic Analysis. J Adv Med Dent Res 2020;8(12):4-7.

## INTRODUCTION:

Successful endodontic treatment depends on the thorough debridement of the entire root canal system. Intricate root canal anatomy could be one of the causes of improper cleaning of the canal system. The improper cleaning of any portion of the canal system carries the risk of harboring microorganisms. A strong relationship exists between the existence of an untreated canal space and apical periodontitis.<sup>1</sup> Thus, it is imperative to understand the root canal anatomy to achieve the optimal endodontic treatment result possible. The complexity of the root canal system of mandibular first and second molars has been well-documented in the endodontic literature including the tendency for invagination of the distal aspect of the mesial root of mandibular molars, which necessitates conservative instrumentation to avoid potential for perforation.<sup>2-4</sup> The presence of an independent middle mesial canal (MMC) in mandibular molars was first reported by Vertucci and Williams<sup>2</sup> and Barker et al<sup>3</sup> in 1974. According to Pomeranz et al<sup>5</sup>, MMCs can be classified into 3 categories: fin, confluent, or independent. Fin is when an instrument can pass freely between the mesiobuccal (MB) or mesiolingual (ML) canal and the MMC. Confluent is when the MMC originates as a separate orifice but apically joins with the MB or ML canal, and independent is when the MMC originates as a separate orifice and terminates as a separate foramen. A broad single mesial canal in which 3 master cones could be cemented to the apex at the same time was also included as an independent MMC<sup>5</sup>. However, this classification does not explain the presence of a broad isthmus that can be found between the MB and ML canal orifices. Confirming the presence of distinct MMCs in mandibular molars, instead of grouping them together with broad isthmus, may help allow for more consistent analysis of mandibular molar anatomy, which will help in better treatment outcomes. Also, it is unclear whether the intracanal distance between mesial canals in mandibular molars can be used as a predictor for the presence or absence of a distinct MMC. The objectives of this study were to identify whether or not an MMC or broad isthmus is present between the MB and ML canal orifices in a random sample of mandibular molars, to correlate clinical findings with conebeam computed tomographic (CBCT) findings, and to correlate the difference between the intracanal distances between the MB and ML canal orifices when the middle mesial canal is present or absent.

## METHODS AND MATERIAL

A total of 50 extracted mandibular molars were randomly collected and divided into samples of 5 teeth, mounted in modeling wax and then immersed in water before taking each CBCT scan. The extracted

mandibular molars were blind samples; no information was provided about or could be determined regarding whether the teeth were from male or female patients, patients of specific ages. Permanent mandibular molars with calcified canals, single roots, or fused roots were excluded in this study. Permanent mandibular molars with complete root formation were included in the study. Access opening done using Endo Z bur, canal negotiated by using number 10 k file. Teeth were hemisected for better visualization. Hemisection (remove distal half) of the mandibular molars may have offered more precise evaluation of the true mesial root anatomy. Hemisection of mandibular molars is not commonly performed in a clinical environment, but the use of this method may be useful in confirming the true anatomy of mesial roots of mandibular molars in an expanded version of this study. However All CBCT images were taken on CBCT unit CS 9000 3D (Carestream ) with voxel size of 70  $\mu$ m and a field of view of 5\*5. Exposure parameters were 60–90 kVp and 2–15 mA. The CBCT images were viewed with CS 3-D imaging. The following criteria were evaluated: the distance between the buccal aspects of the MB canal to the lingual aspect of the ML canal at the pulpal floor was measured to determine the average distance in millimeters between the canals; in the axial view, an MMC was noted when a distinct radiolucent area was observed at the pulpal floor between the MB and ML canals and an isthmus was noted when a narrow ribbon-shaped communication was present between the MB and ML canals. All CBCT images were analyzed.

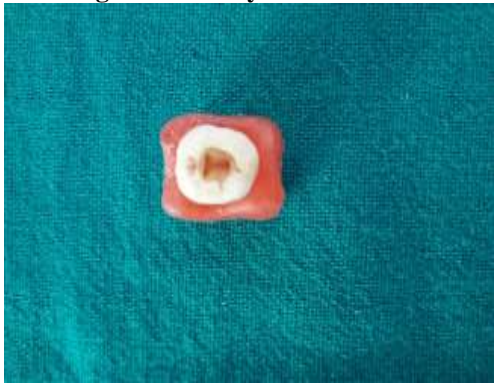## STATISTICAL ANALYSIS

The independent sample t test was used to assess the difference in the distance between MB and ML canals in the presence or absence of an MMC. The interexaminer reliability was tested on 10 randomly selected samples by interclass correlation coefficient using a 2-way mixed and absolute agreement model. CBCT volumes for interexaminer reliability after 6 weeks.

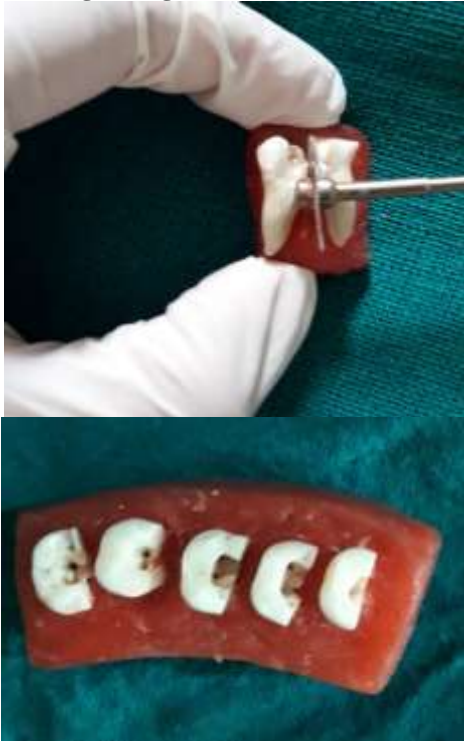## RESULTS

Fifty extracted mandibular mesial half, 8 showed distinct MMCs on CBCT imaging. 20 had ambiguous broad isthmus between the MB and ML canal orifices. MMCs were present at the furcation level but merged with the MB or ML canal toward the apex in 7 of 8 teeth with distinct MMCs (87.5%)(table-1). The mean distance between the MB and ML canals in teeth with MMCs was 3.4mm, and the mean distance was 3.6 mm for teeth without MMCs.(table-2) The results of the independent sample t test showed no statistically significant difference in the mesial intracanal distance in teeth with and without MMCs ( $p>0.05$ ).

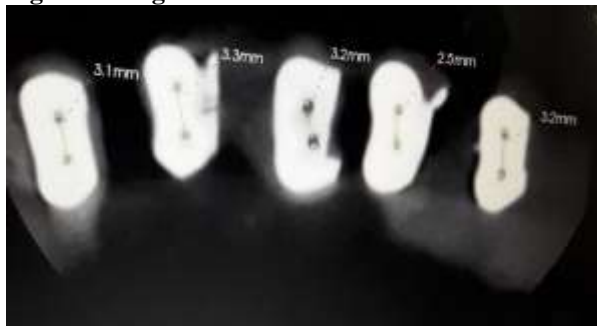
**Fig-1 showing access cavity**



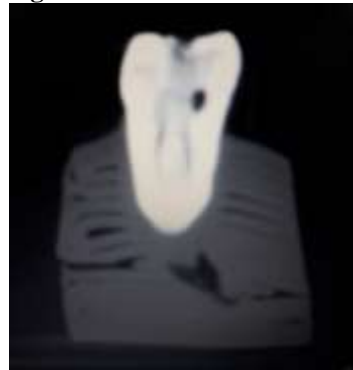
**Fig-2 showing slicing of tooth removal distal half**



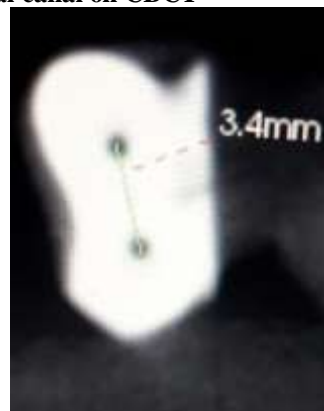
**Fig-3 showing axial view of mesial root on CBCT**



**Fig-4 showing coronal view of mesial root on CBCT**




**Fig-5 showing distance between mesiobuccal and mesiolingual canal on CBCT**



**Fig-6 showing 3-D view of model on CBCT**



**Fig-7 showing middle mesial canal on axial view on CBCT**



	Distinct	Broad isthmus	Merged with MB & ML
MMCs	8 (50)16%	20(50)40%	6(8) 87.5%

**MMCs, Middle Mesial Canal**

	mandibular 1st molars n=45		mandibular 2nd molars (n=5)	
with MMCs	3.4mm		3.5mm	
without MMCs	3.6mm		3.6mm	

**MMCs, Middle Mesial Canal**

## DISCUSSION

The variation of root canal anatomy of mandibular molars is well-documented in the literature. The presence of MMCs in mandibular molars is such a morphologic variation. The incidence of MMCs in lower molars ranges from approximately 0.95%<sup>7</sup> to 46.2%<sup>8</sup> depending on the study criteria. Azimet al<sup>8</sup> and Karapinar-Kazandag et al<sup>9</sup> suggested that the use of a dental operating microscope can improve the recognition and negotiation of accessory canals. In this study, the incidence of MMC was 16%(table-1) whereas the presence of an ambiguous isthmus was 40% on CBCT imaging. The reason for a lower incidence of MMCs in this study compared with the study of Azim et al<sup>8</sup> is the division of true MMCs from ambiguous isthmi. Overall, a total of 56% of the teeth used in this study either had a true MMC or broad isthmus between the MB and ML canal orifices. The distinct MMCs and broad isthmi could be visualized by using via CBCT imaging. The combined incidence of both MMCs and broad isthmi in this study was even greater than that found in the study of Azim et al<sup>8</sup>. CBCT imaging proved equally as helpful as the dental operating microscope in locating MMCs. The American Academy of Oral and Maxillofacial Radiology and the American Association of Endodontics published a joint position statement in 2015 that recommended the use of small/limited field of view to locate missed canals and evaluate root fracture in retreatment cases, root resorption, and apical periodontitis. In dental offices where dental operating microscopes are not available, CBCT imaging is a good alternative to visualize complex root canal morphology. Nevertheless, ALARA (as low as reasonably achievable) principles should be followed before any radiographic examination<sup>10</sup>. In the present study, the intracanal distance between the MB and ML canal orifices in mandibular molars was measured on axial and coronal views of CBCT imaging in the presence or absence of an MMC. The purpose of measuring the distance between the canals is to help the clinician detect the presence of an MMC before initiating endodontic treatment. The results of this study showed no statistically significant difference in the mesial intracanal distance in teeth with and without

MMCs. Unfortunately, based on the results of this study, the distance the between the MB and ML canals in mandibular molars cannot be used as a criterion to detect the presence of an MMC.

## CONCLUSION:

The presence of an untreated MMC or isthmus is a potentially important reason for endodontic treatment failure. CBCT imagings are effective in detecting the presence of accessory canals. This means that either or both types of technology can be used to detect MMCs. The intracanal distance between the MB and ML canals in mandibular molars cannot be used as a criterion to detect the presence or absence of an MMC.

## REFERENCES

1. Karabucak B, Bunes A, Chehoud C, et al. Prevalence of apical periodontitis in endodontically treated premolars and molars with untreated canal: a cone-beam computed tomography study. *J Endod* 2016;42:538–41.
2. Vertucci F, Williams R. Root canal anatomy of the mandibular first molar. *J N J Dent Assoc* 1974;48:27–8.
3. Barker BC, Parsons KC, Mills PR, Williams GL. Anatomy of root canals. Permanent mandibular molars. *Aust Dent J* 1974;19:408–13.
4. Hess W. The Anatomy of the Root Canals of the Teeth of the Permanent Dentition. Part I. New York, NY: William Wood & Co; 1925. p. 35–44.
5. Pomeranz HH, Eidelman DL, Goldberg MG. Treatment considerations of the middle mesial canal of mandibular first and second molars. *J Endod* 1981;7:565–8.
6. Schropp L, Alyass NS, Wenzel A, Stavropoulos A. Validity of wax and acrylic as soft-tissue simulation materials used in vitro radiographic studies. *Dentomaxillofac Radiol* 2012;41:686–90.
7. Shahi S, Yavari HR, Rahimi S, Torkamani R. Root canal morphology of human mandibular first permanent molars in an Iranian population. *J Dent Res Dent Clin Dent Prospects* 2008;2:20–3.
8. Azim AA, Deutsch AS, Solomon CS. Prevalence of middle mesial canals in mandibular molars after guided troughing under high magnification: an in vivo investigation. *J Endod* 2015;41:164–8.
9. Karapinar-Kazandag M, Basrani BR, Friedman BS. The operating microscope enhances detection and negotiation of accessory mesial canals in mandibular molars. *J Endod* 2010; 36:1289–94.
10. AAE and AAOMR Joint Position Statement. *J Endod* 2015; 30:1–7. JOE