

## CASE REPORT

### FOREIGN BODY EXTERNAL AUDITORY CANAL MASQUERADING AS AN OSTEOMA ON RADIO IMAGING: A CASE STUDY

Deepika Aggarwal<sup>1</sup>, Ruby Singh<sup>2</sup>

<sup>1</sup>Associate Professor, Dept of ENT, IQ City College and Hospital, Durgapur, <sup>2</sup>Department Of Paediatrics, Ex-Assistant Professor, CMC Ludhiana, Punjab


#### ABSTRACT:

We report a case of foreign body incidentally detected in external auditory canal, masquerading as an Osteoma on imaging. The case was an 11 year old boy who presented in paediatric OPD of a rural health centre with scalp swelling of 15 days duration and MRI which reported Osteoma in EAC. He manifested with no auditory symptoms in his daily life. Incidental finding on MRI necessitated Otorhinolaryngological consultation. Examination under microscope revealed a stone of about 7x5 mm which was removed under vision. Our objective is to emphasize the significance of meticulous clinical examination to achieve correct diagnosis and appropriate management.

**Key words:** Foreign body; external auditory canal; Osteoma; MRI

Corresponding author: Dr Deepika Aggarwal, Associate Professor, Dept Of ENT, IQ City College and Hospital, Durgapur.

This article may be cited as: Aggarwal D, Singh R. Foreign body external auditory canal masquerading as an osteoma on radio imaging: A case study. J Adv Med Dent Scie Res 2017;5(5):8-10.

Access this article online	
<p><b>Quick Response Code</b></p> 	Website: <a href="http://www.jamdsr.com">www.jamdsr.com</a>
	DOI: 10.21276/jamdsr.2017.5.5.2

## INTRODUCTION

All children seeking emergency department (ED) care for foreign bodies (FBs) in the external auditory canal (EAC) needs to be examined carefully under microscope. Although many FBs are successfully removed, the procedure is associated with potential complications because children have small EACs and frequently move during removal attempts.<sup>1</sup> In most situations, FBs are removed without serious consequences. There is limited information about FB removal in the pediatric ED. Most studies of ear FB removal are found in the otolaryngology literature, where referral to an ear, nose, and throat specialist is emphasized.<sup>1,2,7,8</sup> need for general anesthesia is emphasized and rates of operative removal have been reported to be as high as 30%.<sup>7,8</sup> We present here a case report of foreign body external auditory canal masquerading as an osteoma on radio imaging.

## CASE REPORT

Eleven Year old boy presented in paediatric OPD of rural health centre with the chief complaint of scalp swelling since 1 month. It was associated with fever. Patient gave a history of head injury following which the swelling developed. He took medications from a local doctor but had no relief. There was no other history suggestive of cerebral compromise.

On local examination, a soft tissue swelling of approximately 4 x 3 cm was seen on right high parietal region. The swelling was soft, fluctuant and tender. Skin over the swelling was warm and scabbing was present. On general examination: Patient was conscious, cooperative and oriented.

- BP: 100/60,
- Pulse: 80/ min,
- Temp: 98.6 F

#### Hematological investigations:

- HB- 10 gms/dl
- TLC : 7400 x 10<sup>3</sup> /microL
- Platelets: 1,92,000 /microL
- ESR: 10mm in 1st hour
- Neutrophils: 54%
- Eosinophils: 2%
- Lymphocytes: 44%
- Bleeding Time: 2'35''
- Clotting Time- 5'50''
- RBS- 95 mg/dl

**MRI Findings:** It revealed a soft tissue scalp swelling seen on right parietal region. Underlying bone was found intact. A high density well defined lesion 7 x 5 mm (CT attenuation of 2000 HU) was seen in right external auditory canal query Osteoma/

Osteochondroma. There was no evidence of intraparenchymal injury/extraxial haematoma or subarachnoidhemorrhage. No fracture was seen. Incidental finding on MRI necessitated Otorhinological consultation. Patient was examined under microscope which revealed foreign body in right external auditory canal. Foreign body was removed under vision using foreign body removal hook. Tympanic membrane was found normal and intact. There was no injury to the external auditory canal. Foreign body size was approx 7 x 5 mm. Patient was started on oral antibiotics and analgesics for scalp swelling.

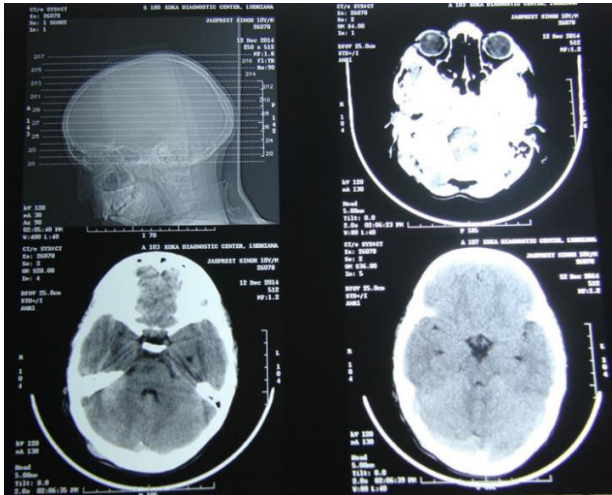


Figure 1: MRI findings

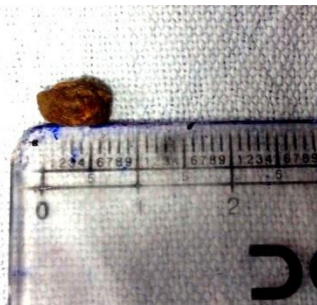

Figure 2: Gross biopsy findings

## DISCUSSION

External auditory canal foreign bodies are most commonly seen in children under 7. Children with conditions that cause irritation of the ear such as otitis media or cerumen impaction are at higher risk. Additional risk factors include pica and ADHD. Most often, the foreign body is on the right side due to the handedness of the child. The most common foreign bodies found in the external auditory canal include beads, pebbles, pieces of paper, toys, popcorn kernels and insects.

Frequently, foreign bodies of the external auditory canal are asymptomatic and found during routine otoscopy. However, they may cause impaired hearing, pain, purulent or bloody drainage from the ear or chronic cough/hiccups (which is rare).

Timing of removal is dependent upon the type of foreign body. Button batteries should be removed immediately, as the electrical current from the battery can cause destruction of the ear canal skin, tympanic membrane, facial nerve and ossicles. They also cause local pressure necrosis. Insects should be removed urgently because they can cause damage to the tympanic membrane and middle ear as the insects move in the canal. Foreign bodies that can penetrate the tympanic membrane and cause damage to middle ear structures should also be evaluated immediately. Such foreign bodies include cotton applicator tips, pencil points, hair pins. A patient with a penetrating foreign body who exhibits vertigo, ataxia, facial nerve damage, or hearing impairment should be urgently evaluated by an otolaryngologist.

## Techniques for removal are

1. **Irrigation:** Can be used for small, inorganic items. Contraindicated in patients with PE tubes or with perforated tympanic membranes. Should not be used to remove vegetable matter or button batteries. Organic matter may swell with water, which leads to further obstruction. Using water with button batteries increases risk of chemical injury. The patient should be in the supine position with affected ear up. Irrigate with body temperature water until foreign body is expelled. It may still require instrumentation to grasp the foreign body if it reaches the auditory meatus but is not expelled.

2. **Instrumentation:** Commonly used instruments for foreign body removal include an ear speculum, forceps, or curettes. The use of instrumentation can be painful and may be difficult in patients who are unable to remain still for the procedure. Soft objects with irregular edges typically can be grasped with forceps. Round objects are often removed by extending an instrument such as a curette beyond the object then slowly withdrawing it from the ear canal

Live insects should be killed with mineral oil or 1% lidocaine prior to removal to prevent insect movement during removal. Mineral oil is preferred because though both kill the insect, lidocaine may cause it to writhe and squirm which is, needless to say, uncomfortable for the patient.

## Complications

Common complications include laceration or abrasion of the ear canal, which occurs in up to 50% of patients. Additionally, patients are at risk for tympanic membrane perforation and middle ear damage during removal.

A study by Thompson, Wein and Dutcher<sup>1</sup> in 2003 looked at patients presenting to an emergency department over a 3 year period with a chief complaint of external auditory canal foreign body. Of the 162 patients seen with this chief complaint, about 33% required ENT referral, 81% of them after unsuccessful removal attempt in the ED. They found that ED removal was successful for irregularly shaped, soft objects with

easily graspable parts such as paper, small toys and insects. Firm, smooth and round objects such as beads, beans, stones and popcorn kernels were more likely to require ENT referral. A wide variety of removal techniques were used in the ED including irrigation, forceps, suction and curette. Overall complication rate was about 1% with 2 patients developing tympanic membrane perforation after multiple attempts at foreign body removal ultimately requiring removal by an ENT. Another study by Marin and Trainor<sup>2</sup> examined the medical records of patients presenting to a pediatric emergency department with a chief complaint of "foreign body in the ear" between November 1998 and October 2003. In this study, there were 254 foreign body removal attempts in 250 children over 5 years. About 80% of foreign bodies were successfully removed in the ED using a variety of different techniques. Twenty percent of cases were referred to ENT, and 6% required removal in the OR. Complications included canal bleeding and/or laceration in 29 patients. One patient developed a perforation of the tympanic membrane with ossicle damage. Risk of complications increased as number of attempts at removal increased as well as the number of instruments used for removal increased.

Osteomas are considered bony neoplasms that show a predilection for the external auditory canal (EAC), mastoid cortex, facial bones, and mandible. Osteomas of the EAC are considered benign tumors as they are non-invasive; however, they can cause significant symptoms due to mass effect and auditory canal obstruction.<sup>6</sup> Over the last several decades, there has been an ongoing debate over distinguishing osteoma from exostosis of the external auditory canal. Indolent by nature, both osteomata and exostoses of the EAC are often found incidentally. Of the two entities, exostosis is much more common with a reported incidence of 0.6% and occurring more frequently in middle aged men.<sup>7-9</sup> While chronic irritation such as cold water exposure and repeated otitis externa are directly correlated with the development of exostosis, a clear aetiology of osteoma of the EAC has yet to be discerned.

We present here a case report of foreign body external auditory canal masquerading as an osteoma on radio imaging. In the present case report, an eleven year old boy presented in paediatric OPD of rural health centre with the chief complaint of scalp swelling since 1 month with was associated with fever. MRI Head revealed a soft tissue scalp swelling seen on right parietal region. Incidental finding on MRI necessitated Otorhinological consultation. Differential diagnosis of Osteoma and Osteochondroma was given. Microscope examination revealed foreign body in right external auditory canal. Which was removed by otolaryngologist using microscopy.

Above case potentiated the need of good clinical examination for proper diagnosis and treatment, which usually is often overlooked due to clinical work overload in emergency departments.

## CONCLUSION

Foreignbodies in EAC is a common emergency seen in pediatrics OPD. Asymptomatic FBs are often missed in clinical examination and may remain therefor days. Similarly osteoma of the external auditory canal are often asymptomatic due to the indolent nature and the lesions are found incidentally during unrelated evaluations. Similar appearance on radioimaging of both the above said entities might create a diagnostic dilemma, if not examined carefully. Therefore a meticulous clinical examination is a reasonable approach saving a lot of time, money and appropriate treatment of the disease.

## REFERNCES

1. Marin Marin J, Trainor J. Foreign Body Removal from the External Auditory Canal in a Pediatric Emergency Department. *Pediatric Emergency Care* 2006;22(9):630-634.
2. Thompson SK, Wein RO, Dutcher PO. External Auditory Canal Foreign Body Removal: Management Practices and Outcomes. *Laryngoscope* 2003;113:1912-1915
3. Liétin B, et al. Osteoma of the internal auditory canal. *European annals or otorhinolaryngology. Head Neck Dis.* 2010;127:15-19.
4. Orita Y, et al. Osteoma with cholesteatoma in the external auditory canal: case report. *Int J Pediatr Otorhinolaryngol.* 1998;43:289-293.
5. Venelin G, et al. Bilateral osteomas arising from the internal auditory canal: case report. *Neurosurgery.* 2008;62:E528-E529.
6. Denia A, et al. Extracanalicular Osteomas of the Temporal Bone. *Arch Otolaryngol.* 1979;105:706-709.
7. DiMuzio J, Deschler DG. Emergency department management of foreign bodies of the external auditory canal in children. *OtolNeurotol.* 2002; 23:473-475.
8. Schulze S, Kerschner J, Beste D. Pediatric external auditory canal foreign bodies: a review of 698 cases. *OtolaryngolHead Neck Surg.* 2002;127:73-78.
9. Balbani APS, Sanchez TG, Butugan O, et al. Ear and nose foreign body removal in children. *Int J PediatrOtorhinolaryngol.* 1998;46:37-42.
10. Bressler K, Shelton C. Ear foreign-body removal: a review of 98 consecutive cases. *Laryngoscope.* 1993;103:367-370.
11. Mackle T, Conlon B. Foreign bodies of the nose and ears in children. Should these be managed in the accident and emergency setting? *Int J PediatrOtorhinolaryngol.* 2006;70:425-428.

**Source of support:** Nil

**Conflict of interest:** None declared

This work is licensed under CC BY: *Creative Commons Attribution 3.0 License.*