(e) ISSN Online: 2321-9599

(p) ISSN Print: 2348-6805

Index Copernicus value = 76.77

# ORIGINAL ARTICLE

# Comparison of over underlay graft technique with conventional underlay myringoplasty in patients with mucosal chronic suppurative otitis media

[1]Dr Anushri Bajaj, [2]Dr Shahnaz Sheikh, [3]Dr Vikrant Vaze, [4]Dr Balchandra Paikay

[1]Associate professor, [2,3]Senior resident, [4]HOD

[1-4]Department of ENT, Dr. Ulhas Patil Medical College & Hospital, Jalgaon, Maharashtra, India

***ABSTRACT:***

**Background:** Chronic suppurative otitis media (CSOM) is an inflammatory process of the mucoperiosteal lining of the middle ear space and mastoid. The present study compared over underlay graft technique with conventional underlay myringoplasty in patients with mucosal CSOM. **Materials & Methods:** 84 patients diagnosed with chronic suppurative otitis media of both genders were divided into 2 groups of 42 each. Group I patients were operated by conventional underlay myringoplasty and group II patients were operated by over-underlay myringoplasty. Parameters such as status of graft, size of perforation, degree of hearing loss etc. was compared in both groups. **Results:** Group I had 28 males and 16 females and group II had 20 males and 22 females. The site of perforation was grade IV seen in 12 in group I and 10 in group II and V 30 in group I and 32 in group II. Degree of hearing loss was mild seen in 34 in group I and 30 in group II, moderate 8 in group I and 12 in group II, air born gap pre-op was 34.2 dB in group I and 38.6 dB in group II and post- op was 19.6 dB in group I and 19.7 dB in group II. Graft status was graft taken up in 40 in group and 41in group II and graft failure was 2 in group I and 1in group II. The difference was significant (P< 0.05). **Conclusion:** Over-underlay technique has advantages of graft uptake rate and found to be better than conventional underlay myringoplasty.

**Key words:** Chronic suppurative otitis media, conventional underlay myringoplasty, Over-underlay technique

**Corresponding Author:** Dr Shahnaz Sheikh, Senior resident, Department of ENT, Dr. Ulhas Patil Medical College & Hospital, Jalgaon, Maharashtra, India

**This article may be cited as:** Bajaj A, Sheikh S, Vaze V, Paikay B. Comparison of over underlay graft technique with conventional underlay myringoplasty in patients with mucosal chronic suppurative otitis media. J Adv Med Dent Scie Res 2017;5(5):-109-111.

## INTRODUCTION

Chronic suppurative otitis media (CSOM) is an inflammatory process of the mucoperiosteal lining of the middle ear space and mastoid.[1] Infection of the middle ear has been a problem encountered in the human race and is as old as humanity itself.[2] Myringoplasty is the term used to describe the surgical repair of a perforated tympanic membrane and is the most to evaluate and compare the results of over-underlay graft technique with conventional underlay myringoplasty an adequate area of contact between the graft and tympanic membrane remnant is fundamental to the successful closure of any perforation. Graft failure is considerably higher in anterior perforation, large perforation, and more so by the dexterity of graft placement.[3]

There are two established techniques of myringoplasty, overlay technique and underlay technique. In overlay technique we place the graft lateral to the fibrous layer of the tympanic membrane.[4] In underlay technique we place the graft medial to the tympanic membrane remnant. Underlay technique is the most common and time tested technique, is typically used for posterior perforations, whereas the overlay technique is more technically challenging and particularly suited for anterior large or subtotal perforations.[5] Although overlay technique has higher success rate for the reconstruction of anterior large or subtotal tympanic membrane perforation, it's more challenging and demands surgeons skill and serious complications including anterior angle blunting, graft lateralization, epithelial pearls and delayed healing may occur.[6] The present study compared over-underlay graft technique with conventional underlay myringoplasty in patients with mucosal CSOM.

## MATERIALS & METHODS

The present study comprised of 84 patients diagnosed with Chronic suppurative otitis media of both genders. All were informed regarding the study and their written consent was obtained.

Data such as name, age, gender etc. was recorded. Patients were divided into 2 groups of 42 each. Group I patients were operated by conventional underlay myringoplasty and group II patients were operated by over-underlay myringoplasty. Parameters such as status of graft, size of perforation, degree of hearing loss etc. was compared in both groups.

Results thus obtained were subjected to statistical analysis. P value less than 0.05 was considered significant.

## RESULTS

**Table I Distribution of patients**

| Groups | Group I | Group II |
|---|---|---|
| Method | Conventional underlay myringoplasty | Over underlay myringoplasty |
| M:F | 28:16 | 20:22 |

Table I shows that group I had 28 males and 16 females and group II had 20 males and 22 females.

**Table II Comparison of parameters**

| Parameters | Variables | Group I | Group II | P value |
|---|---|---|---|---|
| Site of perforation | Grade I | 0 | 0 | 0.01 |
| | II | 0 | 0 | |
| | III | 0 | 0 | |
| | IV | 12 | 10 | |
| | V | 30 | 32 | |
| Degree of hearing loss | Mild | 34 | 30 | 0.02 |
| | Moderate | 8 | 12 | |
| | Moderately severe | 0 | 0 | |
| | Severe | 0 | 0 | |
| Air born gap | Pre- op | 34.2 | 38.6 | 0.02 |
| | Post- op | 19.6 | 19.7 | |
| Graft status | Graft taken up | 40 | 41 | 0.05 |
| | Graft failure | 2 | 1 | |

Table II, graph I shows that site of perforation was grade IV seen in 12 in group I and 10 in group II and V 30 in group I and 32 in group II. Degree of hearing loss was mild seen in 34 in group I and 30 in group II, moderate 8 in group I and 12 in group II, air born gap Pre-op was 34.2 dB in group I and 38.6 dB in group II and post- op was 19.6 dB in group I and 19.7 dB in group II. Graft status was graft taken up in 40 in group and 41in group II and graft failure was 2 in group I and 1in group II. The difference was significant (P< 0.05).

**Graph I Comparison of parameters**

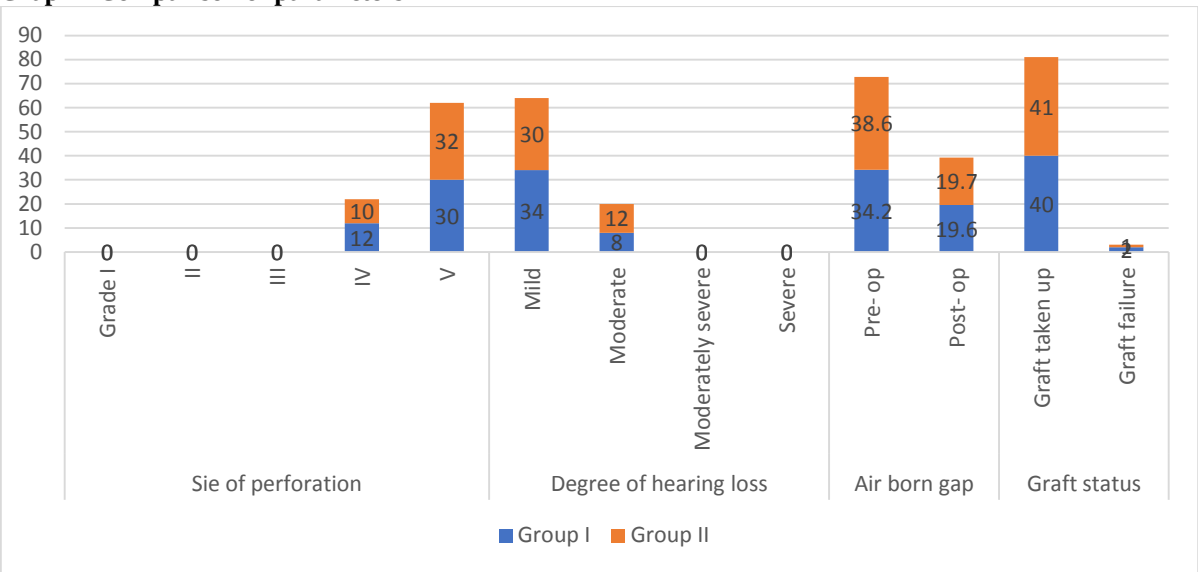


## DISCUSSION

Myringoplasty is the operative procedure performed to repair the tympanic membrane perforation and to improve hearing level.[7] The graft success rate depends on various factors such as the size of the perforation, functioning of eustachian tube, graft placement techniques, the experience of the operating surgeon etc. There is marked diversity noted in achieving an intact tympanic membrane following myringoplasty.[8] It is often reported that repair of anterior and subtotal perforation by conventional underlay technique is less successful when compared to small perforation because it is technically more difficult.[9] The present study compared over-underlay graft technique with

conventional underlay myringoplasty in patients with mucosal CSOM.

In present study, group I had 28 males and 16 females and group II had 20 males and 22 females. Panchal et al[10] evaluated the efficacy of over-underlay graft technique of myringoplasty and compare the results of over-underlay graft technique with conventional underlay myringoplasty. Twenty patients underwent conventional underlay myringoplasty and 20 patients underwent over-underlay myringoplasty. The follow-up period was 3 months. Graft uptake and hearing improvement was comparable in both groups. Although the graft uptake was 5% lower in the group which underwent conventional underlay myringoplasty (90%) as compared to over-underlay myringoplasty (95%), however, the difference was not statistically significant (P = 0.5). However, there was statistically significant difference in gain in hearing threshold (gain in A-B gap) in the conventional underlay myringoplasty (14.5 dB ± 7.236) as compared to over-underlay myringoplasty (18.75 dB ± 5.349) (P = 0.04).

We found that site of perforation was grade IV seen in 12 in group I and 10 in group II and V 30 in group I and 32 in group II. Degree of hearing loss was mild seen in 34 in group I and 30 in group II, moderate 8 in group I and 12 in group II, air born gap Pre-op was 34.2 dB in group I and 38.6 dB in group II and post-op was 19.6 dB in group I and 19.7 dB in group II. Graft status was graft taken up in 40 in group and 41in group II and graft failure was 2 in group I and 1in group II. Murugendrappa et al[11]compared the two different techniques of myringoplasty- circumferential subannular grafting technique and conventional underlay technique in cases of chronic otitis media with inactive mucosal disease. A total of 50 cases are included in this study, out of which 21 were males and 29 were females with male to female ratio of 0.72:1. The success rate of graft take up by circumferential subannular grafting technique is 96% and by conventional underlay technique is 76% respectively. In circumferential subannular grafting technique, the pre-op mean PTA was 36.92db, and the post-op mean PTA after 3 months was 25.87 db with a mean difference in PTA (dB) was 11.05 with t value of 7.74. In case of conventional underlay technique, the pre-op mean PTA was 38.24 db, and the post-op mean PTA after 3 months was 30.28 db with a mean difference in PTA (dB) was 7.96 with t-value of 14.39.

Kartush et al[12] coined the term over-underlay technique to emphasize that the graft was placed over the handle of malleus but under the residual drum and annulus. They reported on 120 patients who underwent over-underlay tympanoplasty between 1993 and 1999. The average follow-up period was 1.8 years (range: 6 months–6.5 years). Their group of patients included 81 (67.5%) patients with cholesteatoma. Fifty-four patients (45%) underwent intact canal mastoidectomy, 19 (15.8%) had a canal wall down mastoidectomy, 25 (20.8%) had endaural atticotomies, and only 22 (18.3%) had no mastoidectomy. All 120 patients had a full take-up of the graft at 6 months follow-up. However, the authors reported delayed tympanic problems such as atelectasis in 17 cases and perforation in 12 cases. There was no recurrence of cholesteatoma apart from small epithelial pearls on tympanic membrane in three children, which were removed easily.

## CONCLUSION

Authors found that the over-underlay technique has advantages of graft uptake rate and found to be better than conventional underlay myringoplasty.

## REFERENCES


1. Gopen Q. Pathology and clinical course of inflammatory disease of the middle ear. In: Gulya AJ, Minor LB, Poe DS, editors. Glasscock – Shambaugh Surgery of the Ear 6th ed. Shelton: Peoples Medical Publishing House-USA; 2010. p. 425-36.
2. Piédrola Maroto D, Escalona Gutiérrez JJ, Conde Jiménez M, Casado Morente JC, Povedano Rodríguez V, Benítez-Parejo N. Functional results in myringoplasties. Acta Otorrinolaringol Esp 2010;61:94-9.
3. Packer P, Mackendrick A, Solar M. Whats best in myringoplasty: Underlay or overlay, dura or fascia? J Laryngol Otol 1982;96:25-41.
4. Weider DJ. Use of William's microclips in various aspect of tympanoplastic surgery. Laryngoscope 1981;91:2106-25.
5. Farrior JB. Sandwich graft tympanoplasty: Experience, results, and complications. Laryngoscope 1989;99:213-7.
6. Lee HY, Auo HJ, Kang JM. Loop overlay tympanoplasty for anterior or subtotal perforations. Auris Nasus Larynx 2010;37:162-6.
7. Lerut B, Pfammatter A, Moons J, Linder T. Functional correlations of tympanic membrane perforation size. Otol Neurotol 2012;33:379-86.
8. Schuknecht HF. Myringoplasty. Clin Otolaryngol Allied Sci 1976;1:53-65.
9. Stage J, Bak-Pederson K. Underlay tympanoplasty with the graft lateral to the malleus handle. Otolaryngol Clin North Am 1992;17:6-9.
10. Panchal V, Gulia JS, Yadav SP, Hernot S, Kathuria B, Kaintura M. To evaluate and compare the results of over-underlay graft technique with conventional underlay myringoplasty. Indian J Otol 2015;21:274-9.
11. Murugendrappa MA, Siddappa PN, Shambulingegowda A, Basavaraj GP. Comparative study of two different myringoplasty techniques in mucosal type of chronic otitis media. Journal of clinical and diagnostic research: JCDR. 2016 Feb;10(2):MC01.
12. Kartush JM, Michaelides EM, Becvarovski Z, LaRouere MJ. Over-under tympanoplasty. Laryngoscope 2002;112:802-7.