

## Journal of Advanced Medical and Dental Sciences Research

@Society of Scientific Research and Studies

Journal home page: [www.jamdsr.com](http://www.jamdsr.com)

doi: 10.21276/jamdsr

(e) ISSN Online: 2321-9599;

(p) ISSN Print: 2348-6805

### Original Research

#### Evaluation of placental histology after maternal trauma

Adreena<sup>1</sup>, Pradeep Kumar<sup>2</sup>

<sup>1</sup>Assistant Professor, Dept of Pathology, Sakshi Medical College, Guna, Madhya Pradesh, India;

<sup>2</sup>Assistant Professor, Dept of Pediatrics, School of Medical Sciences and Research, Sharda University, Greater Noida, U.P., India;

#### ABSTRACT:

**Background:** Trauma in pregnancy occurs in approximately 7% of all pregnant women in industrialized countries. The present study was conducted to evaluate placental histology after maternal trauma in pregnancy.

**Materials & Methods:** The present study was conducted on 67 Placentas from women exposed to maternal trauma 20 weeks' gestational age. Serial fetal and neonatal brain imaging by means of ultrasound and magnetic resonance imaging (MRI) as well as histological examination of the placenta and a neurological follow-up of the infant until 5 years of age were performed.

**Results:** Gestational age at delivery was 39.2 weeks, mode of delivery was vaginal in 56 and cesarean in 11 and pre term birth was evident in 4. Umbilical cord knots was seen in 2, diameter was 1.2 cm, coiling index was 0.76 cm, maternal vascular malperfusion was seen in 34, accelerated villous maturation was seen in 28, retroplacental hematoma was seen in 51 and thrombus fetal chorionic plate was seen in 42 cases. The reason of trauma was fall in 34, domestic violence in 17 and road traffic accident in 16 cases.

**Conclusion:** Authors found that placenta histology may depict wide range of findings.

**Key words:** Gestational, Placenta, umbilical cord knots

Received: 27 October 2017

Revised: 28 November 2017

Accepted: 18 December 2017

**Corresponding author:** Dr. Pradeep Kumar, Assistant Professor, Dept of Pediatrics, School of Medical Sciences and Research, Sharda University, Greater Noida, U.P., India;

**This article may be cited as:** Adreena, Kumar P. Evaluation of placental histology after maternal trauma. J Adv Med Dent Scie Res 2018;6(2):114-117.

#### INTRODUCTION

Trauma in pregnancy occurs in approximately 7% of all pregnant women in industrialized countries. Minor and major trauma has been reported to cause fetal brain damage. The prevalence of fetal brain injury with consequences for later neurological outcome after maternal trauma, however, is not yet known.<sup>1</sup> Fetal brain injury after mechanical maternal trauma can be elicited by direct injury to the fetal head or indirectly via (partial) placental abruption<sup>2</sup> or fetomaternal hemorrhage. Fetal death has been reported after complete placental abruption following maternal trauma.<sup>2</sup>

Pregnancy imposes significant physiologic demands that may confuse and complicate the evaluation,

resuscitation, and definitive management of pregnant women who sustain trauma. Accurate prediction of fetal outcome after trauma remains elusive. Occurrence of trauma in pregnancy occurs in upto 7% of all pregnancies. The number is still underestimated as many pregnancies are undiagnosed in first trimester.<sup>3</sup> The incidence is maximum in third trimester. Motor vehicle crashes are the major cause of maternal trauma during pregnancy accounting for 55% of trauma followed by falls (22%), assaults (22%) and burns (1%). Trauma accounts for 6 to 75% of deaths in pregnant females. The leading cause of mortality in these is head injury and haemorrhagic shock. Obstetric trauma has been associated with risk factors such as young age, alcohol use, drug use and domestic violence. Some

studies have found pregnancy to be itself a risk factor for trauma.<sup>4</sup> The present study was conducted to evaluate placental histology after maternal trauma in pregnancy.

**MATERIALS & METHODS**

The present study was conducted in the department of General pathology & Pediatrics. It comprised of 67 Placentas from women exposed to maternal trauma 20

weeks’ gestational age. Ethical clearance was taken from institute ethical committee.

Data such as name, age, gender etc. was recorded. Serial fetal and neonatal brain imaging by means of ultrasound and magnetic resonance imaging (MRI) as well as histological examination of the placenta and a neurological follow-up of the infant until 5 years of age were performed. Results thus obtained were subjected to statistical analysis. P value less than 0.05 was considered significant.

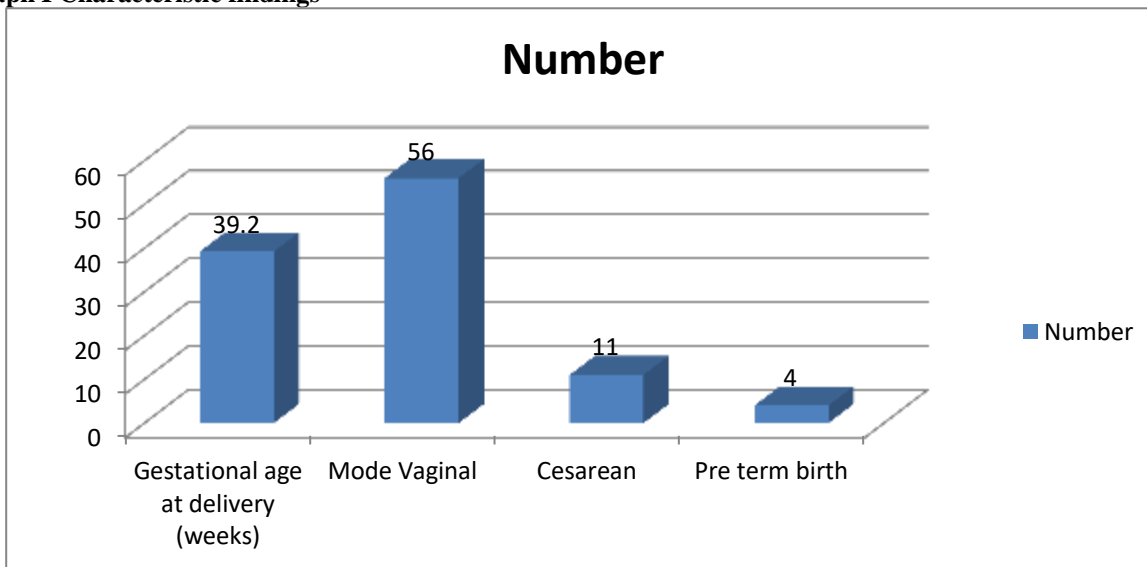
**RESULTS**

**Table I Characteristic findings**

Findings	Number
Gestational age at delivery (weeks)	39.2
Mode Vaginal	56
Cesarean	11
Pre term birth	4

Table I, graph I shows that gestational age at delivery was 39.2 weeks, mode of delivery was vaginal in 56 and cesarean in 11 and pre term birth was evident in 4.

**Graph I Characteristic findings**

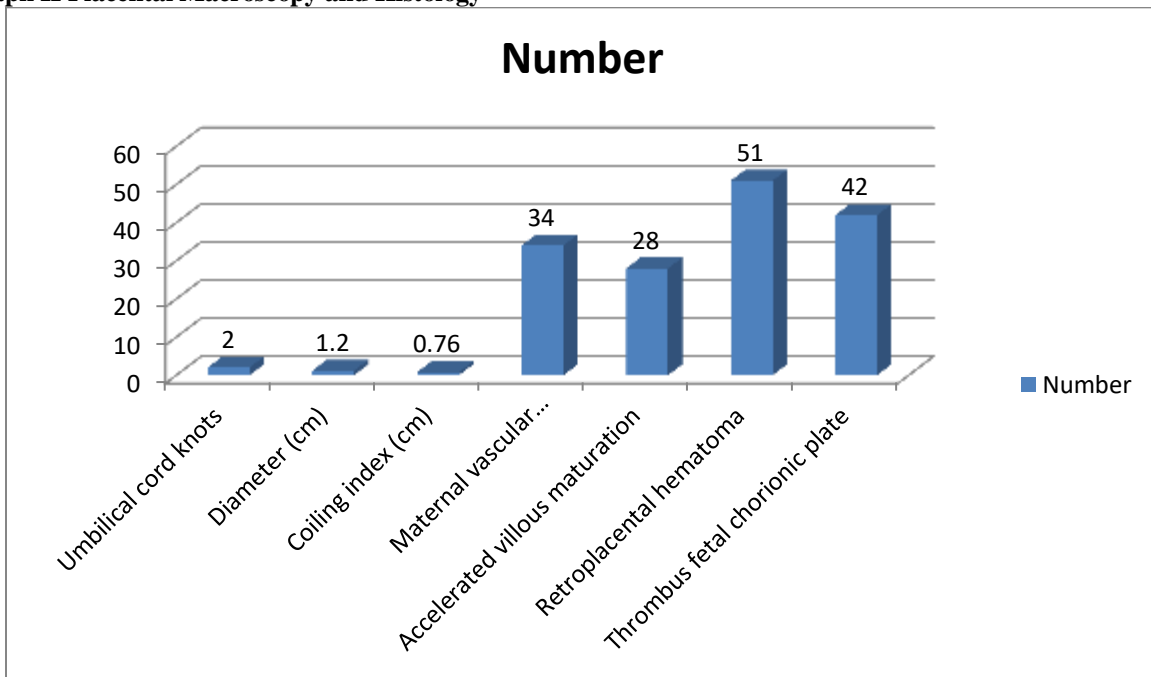


**Table II Placental Macroscopy and Histology**

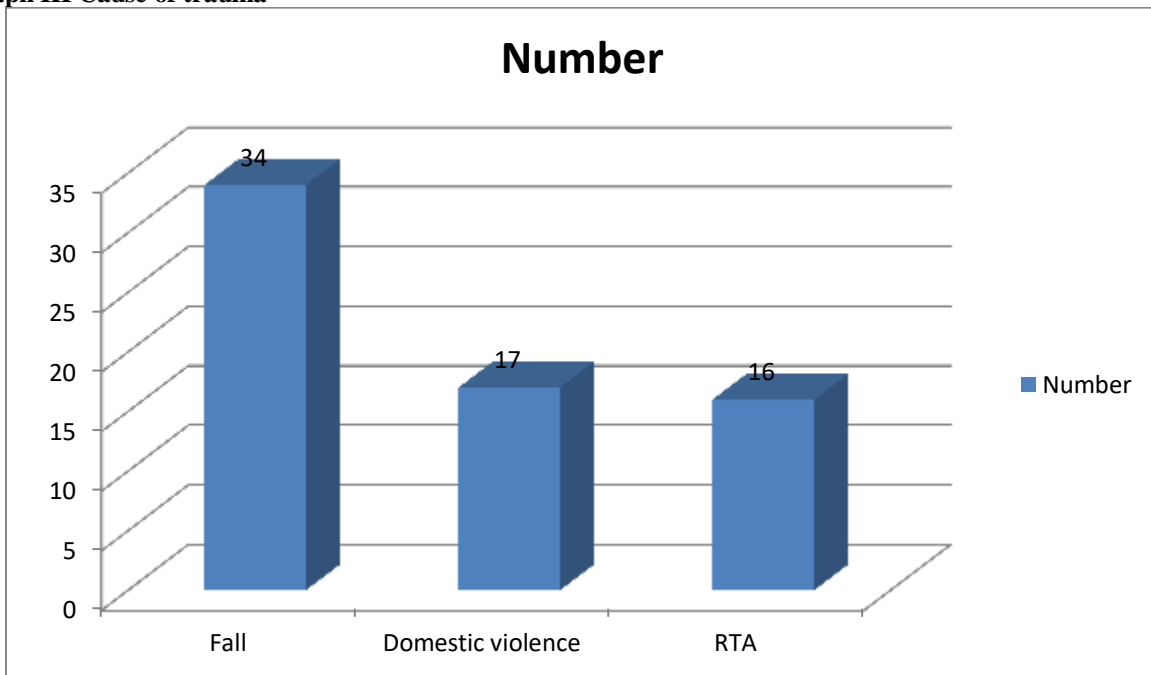
Findings	Number	P value
Umbilical cord knots	2	0.01
Diameter (cm)	1.2	
Coiling index (cm)	0.76	
Maternal vascular malperfusion	34	
Accelerated villous maturation	28	
Retroplacental hematoma	51	
Thrombus fetal chorionic plate	42	

Table II, graph II shows that umbilical cord knots was seen in 2, diameter was 1.2 cm, coiling index was 0.76 cm, maternal vascular malperfusion was seen in 34, accelerated villous maturation was seen in 28, retroplacental hematoma was seen in 51 and thrombus fetal chorionic plate was seen in 42 cases.

**Graph II Placental Macroscopy and Histology**



**Graph III Cause of trauma**



Graph III shows that reason of trauma was fall in 34, domestic violence in 17 and road traffic accident in 16 cases.

**DISCUSSION**

Foetal death in first trimester is related to maternal hypotension leading to uterine hypoperfusion. Deaths in the next two trimesters are due to direct trauma to the uterus. 11% of the foetal deaths are due to maternal

deaths.<sup>5</sup> 82% are related to motor vehicle accidents, while rest are accountable to firearm injuries and falls (6 & 3 %). Foetal deaths has been amounted as 60 % in major trauma to pregnant female and is as high as 80% in presence of maternal shock.<sup>6</sup>

Mother not only provides nutrition to the foetus but also protects the foetus by the amniotic fluid and the thick walled uterus around it. Studies have reported preterm labour, low birth weight, foetal distress and foetal death in pregnant females sustaining even minor injuries. Patients in third trimester are at risk of early labour, placental abruption, amniotic rupture, and foetal-maternal blood transfusion. Among the causes placental abruption is the leading cause of foetal death and accounts for upto 60 to 70 % foetal losses after the pregnant female sustains severe injury.<sup>7,8</sup> The present study was conducted to evaluate placental histology after maternal trauma in pregnancy.

In this study, gestational age at delivery was 39.2 weeks, mode of delivery was vaginal in 56 and cesarean in 11 and pre term birth was evident in 4. Klinich et al<sup>9</sup> found that placentas from women exposed to maternal trauma 20 weeks' gestational age were histologically examined. Neurological follow-up of the infants was performed at 1 year of age by means of Alberta Infant Motor Scale. Histological findings were compared to placentas from pregnancies without trauma. Thirteen placentas were investigated in the trauma group. The control group consisted of 15 placentas. Placental pathology was seen more often in the trauma cases (11 of the 13) than in the controls (6 of the 15),  $P = 0.024$ . Neurological follow-up was normal. In this small population, majority of the placentas showed pathology after minor trauma in pregnancy without consequences for neurodevelopment at 1 year.

We found that umbilical cord knots was seen in 2, diameter was 1.2 cm, coiling index was 0.76 cm, maternal vascular malperfusion was seen in 34, accelerated villous maturation was seen in 28, retroplacental hematoma was seen in 51 and thrombus fetal chorionic plate was seen in 42 cases. Pregnancy causes physiologic changes, so even normal appearing tests may actually be abnormal in pregnant patients. The normal pregnant patients hyperventilate and maintain an end tidal CO<sub>2</sub> lower than the normal values, thus a value in the normal range is actually alarming and a sign of hypoventilation and impending respiratory failure in pregnant trauma patients. There is diminished respiratory reserve making hypoventilation less tolerated. Increase in plasma volume, so patient

might have lost a significant amount of blood before any signs of hypovolemia appear. The baseline heart rate is higher (by 10 to 15 beats per minute) and blood pressure is lower than the normal particularly in second trimester in these patients making diagnosis of hypovolemia even difficult. Bleeding may be internal like in concealed placental abruption making decision to resuscitate difficult especially in view of delayed signs of hypovolemia.<sup>10</sup>

## CONCLUSION

Authors found that placenta histology may depict wide range of findings.

## REFERENCES

1. Connolly AM, Katz VL, Bash KL, McMahon MJ, Hansen WF. Trauma and pregnancy. *Am J Perinatol* 1997; 14: 331-336.
2. El-Kady D, Gilbert WM, Anderson J, Danielsen B, Towner D, et al. Trauma during pregnancy: an analysis of maternal and fetal outcomes in a large population. *Am J Obstet Gynecol* 2004; 190: 1661-1668.
3. Stewart DE, Cecutti A. Physical abuse in pregnancy. *CMAJ* 1993; 149: 1257-1263.
4. Helton AS, McFarlane J, Anderson ET. Battered and pregnant: A prevalence study. *Am J Public Health* 1987; 77: 1337-1339.
5. McFarlane J, Parker B, Soeken K, Bullock L. Assessing for abuse during pregnancy. Severity and frequency of injuries and associated entry into prenatal care. *JAMA* 1992; 267: 3176-3178.
6. Weiss HB. Pregnancy-associated injury hospitalizations in Pennsylvania, 1995. *Ann Emerg Med* 1999; 34: 626-636.
7. Hayes B, Ryan S, Stephenson JB, King MD. Cerebral palsy after maternal trauma in pregnancy. *Dev Med Child Neurol*. 2007;49(9):700-706.
8. Goodwin TM, Breen MT. Pregnancy outcome and fetomaternal hemorrhage after noncatastrophic trauma. *Am J Obstet Gynecol*. 1990;162(3):665-671.
9. Klinich KD, Flannagan CA, Rupp JD, Sochor M, Schneider LW, Pearlman MD. Fetal outcome in motor-vehicle crashes: effects of crash characteristics and maternal restraint. *Am J Obstet Gynecol*. 2008;198(4):450-459.
10. Gazmararian JA, Lazorick S, Spitz AM, Ballard TJ, Saltzman LE, et al. (1996) Prevalence of violence against pregnant women. *JAMA* 275: 1915-1920.