

Case Report

Unpredictable Root Canal Morphology –Expect the Unexpected

Sohez Makani¹, Kiran Vachhani², Kailash Attur³, Shoba Fernandes⁴

¹Post Graduate Student, ²Head and Professor, ³Reader, Department of Conservative Dentistry and Endodontics, ⁴Head and Professor Department of Paediatric Dentistry, Narsinhbhai Patel Dental College and Hospital, Visnagar – 384315, Dist. Mehsana, North Gujarat, India

Abstract:

A maxillary first molar with more than four canals is an interesting example of anatomic variations, especially when two of these canals are detected, with separate apical foramen in the distal root of maxillary molar. The inability to locate the unexpected canals of various anatomical configuration and subsequently treat them, may lead to therapeutic failure. Endodontic Retreatment is usually the modality of choice in such cases. This report describes a case of a maxillary first molar with five canals (two mesial canals in mesial root, two distal canals in two distal roots and a palatal canal in palatal root). Additionally it shows a rare anatomic configuration and emphasizes the importance of identifying additional canals.

Key Words: Five root canals, Maxillary First Molar, Two Distobuccal Canals, Endodontic Retreatment

Corresponding Author: Dr. Sohez Makani, Post Graduate Student, Department of Conservative Dentistry and Endodontics, Narsinhbhai Patel Dental College and Hospital, S. P. Sahakar Vidyadham, Ambaji Gandhinagar Link Road, Near Kamana Char Rasta, Visnagar – 384315, Dist. Mehsana, North Gujarat, India. Email: Sohez.makani@gmail.com

This article may be cited as: Makani S, Vachhani K, Attur K, Fernandes S. Unpredictable Root Canal Morphology –Expect the Unexpected. J Adv Med Dent Scie Res 2015;3(1):169-174.

INTRODUCTION:

Maxillary first molar has immense variability with regards to the number of roots, canals and anatomy. It is traditionally described to have three roots and three canals, with the most common variation of additional(second) mesiobuccal canal (MB2). The failure rate of endodontic treatment in maxillary first molar is high due to the complex morphology of root canals.^[1-4] Very narrow mesiodistal dimension of the mesiobuccal root and associated concavities on its mesial and distal surfaces are consistent with the presence of two canals, while single canals are usually found in distobuccal and

palatal roots.^[5, 6] The reported incidence of MB2 is between 18% and 96.1%.^[7-9] while the incidence of second distobuccal canal(DB2) ranges from 1.64% to 9.5%.^[10,11] Chevigny et al reported that the success rate of endodontic treatment is 80% in the teeth associated with apical periodontitis.^[12] Failure rate of endodontics due to missed canals is 42%.^[13] The goal of retreatment is to ensure success. Thus special attention is given to proper access cavity preparation, identification of missed canals and thorough cleaning and shaping procedures of previous treated root canals.^[14] Endodontic microsurgery success rate ranges from 88%

to 94%.^[15] However, this option is chosen only when the improbability of the improved quality of non surgical retreatment is anticipated.

The purpose of this case report was to reemphasize the significance and consequences of missed canals. As well as present Endodontic Retreatment of a Maxillary first molar with uncommon anatomic configuration.

CASE REPORT:

A 25 year old female patient was referred to Department of Conservative Dentistry and Endodontics. Patient presented with pain in 26. Medical History was non-contributory. Past dental history revealed, Root canal treatment performed a year earlier. Clinical examination revealed amalgam restoration in Maxillary Left First Molar (26) and the tooth was sensitive to percussion. According to the symptoms and clinical findings the diagnosis of symptomatic

Chronic apical periodontitis was made and endodontic retreatment was planned. Radiographic evaluation of the involved tooth failed to indicate any variations in the canal anatomy. Improperly obturated palatal root canal was observed (Figure 1).

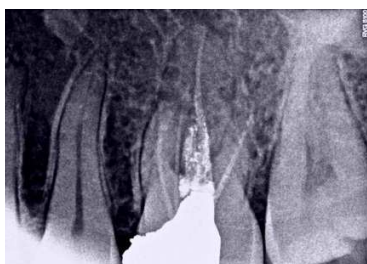

Figure 1: Preoperative Periapical radiograph of Left Maxillary First Molar

Root canal therapy was performed in two appointments. Administration of local anesthesia was followed by the placement of rubber dam. Amalgam restoration was removed and Endodontic access cavity was

prepared. Examination of the pulp chamber floor with DG-16 Endodontic explorer (GDC Marketing), under 2.5x-420 magnifying loupes (Galilean loupes, Lifecare Medical Equipments Co., Ltd., Zhejiang, China) revealed a pulp stone. This was removed using ultrasonic micro-endodontic tip (ET 18D tip; Satelec, Acteon, France).

Four previously treated root canals were observed. An Additional root canal DB2 was detected using DG-16 explorer when a drop was encountered with the probe tip on the floor of the pulp chamber. This was confirmed by the Champagne test, performed with 3% Sodium Hypochlorite (NaOCl). Then accessed with ISO no. 10 K-file. Guttapercha from previously treated canals was removed with the help of H-files. Patency of canals was confirmed with ISO No. 10 K-file. Working length was determined using Root ZX II (J. Morita, Japan). The canals were reshaped and cleaned with rotary Protaper with copious irrigation of 3% NaOCl, 2% Chlorhexidine interspersed with Normal Saline.

At the end of first visit canals were dried with paper points and water based calcium hydroxide medicament was placed in the root canals

At the second visit, (scheduled 2 weeks later) the tooth was asymptomatic. The master cone selection radiographs were taken separately (One for Mesial and palatal canals and another for distal canals in figure 2 and 3) to avoid overlap of cone images, to check cone fit at working length and to avoid false tug back of guttapercha cones. Obturation was done using AH plus sealer and lateral compaction technique. Upon completion of root canal treatment, Composite Restoration was performed. Post obturation evaluatory radiograph was taken (Figure 4, 5 & 6). Follow-up was scheduled after 3 and 6 months and post-endodontic final restoration was done (Figure 7-9).

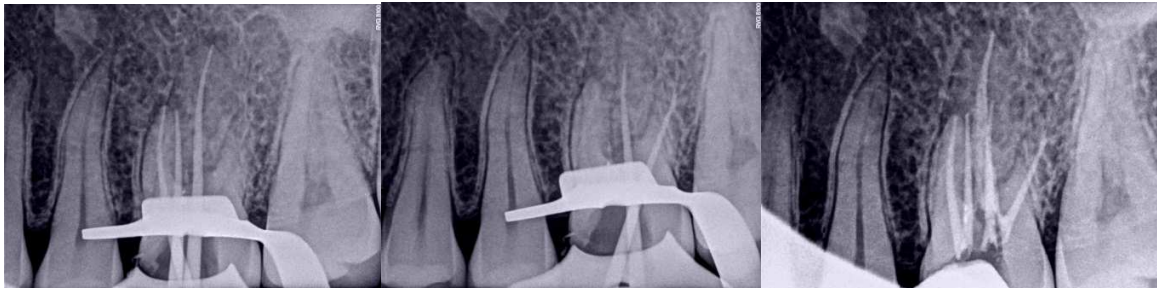


Figure 2: The master cones Radiograph for Mesial and palatal canals

Figure 3: The master cones Radiograph for Distal Canals

Figure 4: Post Obturation Radiograph

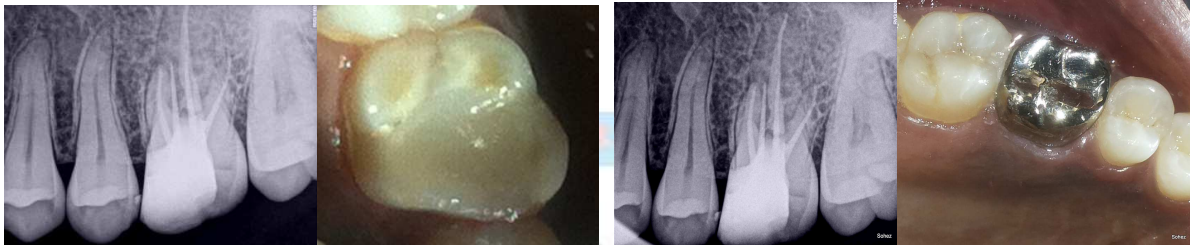

Figure 5: Radiographs after Composite Restoration

Figure 6: composite Restoration

Figure 7: Radiograph after 3 month

Figure 8: Full coverage Crown

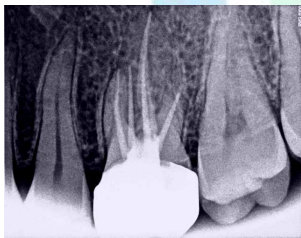


Figure 9: Radiograph after 6 months

Discussion:

The feasibility of negotiating teeth with unusual morphology depends upon a thorough knowledge of the normal anatomy, as well as existence of anomalies. Proper access cavity preparation is a key, to the successful identification and negotiation of root canals. Morphology of root and root canal varies greatly in the reported literature. Although several anatomic configurations have been reported, the most common reports are of four canal i.e one palatal, one distobuccal and two mesibuccal root canals.^[11]

Hummonen et al studied a group of 38 root canal treated maxillary first molars with apical periodontitis. MB2 canals were verified in 30 out of 38 through a computer tomography scan and of those 90% of MB2 canals were unfilled.

The Second Distobuccal canal or distopalatal canal in maxillary first molar is uncommon, of which Vertucci Type IV (Two separate, distinct canals extend from the pulp chamber to the apex) is very rare. This fact is confirmed by various researchers (Fig/Table:11). With great variety of morphology of root canal, suspicion of iatrogenic or pathological perforation arises, especially when fresh bleeding spots are glimpsed at unexpected locations. To rule out such doubt, various methods have been discussed by several authors,^[12] Amongst these the Clinical methods are -careful examination of dentinal map ,use of DG 16 to explore the floor of the pulp chamber, search

Table-11: Incidence of various canal configuration in distobuccal root of maxillary first molar¹¹

Sr. No.	Reference	Number of teeth in study	Type of study	1 canal %	2 or more canal %	2 into 1 canal at apex %	2 or more canals at apex %
1	Sert, S and Bayirli, GS (2004)	200	Clearing	90.50% (181)	9.50% (19)	97% (194)	3% (6)
2	Al Shalabi, RM et al (2000)	83	Clearing	97.50% (81)	2.50% (2)	97.50% (81)	2.50% (2)
3	Çalışkan, MK et al (1995)	100	Clearing	98.40% (98)	1.60% (2)	98.40% (98)	1.60% (2)
4	Thomas, RP, Moule, AJ and Bryant, R (1993)	216	Radiographic examination with radiopaque gel infusion of canals	95.70% (207)	4.30% (9)	96.20% (208)	3.80% (8)
5	Pineda, F and Kuttler, Y (1972)	262	In vitro radiographic examination	96.40% (253)	3.60% (9)	96.40% (253)	3.60% (9)

for hemorrhagic spots (indicate the presence of extra canals), performing champagne test with sodium hypochlorite, staining the pulp chamber with dye (eg, 1% methylene blue), use of ultrasonic tips to remove a small amount of tooth structure or calcification and trough the line angles of the pulp chamber will help, modification of the conventional outline form to include the extra canals, ensure adequate straight-line access to improve visibility. Methods accentuated via technology are additional angulated radiographs (at least 3 radiographs at varying horizontal angles), computed tomography, magnification i.e loupes and dental operating microscopes. Among these, Computed Tomography has played a major role in understanding the root canal system and provided an accurate measurement of the morphology of the root canal by detecting missed canals with high precision in three dimensions, overcoming the drawbacks of conventional radiographs.

The Cone Beam Computed Tomography (CBCT) was introduced in endodontics in

1990.^[14]The major advantages of CBCT scanning over the conventional CT scans are x-ray beam limitation,^[15] rapid scan time,^[16] and effective dose reduction.^[17] Even though the use of CBCT scanning involves less radiation than conventional CT scanning, the radiation dose is still higher than regular conventional intraoral radiographs.^[18] At this point of time, CBCT scanning is limited to major metropolitan areas and is prohibitively expensive. The inaccessibility and economic constraints, helped to refocus the emphasis on the clinician's skills, accentuated with methods like champagne test, loupes magnification, use of ultrasonic tips and DG-16 explorer.

Thus emphasizing that in daily endodontic practice the clinician's skill plays a pivotal role and technology provides the confirmation.

The reported case, represents an uncommon canal configuration in maxillary first molar as, possible cause for the failure of initial RCT .The identification of pulp stone, the DB2 Canal, subsequently removal of the pulp

stone followed by the treatment of DB2, lead to the successful outcome.

CONCLUSION:

The clinician should acquire knowledge and must explore the potential anatomic variations of root canal system. Currently Cone beam computed tomography is an adjunct diagnostic aid for detection of additional canals. But the cost and inaccessibility limits its application in regular practice. Magnification is a great tool to be used in everyday practice, for detection of unusual anatomic configuration of the root canal system. Undetected root canals may lead to treatment failure and detecting those missed canal may lead to success in retreatments. Technological advancement in the field of Endodontics with introduction of modern Equipments has limited the reliability on clinician's skill. Thus treating the patient with available armamentarium evokes the best out of the clinician's knowledge and skills.

REFERENCES:

1. Smadi L, Khraisat A. Detection of a second mesiobuccal canal in the mesiobuccal roots of maxillary first molar teeth. *Oral Surg Oral Med Oral Pathol Oral Radiol Endod.* 2007; 103:77-81.
2. Vertucci FJ. Root canal morphology and its relationship to endodontic procedure. *Endod Topics.* 2005; 10:3-29.
3. Wolcott J, Ishley D, Kennedy W, Johnson S, Minnich S, Meyers J. A 5 yr clinical investigation of second mesiobuccal canals in endodontically treated and retreated maxillary molars. *J Endod.* 2005; 31:262-4.
4. Weine FS, Hayami S, Hata G, Toda T. Canal configuration of the mesiobuccal root of the maxillary first molar of a Japanese subpopulation. *Int Endod J.* 1999; 32:79-87.
5. Ash M, Nelson S. *Wheeler's Dental Anatomy, Physiology and Occlusion.* 8th ed. Philadelphia: Saunders; 2003.
6. Walton R, Torabinejad M. *Principles and Practice of Endodontics.* 2nd ed. Philadelphia: W.B. Saunders Co.; 1996.
7. Hartwell G, Appelstein CM, Lyons WW, Guzek ME. The incidence of four canals in maxillary first molars: a clinical determination. *J Am Dent Assoc.* 2007; 138:1344-6.
8. Hartwell G, Bellizzi R. Clinical investigation of in vivo endodontically treated mandibular and maxillary molars. *J Endod.* 1982; 8:555-7.
9. Kulild JC, Peters DD. Incidence and configuration of canal systems in the mesiobuccal root of maxillary first and second molars. *J Endod.* 1990; 16:311-7.
10. Caliřkan MK, Pehlivan Y, Sepetciođlu F, Turkun M, Tuncer SS. Root canal morphology of human permanent teeth in a Turkish population. *J Endod.* 1995; 21:200-4.
11. Cleghorn BM, Christie WH, Dong CCS. Root and root canal morphology of the human permanent maxillary first molar: a literature review. *J Endod.* 2006; 32:813-21.
12. Holderrieth S, Gernhardt CR. Maxillary molars with morphologic variations of the palatal root canals: a report of four cases. *J Endod.* 2009; 35:1060-1065.
13. Michael M. Hoen, DDS, and Frank E. Pink, DDS. Contemporary Endodontic Retreatments: An Analysis based on Clinical Treatment Findings. *Int Endod J.* 2002; 28(12):834-836.
14. Kalender WA, Sessler W, Klotz E, Vock P. Spiral volumetric CT with single breath hold technique, continuous transport and continuous scanner rotation. *Radiology.* 1990; 173:567-568.
15. Lofthag-Hansen S, Huuonen S, Grondahl K, et al. Limited cone-beam CT and intraoral radiography for the diagnosis of periapical pathology. *J Endod.* 2007; 103:114-119.

Makani S et al. Unpredictable Root canal morphology.

16. Cotton TP, Geisler TM, Holden DT, et al. Endodontic applications of cone-beam volumetric tomography. J Endod2007;33:1121–1132.
17. Patel S, Dawood A, Ford TP, et al. The potential applications of cone beam computed tomography in the management of endodontic problems. J Endod2007;40:818–830.
18. Ludlow JB, Davies-Ludlow LE, Brooks SL, et al. Dosimetry of 3 CBCT devices for oral and maxillofacial radiology: CB Mercuray, NewTom 3G and i-CAT. DentomaxillofacRadiol2006;35:219–226.

Source of support: Nil

Conflict of interest: None declared

