

ORIGINAL ARTICLE

ASSESSMENT OF VARIOUS FIXATION OPTIONS FOR THE TREATMENT OF FEMUR FRACTURE: A COMPARATIVE STUDY

Sangam Garg¹, Sandeep Kumar², Sagar Garg³, Sahil Gaba⁴, Gagan deep Gupta⁵, Anmol Sharma⁶

¹Senior Resident, ²Assistant professor, Department of Orthopaedics, Gian Sagar Medical College and Hospital, Ram Nagar, Banur, Punjab, ³Medical officer, Civil Hospital, Sirsa, Haryana. ⁴Senior resident, Department of Orthopaedics, AIIMS, Delhi, ⁵Senior resident, Department of Orthopaedics, Maharishi Markandeshwar University, Mullana, Ambala, Haryana, ⁶Senior resident, Department of Orthopaedics, Government hospital, Sector 16, Chandigarh, India

ABSTRACT:

Background: Incidence of intertrochanteric fractures has been found to be significantly increasing in today's modern human populations. Generally, intramedullary fixation and extramedullary fixation are the 2 primary options for treatment of such fractures. The dynamic hip screw (DHS), commonly used in extramedullary fixation, has become a standard implant in treatment of these fractures. Proximal femoral nail (PFN) and Gamma nail are 2 commonly used devices in the intramedullary fixation. Hence; we prospectively analyzed and compared the DHS and the PFN method of fixation in intertrochanteric fracture of femur in the adults. **Materials & Methods:** Analysis of a total of 100 patients reporting from 2010 to 2014 with intertrochanteric femur fracture was done in the present analysis. Out of 100 patients 50 patients were treated with P.F.N. and 50 with D.H.S. In this study more than 50 years of age patient were surgically fit who has been diagnosed as having intertrochanteric fractures. The fracture was classified using Orthopaedic Trauma Association classification. Implant either DHS or PFN was randomly selected by operating surgeon. A combination of 3rd generation Cephalosporin and Amino glycoside was administered intravenously 30 min. prior to the skin incision. Patients were encouraged calf and ankle exercises from day one and mobilized non-weight bearing from the second postoperative day depending upon the physical condition of the patient. All drains were removed by 24 h. Follow-up the patients were maintained and results were analyzed. **Results:** 00 confirmed cases of intertrochanteric femur reporting from 2010 to 2014 were analyzed. Out of 100 cases, 50 were treated by a dynamic hip screw and 50 were treated by proximal femoral nail. The average age was 64.5 years. Out of 100, 40 were males and 60 were females. Accidents were the most common reason for occurrence of fractures in the present study. There were a total of 12 A-1 fractures, 29 A-2 fractures and 9 A-3 fractures. Measurement of blood loss was done by using mop count and collection in suction drain. Blood loss was comparatively less for PFN cases. The average blood loss in the P.F.N group and DHS group were 110 ml and 260 ml respectively. Blood transfusion was required in 10 cases of DHS group. At one month's follow-up time, hip score in the D.H.S group was less than that of the P.F.N group. **Conclusion:** Fracture dimensions and quality of bone decides the type of fixation. For the achievement of best post-surgical results, a good quality reduction and proper positioning of the implants favour good prognosis.

Key words: DHS, Femur, PFN

Corresponding author: Dr. Sangam Garg M.S. Orthopaedics, Senior Resident, Department of Orthopaedics, Gian Sagar Medical College and Hospital, Ram Nagar, Banur, Punjab, India
E mail: aryansandhus@gmail.com

This article may be cited as: Garg S, Kumar S, Garg S, Gaba S, Gupta GD, Sharma A. Assessment of various fixation options for the treatment of femur fracture: A comparative study. J Adv Med Dent Scie Res 2016;4(4):120-124.

Access this article online	
<p>Quick Response Code</p> 	Website: www.jamdsr.com
	<p>DOI:</p> <p>10.21276/jamdsr.2016.4.4.26</p>

INTRODUCTION

With rising age, the incidence of intertrochanteric fractures has been found to be significantly increasing in modern human populations.^{1,2} Generally, intramedullary fixation and extramedullary fixation are the 2 primary options for treatment of such fractures. The dynamic hip screw (DHS), commonly used in extramedullary fixation, has become a standard implant in treatment of these fractures.^{3,4} Proximal femoral nail (PFN) and Gamma nail are 2 commonly used devices in the intramedullary fixation. Previous studies showed that the Gamma nail did not perform as well as DHS because it led to a relatively higher incidence of post-operative femoral shaft fracture.^{5,6} Ever since its introduction by AO/ASIF group in 1997, PFN has become prevalent in treatment of intertrochanteric fractures in recent years because it was improved by addition of an antirotation hip screw proximal to the main lag screw. However, reports are present in the literature which highlights both benefits and technical failures of PFN.⁷⁻⁹ Hence; we prospectively analyzed and compared the DHS and the PFN method of fixation in intertrochanteric fracture of femur in the adults.

MATERIAL AND METHODS

In the present study from June 2010 to July 2014 analysis of all the patients with intertrochanteric femur fracture. Out of 100 patients 50 patients were treated with P.F.N. and 50 with D.H.S. More than 50 years of age patient were surgically fit who has been diagnosed as having intertrochanteric fractures. The patients were randomly selected on first come and first inclusion basis. Fifty consecutive operated cases were selected and the patients were informed about the study in all respects and informed consent was obtained from each patient. The exclusion criteria were Patients unfit for the surgery, with compound or pathological fractures, admitted for re-operation and those who have not given written consent for surgery. All the patients were carefully evaluated preoperatively which included detailed history to determine the cause of fracture and other diseases. The radiograph of pelvis with both hips and lateral view of the affected hip was taken. The fracture was classified using Orthopaedic Trauma Association (OTA) classification. Skin traction was applied to all cases. Implant either DHS or PFN was randomly selected by operating surgeon. For DHS Length of compression screw is measured from tip of the head to the base of greater trochanter on AP view X-ray subtracting magnification, neck shaft angle Neck

shaft angle is determined using goniometer on X-ray AP view on unaffected side and length of side plate length of the side plate is determined to allow purchase of atleast 8 cortices to the shaft distal to the fracture. Neck shaft angle was measured in unaffected side in AP X-ray using goniometer and in all our cases a standard length PFN (250 mm) was used. PFN Nail diameter was determined by measuring diameter of the femur at the level of isthmus on an AP X-ray. All cases were operated on a standard fracture table under spinal anesthesia using standard operating technique of the implant chosen. The fracture table is essential to achieve reduction and as it allows free access for the C-arm in both views. A combination of 3rd generation Cephalosporin and Amino glycoside was administered intravenously 30 min. prior to the skin incision. In standard doses the same combination was used for 48 hours postoperatively. In our study all the patients were treated manual compression of the calf, elastic stockings and physical methods such as early mobilization Patients were encouraged calf and ankle exercises from day one and mobilized nonweight bearing from the second postoperative day depending upon the physical condition of the patient. All drains were removed by 24 h. The wounds were inspected on the 3rd and 6th post operative day. Stitches were removed on the 11th day. Patients were followed up at one monthly interval till fracture union and then at 6 monthly interval for 1 year and then at yearly interval.

RESULTS

In the present study, 100 confirmed cases of intertrochanteric femur reporting from 2010 to 2014 were analyzed. Out of 100 cases, 50 were treated by a dynamic hip screw and 50 were treated by proximal femoral nail. Maximum age of the patients in the present study was 80 years and minimum was 45 years. The average age was 64.5 years. Out of 100, 40 were males and 60 were females. Accidents were the most common reason for occurrence of fractures in our study. Classification of all the fractures was done according to A.O. (O.T.A.) classification. There were a total of 12 A-1 fractures, 29 A-2 fractures and 9 A-3 fractures. Measurement of blood loss was done by using mop count and collection in suction drain. Blood loss was comparatively less for PFN cases. The average blood loss in the P.F.N group and DHS group were 110 ml and 260 ml respectively. Blood transfusion was required in 10 cases of DHS group. At one month's follow-up time, hip score in the D.H.S group was less than that of the P.F.N group.

Graph 1: Demographic and fracture distribution of patients in which implants were used

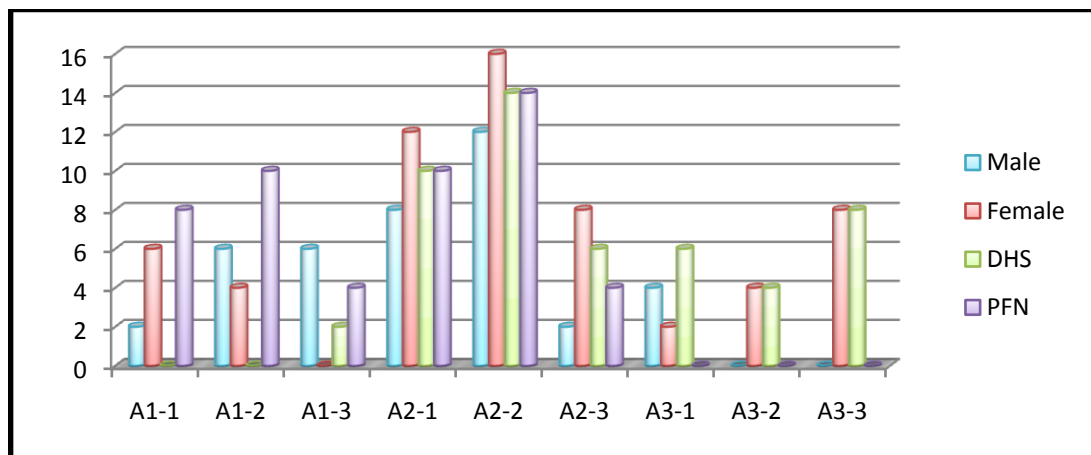


Table 1: Intra-operative complications of DHS and PFN

Complications	No. of cases
DHS	
Improper insertion of compression screw	6
Varus angulations	4
PFN	
Failure to achieve closed reduction	0
Fracture of lateral cortex	2
Failure to put derotation screw	6
Fracture displacement by nail insertion	2

Table 2: Comparison between DHS and PFN.

	DHS	PFN (n=50)	p-value
Mean blood loss	260 ml	110 ml	0.001*
Mean radiation exposure	42 (in no.)	72 (in no.)	0.001*
Hip score at 1 month (Harris)	26.4	35	0.002*
Hip score at 6 month (Harris)	87	90	0.482
Hip score at 1 year (Harris)	95	95	0.845
Mean Sliding	7.5 mm	5.7 mm	0.001*
Mean shortening	10.1 mm	5.6 mm	0.002*
Implant failure cases	4	2	0.003*
No. of deaths	2	2	0.412
No. of cases of infections	2	0	0.003*
GT splinting	0	4	0.425

* Significant

DISCUSSION

The most common fracture is intertrochanteric fracture of the hip especially in the elderly with porotic bones, usually due to low-energy trauma like simple falls. By 2040 the incidence is estimated to be doubled. In India the figures may be much more. The incidence of intertrochanteric fracture is rising because of increasing number of senior citizens with osteoporosis. Problems of these fractures are association with substantial morbidity

and mortality, implant failure, cut out of head, and penetration into hip, malunion, great financial burden to the family and associated medical problem like diabetes, hypertension.¹⁰ Hence; we prospectively analyzed and compared the DHS and the PFN method of fixation in intertrochanteric fracture of femur in the adults.

Siding is an essential principle in the management of intertrochanteric fractures. The sliding properties of both implants vary considerable. Sliding permits

impaction of the fracture fragments thus promoting healing. Kyle et al¹¹ in his extensive study of the biomechanical principles of the sliding hip screw has identified key factors that promote sliding. A reduction in the bending forces is vital since bending forces reduce slide and cause jamming of the implant. Amongst all intra medullary devices the Gamma nail requires the largest force. The explanation lies in the barrel of the side plate, the barrel provides a free passage for the screw to slide, thus the longer the barrel length the less the forces required to initiate sliding. 135 Degree is the most routinely used barrel plate angle in most studies quoted in the literature; this is because of the ease of insertion and the more anatomical restoration of femoral neck angle. However several advantages are seen with 150 degree side plate, since the forces are acting more in line with the screw less bending forces act across the screw so relatively less force is required to initiate sliding resulting in more impaction.^{12, 13}

The average hospital stay was higher in DHS (14.52 days) as compared to PFN cases where it was 13.01 days. On the eleventh day, almost all the stitches were removed. More than 14% of the cases in our study had complications while implant failure was seen in 6 cases. During the insertion of the nail, greater trochanter splintering was seen in less than 5 % of the patients. As far as infections are concerned, they were seen in less than 5 % of the cases. In infection cases, no implant removal was required when detected within 20 days of the surgery. By radiological comparison the amount of sliding seen between the immediate postoperative X-ray the one year follow up X-ray in both the groups, it was noted that the amount of sliding in the P.F.N group was less as compared to the dynamic hip screw. The results of our study were in correlation to the results of Kyle et al¹¹ and Hardy et al.¹⁴ who found nail blocking the head and neck fragment of the proximal part. Proximal femoral nail were found to be more useful in our study in terms of its instability and reverse oblique patterns due to the fact that it has better axial telescoping and rotational stability as it is a load shearing device. As they can withstand higher static and several fold higher cyclical loading than dynamic hip screw, they are proved to be more biomechanically stronger. So the healing of the fracture occurs without primary restoration of the medial support.^{11, 15} Kumar et al compared the prognosis of intertrochanteric fractures treated with Dynamic Hip Screw and Proximal Femoral nail. They studies 50 cases of Intertrochanteric fractures of femur treated by a dynamic hip screw and

proximal femoral nail and concluded that in younger patients, better tolerance was seen in patients treated with DHS while PFN showed better prognosis in osteoporotic patients.¹⁶ Bagaria et al reviewed the current evidences related to complications of Intertrochanteric fracture along with certain guidelines to avoid these complications. They summarized by stressing on facts that intrertrochanteric fractures are not very prone for complications, however when complications do occur they are quite disabling and challenging. Also by understanding the personality of the fracture and by choosing correct implant, major complications can be avoided.¹⁷

CONCLUSION

From the results, it can be concluded that fracture dimensions and quality of bone decides the type of fixation. For the achievement of best post-surgical results, a good quality reduction and proper positioning of the implants favour good prognosis.

REFERENCES

1. Cummings SR, Rubin SM, Black D: The future of hip fractures in the United States. Numbers, costs, and potential effects of postmenopausal estrogen. *Clin Orthop Relat Res*, 1990; 252: 163–66.
2. Kannus P, Parkkari J, Sievänen H et al: Epidemiology of hip fractures. *Bone*, 1996; 18(Suppl.1): 57–63.
3. Bridle SH, Patel AD, Bircher M, Calvert PT: Fixation of intertrochanteric fractures of the femur. A randomized prospective comparison of the gamma nail and the dynamic hip screw. *J Bone Joint Surg Br*, 1991; 73(2): 330–34.
4. Radford PJ, Needoff M, Webb JK: Aprospective randomised comparison of the dynamic hip screw and the gamma locking nail. *J Bone Joint Surg Br*, 1993; 75(5): 789–93.
5. Butt MS, Krikler SJ, Nafie S, Ali MS: Comparison of dynamic hip screw and gamma nail: a prospective, randomized, controlled trial. *Injury*, 1995; 9: 615–18.
6. Saarenpää I, Heikkinen T, Ristiniemi J et al: Functional comparison of the dynamic hip screw and the Gamma locking nail in trochanteric hip fractures: a matched-pair study of 268 patients. *Int Orthop*, 2009; 33(1): 255–60.
7. Nuber S, Schönweiss T, Rüter A: Stabilisation of unstable trochanteric femoral fractures. Dynamic hip screw (DHS) with trochanteric stabilisation plate vs. Proximal femur nail (PFN). *Unfallchirurg*, 2003; 106(1): 39–47.
8. Boldin C, Seibert FJ, Fankhauser F et al: The proximal femoral nail (PFN): a minimal invasive treatment of unstable proximal femoral fractures: a prospective study of 55 patients with a follow-up of 15 months. *Acta Orthop Scand*, 2003; 74(1): 53–58.
9. Pires RE, Santana EO Jr, Santos LE et al: Failure of fixation of trochanteric femur fractures: clinical

- recommendations for avoiding Z-effect and reverse Z-effect type complications. *Patient Saf Surg*, 2011; 22: 17.
10. Kulkarni GS, Limaye R, Kulkarni M, Kulkarni S. Intertrochanteric fractures. *Indian J Orthoped*. 2006; 40(1):16-23.
 11. Kyle RF, Wright TM, Burstein AH. Biomechanical analysis of the sliding characteristics of compression hip screws. *J Bone Joint Surg Am*. 1980;62:1308e1314.
 12. Baumgaertner MR, Curtin SL, Lindskog DM, Keggi J. The value of the tip-apex distance in predicting failure of fixation of peritrochanteric fractures of the hip. *J Bone Joint Surg Am*. 1995;77:1058e1064.
 13. Gl Wolfgang, Bryant MH, O'Neil JP. The treatment of intertrochanteric fractures of the proximal femur using sliding screw plate fixation. *Clin Orthop*. 1982;163:148e158
 14. Hardy D, Descamps P, Krallis P, et al. Use of an intramedullary hip screw compared with a compression hip screw with a plate for intertrochanteric femoral fractures. A prospective randomized study of one hundred patients. *J Bone Joint Surg Am*. 1998;80:618e630.
 15. Boyd HB, Griffin LL. Classification & treatment of intertrochanteric fractures. *Arch Surg*. 1949;58:853e866.
 16. Kumar R, Singh RN. Comparative prospective study of proximal femoral nail and dynamic hip screw in treatment of intertrochanteric fracture femur. *J Clinic Orthoped Trauma*. 2012; 3: 28-36.
 17. Bagaria V, Wadia F. Complications Related to Intertrochanteric fractures. *Trauma International* July-Sep 2015;1(1):25-30.



Source of support: Nil

Conflict of interest: None declared

This work is licensed under CC BY: *Creative Commons Attribution 3.0 License*.