

ORIGINAL ARTICLE

ANALYSIS OF CASES OF TETANY- A CLINICAL STUDY

Vivek Katiyar

Assistant professor, Department of Medicine, Katihar Medical College & Hospital, Katihar, Bihar, India

ABSTRACT:

Background: Tetany is categorized by variable combinations of features comprising cramps, muscle twitching, circumoral numbness etc. The present study was conducted to assess the cases of tetany. **Materials & Methods:** The present study was conducted on 64 cases of tetany of both genders. A thorough clinical examination was performed in all and laboratory investigation such as serum calcium, albumin, ABG, sodium and potassium was done. Symptoms and various causes were recorded. **Results:** Out of 64 patients, males were 30 and females were 34. The difference was non- significant (P- 1). Common symptoms were cramps in males (25) and females (32), paresthesia of hand and feet in males (24) and females (29), laryngeal stridor in males (22) and females (25), carpopedal spasm in males (27) and females (25), circumoral numbness in males (21) and females (30) and muscle twitching in males (29) and females (25). Common causes were recurrent vomiting seen in 9 males and 10 females, Bartter' syndrome in 1 male and 2 females, anxiety hyperventilation in 5 males and 6 females, vitamin deficiency in 5 males and 4 females, acute pancreatitis in 5 males and 6 females, idiopathic hyperparathyroidism in 3 males and 2 females and hypomagnesaemia in 2 males and 4 females. The difference was significant (P< 0.05). **Conclusion:** Tetany is an emergency condition which demands immediate management of the cases. Various causes are acute pancreatitis, vitamin D deficiency, recurrent vomiting etc.

Key words: acute pancreatitis, laryngeal stridor, Tetany.

Corresponding author: Dr. Vivek Katiyar, Assistant professor, Department of Medicine, Katihar Medical College & Hospital, Katihar, Bihar, India

This article may be cited as: Katiyar V. Analysis of Cases of Tetany- a Clinical Study. J Adv Med Dent Scie Res 2015;3(3):133-136.

INTRODUCTION

Tetany is categorized by variable combinations of features comprising cramps, muscle twitching, circumoral numbness, paresthesias of hands and feet, laryngeal stridor, carpopedal spasm, and convulsions. Tetany can be understood as a hyperexcitability of the axons of peripheral nerves leading to the generation of repetitive discharges.¹

Trousseau sign and chvostek sign unmask latent tetany in patients with numbness, tingling and cramps in extremities. There is carpopedal spasm observed following application of inflated blood pressure cuff over brachial artery 20 mmHg above systolic blood pressure for 3 min which shows Trousseau sign and twitching of circumoral muscles with tapping on facial nerve below zygomatic process 2 cm anterior to earlobe is chvostek sign.²

There are various causes of tetany. Common are recurrent vomiting, anxiety hyperventilation, Bartter's syndrome, vitamin D deficiency, Idiopathic hypoparathyroidism and hypomagnesaemia etc. It has been observed that decrease in ionized calcium is more significant than total calcium level, as it is the biologically active component. In different causes of tetany, total serum calcium can be normal when ionized calcium was low. Awareness regarding the etiological spectrum of tetany is very poor amid physicians.³ Hyperventilation can be defined as a state in which breathing in excess of metabolic requirements results in

hypocapnia. Many medical and psychiatric conditions can lead to this condition. The individual manifestations of hypocapnia vary widely, but symptoms can include paresthesias in the face, trunk, and extremities, fasciculations, and tetany, among others.⁴ The present study was conducted to assess the cases of tetany.

MATERIALS & METHODS

The present study was conducted on 64 cases of tetany of both genders. All were admitted to the hospital and were informed regarding the study. The study was approved by institutional ethical committee and was started after obtaining informed written consent.

General information such as name, age, gender etc was recorded. Patients were enquired about recurrent vomiting, polyuria, polydipsia, weakness of limbs, anxiety disorder, drug intake, abdominal pain, thyroid and neck surgeries and chemotherapy for malignant disorders.

A thorough clinical examination was performed in all and laboratory investigation such as serum calcium, albumin, ABG, sodium and potassium was done. Serum phosphate, alkaline phosphatase, serum magnesium and intact parathyroid hormone level was also performed. Results thus obtained were subjected to statistical analysis using chi-square test. P value less than 0.05 was considered significant.

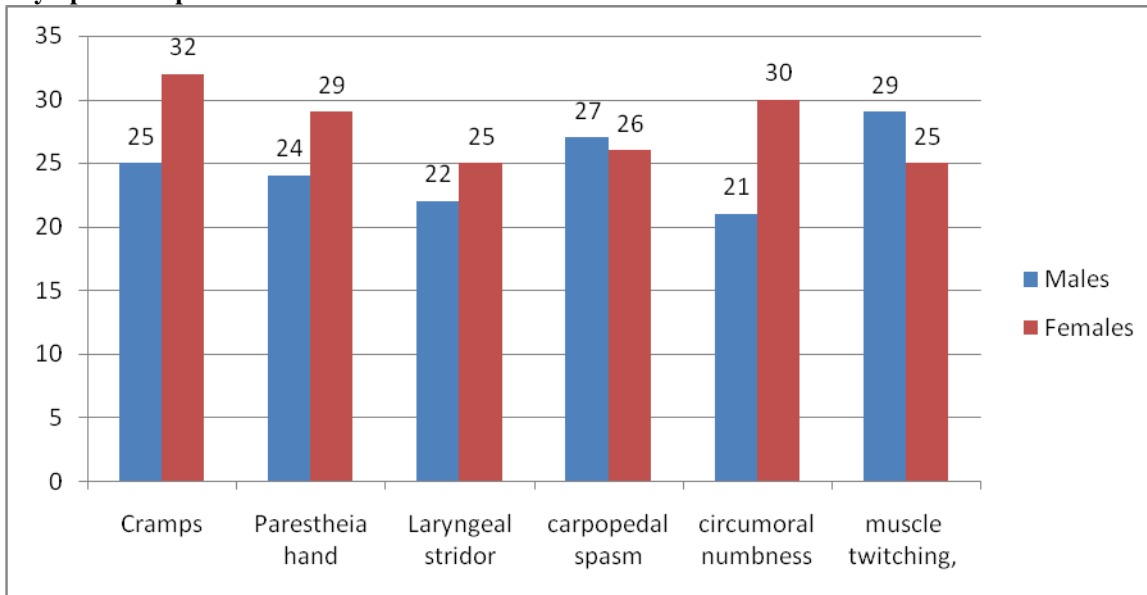
RESULTS

Table I Distribution of patients

Total- 64		
Males	Females	P value
30	34	1

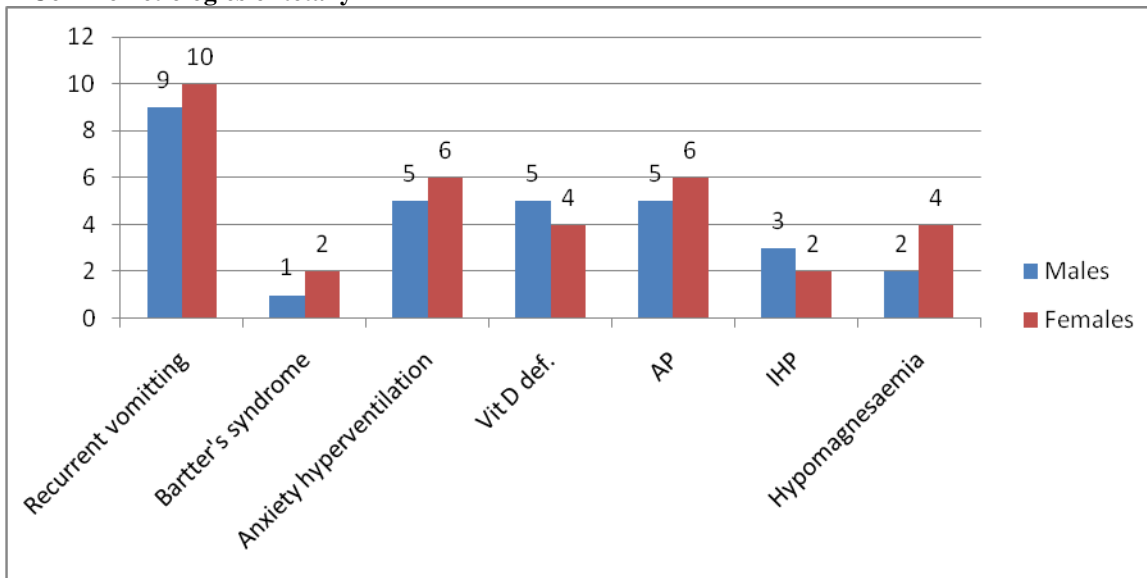
Table I shows that out of 64 patients, males were 30 and females were 34. The difference was non- significant (P- 1).

Graph I Symptoms in patients



Graph I shows that common symptoms were cramps in males (25) and females (32), paresthesia of hand and feet in males (24) and females (29), laryngeal stridor in males (22) and females (25), carpopedal spasm in males (27) and females (25), circumoral numbness in males (21) and females (30) and muscle twitching in males (29) and females (25).

Graph II Common etiologies of tetany



Graph II shows that common causes were recurrent vomiting seen in 9 males and 10 females, Bartter' syndrome in 1 male and 2 females, anxiety hyperventilation in 5 males and 6 females, vitamin deficiency in 5 males and 4 females, acute

pancreatitis in 5 males and 6 females, idiopathic hyperparathyroidism in 3 males and 2 females and hypomagnesaemia in 2 males and 4 females. The difference was significant ($P < 0.05$).

DISCUSSION

Tetany consists of the involuntary contraction of muscles, which may be caused by disease or other conditions that increase the frequency of muscle cells or the nerves that innervate them. Muscle cramps which are caused by the disease tetanus are not classified as tetany. They are due to a lack of inhibition to the neurons that supply muscles.⁵

Tetany is caused by low calcium level in blood. Low ionized calcium levels in the extracellular fluid increase the permeability of neuronal membranes to sodium ion, causing a progressive depolarization, which increases the possibility of action potentials. This occurs because calcium ions interact with the exterior surface of sodium channels in the plasma membrane of nerve cells.⁶

In present study, out of 64 patients, males were 30 and females were 34. We found that common symptoms in patients were cramps, muscle twitching, circumoral numbness, paresthesia of hands and feet, laryngeal stridor, carpopedal spasm and convulsions. This is in agreement with Shantanu et al.⁷

We found that common causes were recurrent vomiting, Bartter's syndrome, anxiety hyperventilation, vitamin deficiency, acute pancreatitis, idiopathic hyperparathyroidism, acute pancreatitis and hypomagnesaemia. Anxiety hyperventilation leads to respiratory alkalosis and is a vital cause of tetany and reports were prevalent particularly after spinal anesthesia.⁸

Bartter's syndrome is an inherited defect characterized by hypokalemia, alkalosis, hypotension and there is defect in Henle's loop of kidney. There are two types, neonatal and classic. Hypocalcemia and tetany by reason of Vitamin D deficiency (VDD) were similarly common. Malnutrition, malabsorption disorders, for example, Celiac disease, decreased sunlight exposure and urbanization was associated with VDD.⁹

The most common cause of tetany is decreased calcium ion concentration, but the literature reports numerous cases of normocalcemic tetany in the context of hyperventilation. This is due to alkalosis causing a change in the relative amounts of bound versus free calcium ions in the plasma. This interpretation has been supported by the frequent observation that normocalcemic patients with tetany still present with Chvostek's sign or a positive Trousseau test, both generally considered indicative of low calcium.¹⁰

Esra et al¹¹ in their study found Gitelman's syndrome (GS), Bartter's syndrome (BS), recurrent vomiting, anxiety hyperventilation, vitamin D3 deficiency (VDD), idiopathic hypoparathyroidism (IHP), postoperative hypoparathyroidism (PHP), acute pancreatitis, tumor lysis syndrome (TLS) and hypomagnesemia as different causes of tetany. Out of 106 patients, total serum calcium was normal in 82 patients with metabolic or respiratory alkalosis. Total calcium was low only in 24 patients. Ionized calcium was low in all patients. GS was the most common

(38%). Recurrent vomiting (19%), anxiety hyperventilation (13%), and VDD (11%) were also common. PHP was less common (4%); acute pancreatitis, TLS, hypomagnesemia and IHP were uncommon.

Acute pancreatitis (AP) is an acute inflammatory disease of the pancreas resulting from autodigestion of the pancreatic tissue due to premature activation of the enzymes within the acini leading to various local and systemic complications. The majority of the patients have "self-limiting disease" while around 20% of the patients have severe disease with mortality ranging from 5-20%.¹²

Puneet et al¹³ in their study found that of 105 patients, 37 (35.2%) had hypocalcemia and 68 (64.8%) had normal corrected serum calcium levels. Patients with hypocalcemia had significantly higher frequency of POF, mortality and need for intervention. Twelve of 37 (32.4%) patients with hypocalcemia had tetany. Patients with tetany had significantly lower serum corrected calcium and ionized calcium levels compared with patients with asymptomatic hypocalcemia. Patients with tetany had significantly higher mortality rates compared with patients with asymptomatic hypocalcemia.

CONCLUSION

Tetany is an emergency condition which demands immediate management of the cases. Various causes are acute pancreatitis, vitamin D deficiency, recurrent vomiting etc.

REFERENCES

1. Schneider D. Hyperventilation-induced tetany: A case report and brief review of the literature. *Neurol Bull* 2009; 1:11-3.
2. Kubota T, Kotani T, Miyoshi Y, Santo Y, Hirai H, Namba N et al. A spectrum of clinical presentations in seven Japanese patients with vitamin d deficiency. *Clin Pediatr Endocrinol* 2006; 15:23-8.
3. Hopper AD, Hadjivassiliou M, Butt S, Sanders DS. Adult coeliac disease. *BMJ* 2007; 335:558-62.
4. Conwell DL, Banks P, Greenberger NJ. Acute and chronic pancreatitis. In: Kasper DL, Haase SL, Jameson JL, Fauci AS, Longo DL, Loscalzo J, Harrison's Principles of Internal Medicine. 19th ed. New York: McGraw-Hill Education. 2012.
5. Chhabra P, Rana SS, Sharma V, Sharma R, Bhasin DK. Hypocalcemic tetany: A simple bedside marker of poor outcome in acute pancreatitis. *Ann Gastroenterol* 2011; 29:214-20.
6. Fong J and Khan A. Hypocalcemia: updates in diagnosis and management for primary care. *Can. Fam. Physician* 2012; 58:158-162.
7. Shantanu, Ismail HM, Jagadeesh T and Bhat RV. Gitelman's syndrome. *J. R. Soc. Med.* 2001; 94:299-300.

8. Gandhi K, Prasad D, Malhotra V and Agrawal D. Gitelman's syndrome presenting with hypocalcemic tetany and hypokalemic periodic paralysis. Saudi J. Kidney Dis. Transpl 2010; 27:1026-1034.
9. Ataş B, Çaksen H, Tuncer O, Kırımı E, Erol M and Yuca SA. A case of Bartter's syndrome associated with nephrocalcinosis presenting with tetany. J. Pediatr. Neurol 2004; 2:45-52.
10. Richardson RM, Forbath N and Karanicolas S. Hypokalemic metabolic alkalosis caused by surreptitious vomiting: Report of four cases. Can. Med. Assoc. J 1983; 129:142-6.
11. Esra, Williams A, Liddle D and Abraham V. Tetany: a diagnostic dilemma. J. Anaesthesiol. Clin. Pharmacol 2011; 27:393-397.
12. Moon HS, Lee SK and Chung JH. Hypocalcemia and hypokalemia due to hyperventilation syndrome in spinal anesthesia – A case report. Korean J 2006; 61:519-523.
13. Puneet, Ramage IJ, Ray M, Paton RD, Logan RW, Beattie TJ. Hypomagnesaemic tetany. J Clin Pathol 1996; 49:343-4.

Source of support: Nil

Conflict of interest: None declared

This work is licensed under CC BY: *Creative Commons Attribution 3.0 License*.