

## Original Research

### Evaluation of cases of seborrheic keratoses in both genders

Anil Goyal

Associate Professor, Department of Dermatology, Muzaffarnagar Medical College, Muzaffarnagar, Uttar Pradesh

#### ABSTRACT:

**Background:** Seborrheic keratoses are common, benign, pigmented epidermal tumors. The present study was conducted to evaluate the cases of Seborrheic keratoses in both genders. **Materials & Methods:** 78 patients of both genders of Seborrheic keratoses were studied. Dermoscopy was performed in all cases. **Results:** Out of 78 patients, males were 38 and females were 40. Common seborrheic keratosis was seen in 34, dermatosis papulosa nigra seen in 26 and pedunculated seborrheic keratoses seen in 18 patients. **Conclusion:** Common seborrheic keratosis, Dermatitis papulosa nigra and Pedunculated seborrheic keratoses. Females were commonly involved than males.

**Key words:** Seborrheic keratosis, Skin lesion, Females

Received: February 6, 2021

Accepted: February 15, 2021

**Corresponding author:** Dr. Anil Goyal, Associate Professor, Department of Dermatology, Muzaffarnagar Medical College, Muzaffarnagar, Uttar Pradesh, India

**This article may be cited as:** Goyal A. Evaluation of cases of seborrheic keratoses in both genders. J Adv Med Dent Scie Res 2021;9(2):97-100.

#### INTRODUCTION

Seborrheic keratoses are common, benign, pigmented epidermal tumors. Many terms such as senile wart, melanoacanthoma, basal cell papilloma, senile keratosis and seborrheic wart have been applied, but seborrheic keratosis is the most widely accepted term.<sup>1</sup> The lesion showed slow growth and the patient reported no increase in size for past many years. Seborrheic keratoses is commonly seen in the head and neck region, but it rarely causes functional impairment.<sup>2</sup>

Despite the diverse clinical presentation of SK, diagnosis is most often clinically straightforward. However, the tumor may simulate other lesions, such as common warts, lentiginos, melanocytic nevi, actinic keratosis, and Bowen disease, or occasionally more aggressive entities, such as basal cell and squamous cell carcinomas, or even cutaneous melanomas.<sup>3</sup>

Even though SK have been well characterized clinically and histopathologically, data regarding clinical and dermoscopic correlation of different types of SK are inadequate. Hence, this study is being carried out to

determine the pattern of clinical variants of SK and to establish whether there is any correlation between the clinical variants of SK and their dermoscopic appearance.<sup>4</sup> The etiology is not well-known, although heredity, sunlight and human papilloma virus (HPV) have been suggested as risk factors.<sup>5</sup> The present study was conducted to evaluate the cases of seborrheic keratoses in both genders.

#### MATERIALS & METHODS

The present study was conducted in 78 patients of seborrheic keratoses in the department of Dermatology. All patients were informed regarding the study and written consent was obtained.

Information such as name, age, gender etc. was recorded. Family history, duration, site of lesions, number of lesions, size of lesions and morphology was also recorded. Dermoscopy was performed in all cases. Results thus obtained were subjected to statistical analysis. P value less than 0.05 was considered significant.

## RESULTS

**Table I Distribution of patients**

Total- 78		
Gender	Males	Females
Number	38	40

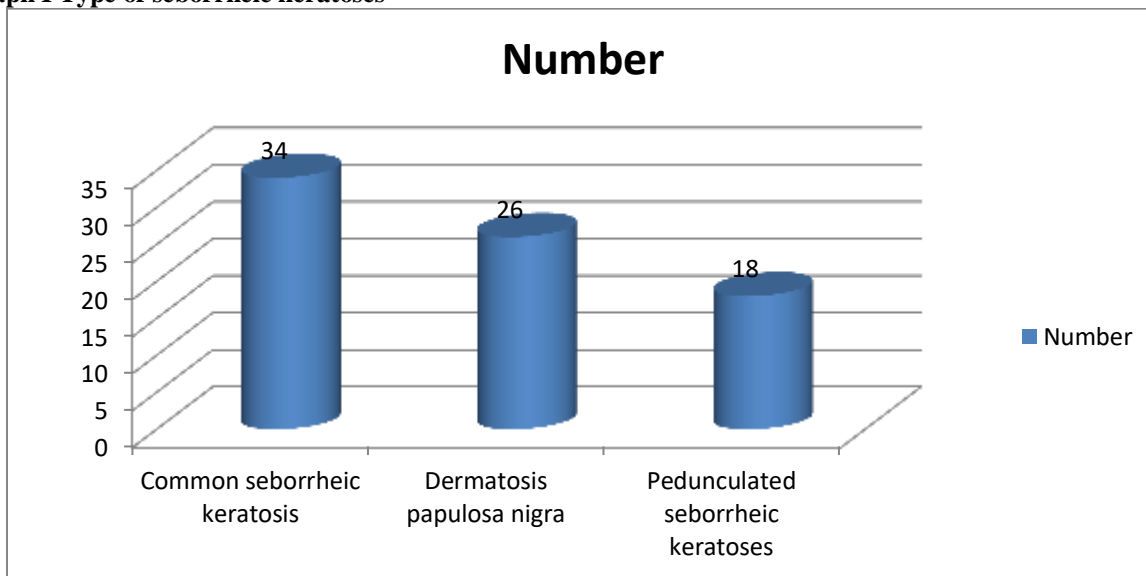
Table I, graph I shows that out of 78 patients, males were 38 and females were 40.

**Table II Type of Seborrheic keratoses**

Type	Number	P value
Common seborrheic keratosis	34	0.04
Dermatosis papulosa nigra	26	
Pedunculated seborrheic keratoses	18	

Table II, graph I shows that common seborrheic keratosis was seen in 34, dermatosis papulosa nigra seen in 26 and pedunculated seborrheic keratoses seen in 18 patients. The difference was significant ( $P < 0.05$ ).

**Graph I Type of seborrheic keratoses**



## DISCUSSION

Seborrheic keratosis (SK) is one of the most common benign epidermal tumors that affects both sexes equally, and usually arises in individuals older than 50 years.<sup>6</sup> It presents as sharply demarcated, slightly raised brownish patches or plaques, usually on sun-exposed surfaces of the skin. The clinical presentation can be quite variable and includes clinical variants, such as stucco keratosis and dermatosis papulosa nigra. The tumors are not, however, seen on the mucous membranes.<sup>7</sup> Commonly papilloma derived from the basal cells. Pigmented subtype may be clinically confused with other pigmented lesions, such as malignant melanoma and melanocytic nevus.<sup>8</sup> The present study was conducted to evaluate the cases of Seborrheic keratoses in both genders.

In present study, out of 78 patients, males were 38 and females were 40. Roh et al<sup>9</sup> in their study included 221 pathology slides of skin tissue from patients with clinically diagnosed SK and 206 cases of biopsy-proven SK. The biopsy-proven cases of SK were assessed for histopathological subclassification. The most frequent histopathological subtype was the acanthotic type, followed by mixed, hyperkeratotic, melanoacanthoma, clonal, irritated, and adenoid types; an unexpectedly high percentage (9.2%) of the melanoacanthoma variant was observed. The adenoid type was more common in sun-exposed sites than in sun-protected sites ( $p=0.028$ ). Premalignant and malignant entities together represented almost one-quarter (24.2%) of the clinicopathological mismatch cases (i.e., mismatch between the clinical and histopathological diagnoses). Regarding the location of SK development, the

frequency of mismatch for the sun-exposed areas was significantly higher than that for sun-protected areas ( $p=0.043$ ).

We observed that common seborrheic keratosis was seen in 34, dermatosis papulosa nigra seen in 26 and pedunculated seborrheic keratoses seen in 18 patients. Rajesh et al<sup>10</sup> conducted a study to establish any correlation between the clinical and dermoscopic appearance of SK and its variants. A total of 250 cases of SK were recruited. A male-to-female ratio was 1:1.04. The most common age group affected by SK was 60 years and above (40%). The most common clinical variant was common seborrheic keratosis (CSK) (60%). Comedo-like openings (CL) (80%), fissures and ridges (FR) (52%), and sharp demarcation (SD) (83%) were consistent finding on dermoscopy in CSK. Dermatosis papulosa nigra (DPN) and pedunculated seborrheic keratoses (PSK) had characteristic CL and FR in both of them. Fingerprint (FP) (55%) and network-like (NL) (88%) structures were commonly seen in flat SK. Stucco keratoses demonstrated SD (100%) and NL structures (100%).

Kwon et al<sup>11</sup> analyzed 303 male patients with SKs and reported that SKs were more prevalent on exposed sites than on partly exposed sites and that the mean number of SKs was higher on exposed areas than on partly exposed areas. However, Gill et al<sup>12</sup> investigated 170 Australian SK patients aged 15 to 30 years and found that SKs appeared more frequently on the trunk than on the limbs, head, and neck. They explained this contrasting finding as a reflection of the changing sunlight-exposure patterns of the younger community; truncal exposure is now almost as great as for traditional light-exposed areas.

Alpatt et al<sup>13</sup> found that the most common age group affected by SK was 31-50 years (42%). A female preponderance of 76% was seen. Majority of our patients had a positive family history (62%), though Sun exposure was not seen to be a major factor. The most common clinical variant was common SK (CSK) (46%). The most common dermoscopic findings seen in CSK were comedo-like (CL) openings, fissures and ridges (FR), and milia-like (ML) cysts. Dermatosis papulosa nigra and pedunculated SK had characteristic FR and CL openings on dermoscopy. Stucco keratoses showed network-like (NL) structures and sharp demarcation. CL opening on dermoscopy corresponded to papillomatosis and pigmentation, ML cysts corresponded to horn cysts, FR corresponded to papillomatosis, and NL structures corresponded to an increase in basal layer pigmentation.

## CONCLUSION

Authors found that lesions were common seborrheic keratosis, Dermatosis papulosa nigra and Pedunculated seborrheic keratoses. Females were commonly involved than males.

## REFERENCES

1. Kwon OS, Hwang EJ, Bae JH, Park HE, Lee JC, Youn JI, et al. Seborrheic keratosis in the Korean males: Causative role of sunlight. *Photodermatol Photoimmunol Photomed* 2003;19:73-80.
2. Noiles K, Vendor R. Are all seborrheic keratoses benign? Review of the typical lesion and its variants. *J Cutan Med Surg* 2008;12:203-10.
3. Kopf AW, Rabinovitz H, Marghoob A, Braun RP, Wang S, Oliviero M, et al. "Fat fingers:" a clue in the dermoscopic diagnosis of seborrheic keratoses. *J Am Acad Dermatol* 2006;55:1089-91.
4. Mackie RM, Quinn AG. Non-melanoma skin cancer and other epidermal skin tumours. In: Burns T, Breathnach S, Cox N, Griffiths C, editors. *Rook's Textbook of Dermatology*. 7th ed. Oxford: Blackwell Publishing; 2004. p. 36.1-36.50.
5. Braun RP, Rabinovitz HS, Krischer J, Kreusch J, Oliviero M, Naldi L, et al. Dermoscopy of pigmented seborrheic keratoses: A morphological study. *Arch Dermatol* 2002;138:1556-60.
6. Yeatman JM, Kilkenny M, Marks R. The prevalence of seborrheic keratoses in an Australian population: Does exposure to sunlight play a part in their frequency? *Br J Dermatol* 1997;131:411-4.
7. Thomas VD, Swanson NA, Lee KK. Benign epithelial tumors, hamartomas and hyperplasias. In: Wolff K, Goldsmith LA, Katz SI, Gilchrist BA, Paller AS, Leffell D, editors. *Fitzpatrick's Dermatology in General Medicine*. 7th ed. New York: McGraw- Hill; 2008. p. 1054-67.
8. Malvey J, Puig S, Braun RP, Marghoob AA, Kopf AW, editors. *Handbook of dermoscopy*. 1st ed. London: Taylor and Francis; 2006. p. 10-20.
9. Roh NK, Hahn HJ, Lee YW, Choe YB, Ahn KJ. Clinical and histopathological investigation of seborrheic keratosis. *Annals of dermatology*. 2016 Apr;28(2):152.
10. Rajesh G, Thappa DM, Jaisankar TJ, Chandrashekar L. Spectrum of seborrheic keratoses in south Indians: A clinical and dermoscopic study. *Indian J Dermatol Venereol Leprol* 2011;77:483-8.
11. Kwon OS, Hwang EJ, Bae JH, Park HE, Lee JC, Youn JI, et al. Seborrheic keratosis in the Korean males: causative role of sunlight. *Photodermatol Photoimmunol Photomed*. 2003;19:73-80.
12. Gill D, Dorevitch A, Marks R. The prevalence of seborrheic keratoses in people aged 15 to 30 years: is the term senile keratosis redundant? *Arch Dermatol*. 2000;136:759-762.
13. Alpatt GF, Sukumar D, Bhat M R. A clinicopathological and dermoscopic correlation of seborrheic keratosis. *Indian J Dermatol* 2016;61:622-7.