

## *Original Article*

### **Comparison of Lichtenstein method of hernioplasty and Preperitoneal Meshplasty in Inguinal Hernia- A Clinical Study**

Ramesh Chandra Awasthi,

Associate Professor, Department of Surgery, Mulayam Singh Yadav Medical College & Hospital, Meerut, Uttar Pradesh

#### **ABSTRACT:**

**Background:** Inguinal hernias account for 75% of abdominal wall hernias. Lichtenstein method of hernioplasty and preperitoneal meshplasty are commonly used methods for management of hernia. **Materials & Methods:** The present study was conducted on 140 cases of lingual hernia of both genders (males- 82, females- 58). Patients were divided into 2 groups. Group I (70) was managed with Lichtenstein's hernioplasty and group II (70) was managed with preperitoneal meshplasty. Time taken for surgery, early complications and late complications etc. were recorded. **Results:** Out of 70 patients in group I, males were 48 and females were 32. In group II, males were 34 and females were 26. The difference was significant ( $P < 0.05$ ). Mean time taken in group I patients was 46.2 minutes and in group II was 50.5 minutes. The difference was non-significant ( $P > 0.05$ ). Early complication were seroma (2) in group I, wound infection 1 case each in group I and II, testicular atrophy in group I (2) and group II (1), mesh infection 1 in group I and post-operative pain in group I (2) and group II (4). Late complications were chronic pain in group I (5) and group II (1), recurrence in group I (2) and group II (1) and sinus formation in group II (1). **Conclusion:** Both techniques found to be equally effective. However, the selection of specific technique should be done cautiously.

**Key words:** Hernia, hernioplasty, Lingual

Received: 16 August 2018

Revised: 25 September 2018

Accepted: 28 September 2018

**Corresponding Author:** Dr. Ramesh Chandra Awasthi, Associate Professor, Department of Surgery, Mulayam Singh Yadav Medical College & Hospital, Meerut, Uttar Pradesh

**This article may be cited as:** Awasthi RC. Comparison of Lichtenstein method of hernioplasty and Preperitoneal Meshplasty in Inguinal Hernia- A Clinical Study. J Adv Med Dent Scie Res 2018;6(10):105-107.

#### **INTRODUCTION**

Hernia is mainly defined as a protrusion, bulge or projection of an organ or a part of an organ through the body wall that normally contains it. Inguinal hernias account for 75% of abdominal wall hernias, with a prevalence of 1.7% for all ages and 4% for those aged over 45 years. It is more common on the right than on the left with a ratio of 2:1. Inguinal hernia is much more common in men than women. The inguinal region is a locus of minor resistance in the abdominal wall.<sup>1</sup> Hernias in this area occur in the space described as the myopectineal orifice. This area is limited from the top and medially by connecting tendon and rectus abdominis muscle, from below by pecten ossis pubis and from laterally by the iliopsoas muscle. Inguinal hernias are a specific group of hernias because of their frequency of occurrence as well as the dynamic development of repair methods.<sup>2</sup>

The risk factors exist for the development of inguinal hernias reported to be associated with increased risk for both sexes include smoking, which causes a defective connective tissue metabolism, chronic obstructive pulmonary disease and heavy lifting. Among women it's considered that rural residence, greater height, and umbilical hernia were risk factors for inguinal herniation. It was reported that factors such as lower body-mass index, high intra-abdominal pressure, collagen vascular disease, thoracic or abdominal aortic aneurysm, patent processus vaginalis, history of open appendectomy, and peritoneal dialysis are also risk factors for inguinal hernia. Lichtenstein method of hernioplasty and preperitoneal meshplasty are commonly used methods for management of hernia.<sup>3</sup> The present study aimed at comparing both methods.

**MATERIALS & METHODS**

The present study was conducted in the department of general surgery. It comprised of 140 cases of lingual hernia of both genders (males- 82, females- 58). All were informed regarding the study and written consent was obtained. General information such as name, age, gender etc was recorded. Patients were divided into 2 groups.

Group I (70) was managed with Lichtenstein’s hernioplasty and group II (70) was managed with preperitoneal meshplasty. Time taken for surgery, early complications and late complications etc. were recorded. Results thus obtained were subjected to statistical analysis. P value less than 0.05 was considered significant.

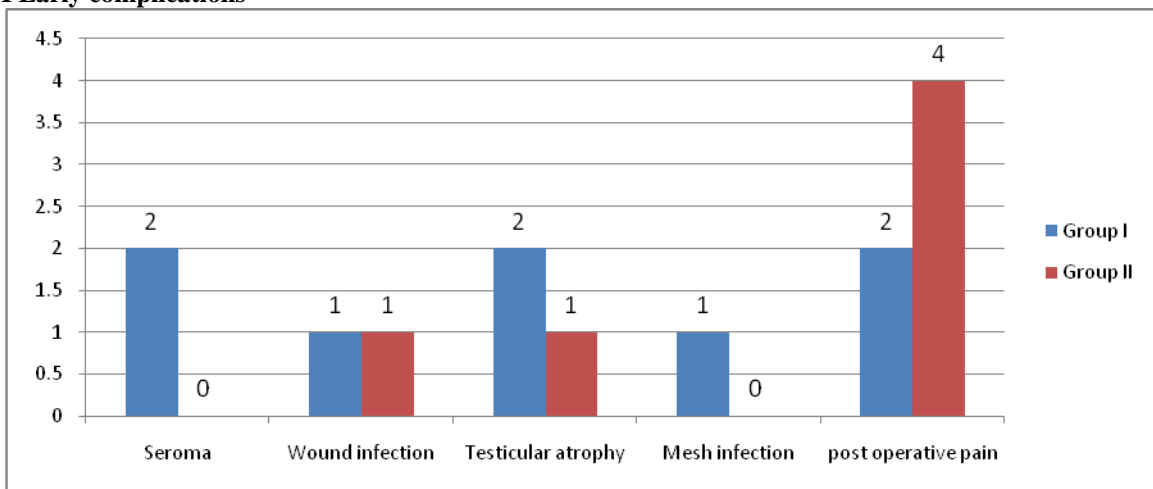
**RESULTS**

**Table I Distribution of patients**

Groups	Group I (Lichtenstein’s hernioplasty)	Group II (Preperitoneal meshplasty)	P value
Number	70	70	
Gender (M:F)	48:32	34:26	0.05
Time for surgery	46.2 mins	50.5 mins	0.1

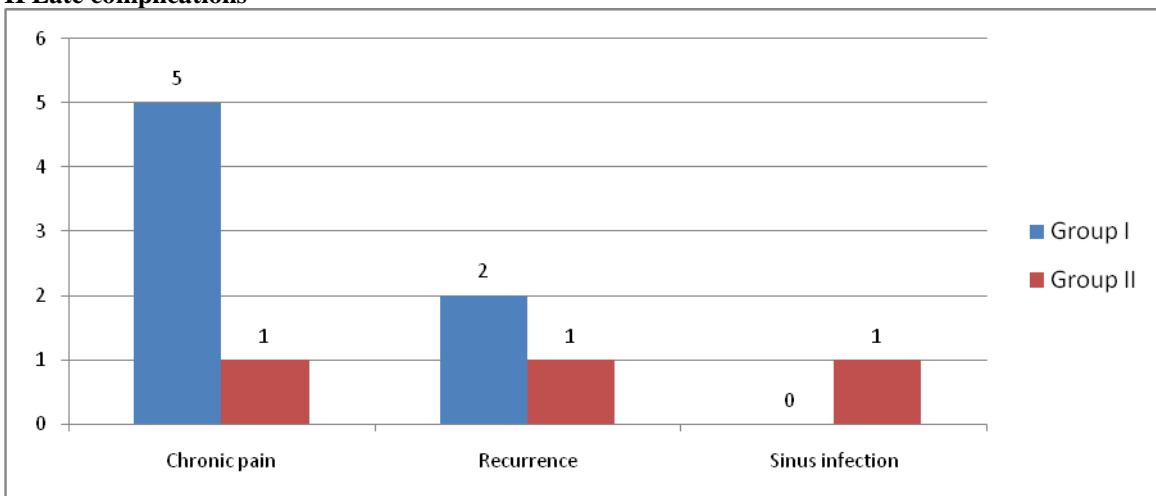
Table I shows that out of 70 patients in group I, males were 48 and females were 32. In group II, males were 34 and females were 26. The difference was significant (P< 0.05). Mean time taken in group I patients was 46.2 minutes and in group II was 50.5 minutes. The difference was non- significant (P>0.05).

**Graph I Early complications**



Graph I shows that early complication were seroma (2) in group I, wound infection 1 case each in group I and II, testicular atrophy in group I (2) and group II (1), mesh infection 1 in group I and post- operative pain in group I (2) and group II (4). The difference was non- significant (P> 0.05).

**Graph II Late complications**



Graph II shows that late complications were chronic pain in group I (5) and group II (1), recurrence in group I (2) and group II (1) and sinus formation in group II (1). The difference was non-significant ( $P > 0.05$ ).

## DISCUSSION

The number of cases is on rise. A correct operation of inguinal hernia is one of the basic skills of every surgeon. Therefore, it is vital to make a choice of the best treatment method, creating a standard procedure based on reliable and current publications, with the economic aspect considered. Currently, according to the American College of Surgeons, the Lichtenstein technique is considered the gold standard.<sup>4</sup> It is based on sewing in a synthetic material (mesh), which fulfils defect of tissue in the inguinal canal posterior wall area, reaching beyond Hasselbach's triangle (after the surgery the mesh becomes reduced by about 20% in each direction). The Lichtenstein technique is frequently performed within one-day surgery which allows reduction of treatment costs. It is also important that the percentage of recurrences and complications is low.<sup>5</sup>

Tissue repair methods have now become obsolete and replaced by tension free prosthesis repair. This can be done by anterior approach or posterior approach. Mesh repairs are superior to "nonmesh" tissue-suture repairs. In laparoscopic repair mesh placement is in preperitoneal plane. The approach may be TAPP (transabdominal preperitoneal) or TEP (totally extraperitoneal). It is associated with longer learning curve and is costlier than open repair.<sup>6</sup>

We observed that out of 70 patients in group I, males were 48 and females were 32. In group II, males were 34 and females were 26. Mean time taken in group I patients was 46.2 minutes and in group II was 50.5 minutes. This is similar to Karthikesalingam et al.<sup>7</sup>

Fenoglio ME et al<sup>8</sup> conducted a study in which all the patients operated electively for uncomplicated inguinal hernia over a period of one year were selected for the study. They were operated by various methods and followed. There were total 130 cases of inguinal hernia repair during study period. 160 cases were operated by Lichtenstein method of hernioplasty, 17 by Preperitoneal meshplasty and 13 by TEP. Lichtenstein repair and endoscopic/laparoscopic techniques have similar efficacy. It is found that Lichtenstein's tension free repair is standard and cost effective.

We found that early complication were seroma (2) in group I, wound infection 1 case each in group I and II, testicular atrophy in group I (2) and group II (1), mesh infection 1 in

group I and post-operative pain in group I (2) and group II (4). Late complications were chronic pain, recurrence and sinus formation.

Kulacoglu H et al<sup>9</sup> conducted a study in which seven hundred and ninety-three operations were performed: Lichtenstein technique was carried out in 301 patients (37.9%), mesh-plug in 325 patients (40.9%) and PHS in 167 patients (21.2%). Spinal anaesthesia was performed in 787 patients (99.2%). General anaesthesia was necessary in 6 patients (0.8%) due to degeneration of the vertebral column. Complications observed include: wound suppuration, haematoma and seroma formation, chronic pain and hernia recurrence. Patients were discharged on the first postoperative day. Return to physical activity was observed usually 14 days after the operation.

## CONCLUSION

Both techniques found to be equally effective. However, the selection of specific technique should be done cautiously.

## REFERENCES

1. Ruhl CE, Everhart JE.: Risk factors for inguinal hernia among adults in the US population. *Am J Epidemiol* 2007; 165:1154–1161.
2. George H Sakorafas, Ioannis Halikias, Christos Nissotakis, Nikolaos Kotsifopoulos, Alexios Stavrou, Constantinos Antonopoulos and George A Kassaras: Open tension free repair of inguinal hernias; the Lichtenstein technique. *BMC Surg*. 2001; 1:3.
3. Aasvang E, Kehlet H. Chronic postoperative pain: the case of inguinal herniorrhaphy. *Br J Anaesth* 2005; 95: 69-76.
4. Lau H, Patil NG, Yuen WK. Day-case endoscopic totally extraperitoneal inguinal hernioplasty versus open Lichtenstein hernioplasty for unilateral primary inguinal hernia in males: A randomized trial. *Surg Endosc*. 2006; 20(1):76-81.
5. Reid I, Devlin HB. Testicular atrophy as a consequence of inguinal hernia repair. *BJS*. 2005; 81:91–93.
6. Ibingira CB. Long term complications of inguinal hernia repairs. *East Afr Med J*. 1999; 76(7):396–399.
7. Karthikesalingam A, Markar SR, Holt PJ, Praseedom RK. Meta analysis of randomized controlled trials comparing laparoscopic with open mesh repair of recurrent inguinal hernia. *Br J Surg*. 2010; 97:4–11
8. Fenoglio ME, Bermas HR, Haun WE, Moore JT. Inguinal hernia repair: results using an open preperitoneal approach. *Hernia* 2005; 9(2):160-1.
9. Kulacoglu H. Current options in inguinal hernia repair in adult patients. *Hippokratia* 2001; 15(3):223–231.

Source of support: Nil

Conflict of interest: None declared

This work is licensed under CC BY: *Creative Commons Attribution 3.0 License*.