

ORIGINAL ARTICLE

Morphometric assessment of mandibles and iliac crests: A comparative study

Vimal Modi

Associate Professor, Department of Anatomy, Amaltas Institute of Medical Sciences, Dewas, Madhya Pradesh, India


ABSTRACT:

Background: In the past literature, positive correlation has been reported between bone mass in ribs, vertebrae and iliac crest. Hence; we planned the present study to comparatively evaluate the cortical bone mass and cortical width at a standard site of the mandible with that in the iliac crest. **Materials & methods:** The present study included assessment of 20 cadavers who have died in recent past and have been deposited to the department of human anatomy. Specimen materials were extracted from lower jaw two mm anterior to the mental foramen. Width of the measurement and the mean cortical width (MCW) were obtained. Another set of two specimens was obtained in a similar way, as done in case of mandibular specimen, from the iliac crest. All the results were analysed by SPSS software. **Results:** 87.1 percent was the mean bone mass observed in the entire cortical plate of mandibular cortices. The mean bone mass of the entire cortical plate in the iliac crest cortex was found to be 86.1 percent. Significant results were obtained while correlating the age and mean bone mass in the sub-periosteal and sub-endosteal cortex. **Conclusion:** Iliac crest specimens cannot predict mandibular canal porosity.

Key words: Morphometric, Occipital, Skull.

Corresponding author: Dr. Vimal Modi, Associate Professor, Department of Anatomy, Amaltas Institute of Medical Sciences, Dewas, Madhya Pradesh, India

This article may be cited as: Modi V. Morphometric assessment of mandibles and iliac crests: A comparative study. J Adv Med Dent Scie Res 2017;5(9):94-96.

Access this article online	
<p>Quick Response Code</p> 	Website: www.jamdsr.com
	DOI: 10.21276/jamdsr.2017.5.9.22

INTRODUCTION

The examination of Bone Mineral Density Distribution (BMDD) in human bone biopsies has propelled the comprehension of how bone turnover relates with different known pathologies and medications meant to improve bone density.¹⁻⁴ Although the utility of BMDD in human bone biopsies has profited from an advancement in methods, the examination of the same in a little creature display has been moderate being developed, particularly, in the craniofacial skeleton.⁵ A positive correlation has been observed in the past literature in between bone mass in ribs, vertebrae and iliac crest.⁶⁻⁸ Hence; we planned the present study to comparatively evaluate the cortical bone mass and cortical width at a standard site of the mandible with that in the iliac crest.

MATERIALS & METHODS

The present study was conducted in the department of human anatomy and forensic medicine of the medical institute and included assessment of 20 cadavers who have died in recent past and have been deposited to the department of human anatomy. Ethical approval was taken from institutional ethical committee and written consent was obtained from institution after explaining in detail the entire research protocol. Complete detailed medical and clinical histories of all the cadavers were

recorded and were divided on the basis of age and gender. Specimen materials were extracted from lower jaw two mm anterior to the mental foramen. These specimens consisted of buccal cortical plate and corresponded to cylindrical specimen with 5 mm diameter. All these specimens were obtained while performing autopsy. Two straight one mm apart specimens were obtained from mandibular specimens. 100 micrometer thick ground sections were obtained from them. Bone mass was calculated which represented the percentage of area of cortical bone. Width of the measurement and the mean cortical width (MCW) were obtained and the dimensions were expressed in μm . measurement of the length of the cortical areas was also done. Estimation of bone mass in the remaining cortical area was also done. Another set of two specimens was obtained in a similar way, as done in case of mandibular specimen, from the iliac crest. Amount of trabecular bone was expressed in terms of percentage of area of the bone marrow in the iliac crest. All the results were analysed by SPSS software. Chi-square test and student t test were used for assessment of level of significance. P- Value of less than 0.05 was taken as significant.

RESULTS

Mean bone mass observed in the subperiosteal and sub-endosteal layer of mandibular cortices was found to be

93.2 and 85.7 percent respectively. 87.1 percent was the mean bone mass observed in the entire cortical plate of mandibular cortices (**Table 1, Graph 1**). In the iliac crest cortices, the mean bone mass at sub-periosteal and sub-endosteal layer was found to be 87.8 and 83.7 respectively. The mean bone mass of the entire cortical plate in the iliac crest cortex was found to be 86.1 percent. Significant results were obtained while correlating the age and mean bone mass in the sub-periosteal and sub-endosteal cortex (**P- value < 0.05**) (**Table 2**).

Table 1: Mean value of bone mass (percentage) in sub-periosteal layer, sub-endosteal layer and entire cortical plate in mandibular, iliac crest and in trabecular bone of iliac crest (A and B)

Bone	Measure area	Mean bone mass (%)
Cortices of mandible	Sub-periosteal layer	93.2
	Sub- endosteal layer	85.7
	Entire cortical plate	87.1
Cortices of iliac crest	Sub-periosteal layer	87.8
	Sub- endosteal layer	83.7
	Entire cortical plate	86.1
Trabecular bone of iliac crest	A	12.5
	B	14.3

Graph 1: Descriptive presentation of mean value of bone mass (percentage) in sub-periosteal layer, sub-endosteal layer and entire cortical plate in mandibular, iliac crest and in trabecular bone of iliac crest (A and B)

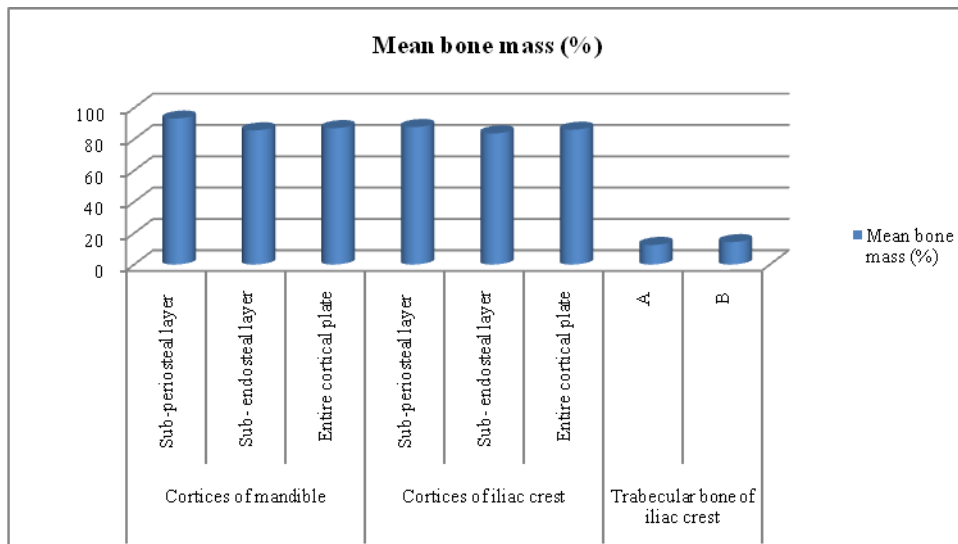


Table 2: Comparison of age and the mandibular and iliac variables

Bone	Measure area	Correlation	p- value
Mandible	Sub-periosteal layer	Age/ bone mass	0.02*
	Sub- endosteal layer	Age/ bone mass	0.03*
	Entire cortical plate	Age/ MCW	0.25
Iliac crests	Sub-periosteal layer	Age/ bone mass	0.14
	Both cortical areas	Age/ bone mass	0.01*
	Trabecular bone area	Age/ MCW	0.04*

*: Significant

DISCUSSION

In the present study, we observed that iliac crestal biopsy tissue does not predict the mean bone mass and cortical width in the mandibular bone (**Table 1, Table 2**). TahaSönmez T et al assessed the morphological characteristics and dimensions of the ilium and fibula to evaluate the suitability of particular areas of bone for use as donor sites for dental reconstructions that carry implants. They measured the dimensions of 130 bilaterally harvested ilium and fibula bones from 65 adult cadavers using osteometric methods, and analysed the effects of age, sex, and side. Dimensions at measuring points, overall suitability for implantation, and relations among age, sex, and side, were evaluated statistically. They report observations of bone morphology involving cross-sections, and clinical relevance. Although the mean dimensions of the fibula and iliac crest were adequate, some segments would not support an implant 10 mm

long and 3.5 mm wide. The overall suitability of parts of the iliac block fell to 30%. Fibular morphology is characterised by constant height and width, and relation of cortical and cancellous bone. Bony dimensions on the iliac fossa and fibula were significantly greater in men than in women. Age had a negative impact in one area of the iliac fossa, but nowhere on the iliac crest. Side was not significant. They found differences in dimensions and morphology between measuring points on the same bone. Precise knowledge about which areas of the donor sites can reliably provide sufficient bone to carry implants after reconstructions will allow greater flexibility and safety when reconstructions are designed.⁹ Wower NV et al conducted a comparative analysis of bone mass in the mandible and the iliac crest in autopsy specimens from 30 subjects aged 23–84 years. Microradiograms of standardized 100- μ m-thick sections of the undemineralized plastic embedded material from the two locations were used for quantitation. The following measurements were carried out by electronic point-counting: 1) the percentage of cortical bone mass in the subperiosteal and subendosteal layers, 2) mean cortical width, and 3) the percentage of trabecular bone mass in the iliac crest. Positive correlations were found in the expressions of bone mass within the mandible; the values were significantly higher in the 200- μ m-thick subperiosteal layer than in the remaining part of the mandibular cortex. Only a poor or no correlation was found in the expressions of bone mass from the two sites. The investigation, therefore, shows that bone mass and cortical width in the mandible cannot be predicted from a biopsy from the iliac crest. This finding may partly be due to different age-dependent functional changes of the two bones.¹⁰ Wower NV et al examined the precision in vitro and in vivo and the accuracy in vivo for assessment of Bone mineral content (BMC) in the maxilla. The precision was determined by repeated measurements in vitro on a cranium and in vivo on two test persons with and without a bone specimen fixed to a palatal plate. The accuracy in vivo was determined from the BMC measurements of the two test persons and of nine edentulous persons, scanned before and after augmentation of the maxillary alveolar ridge with hydroxyapatite. The analyses indicated that the precision for maxillary BMC assessments was high (0.9% in vitro and 2.0% in vivo) and the accuracy in vivo was 6.6%, corresponding to the accuracy in vitro for skeletal BMC measurements by dual-photon absorptiometry. The present method therefore seems to be well-suited for follow-up analyses of the BMC changes in the jaws after augmentation of the alveolar ridges with bone or hydroxyapatite.¹¹ Lumetti S et al compared the outcome of fresh-frozen versus autologous bone block grafts for horizontal ridge augmentation in patients with Cawood and Howell class IV atrophies. Seventeen patients received autologous grafts and 21 patients received fresh-frozen bone grafts. Patients underwent CT scans 1 week and 6 months after surgery for graft volume and density

analysis. Two autologous and 3 fresh-frozen grafts failed. Autologous and fresh-frozen grafts lost, respectively, 28% and 46% of their initial volume ($P = 0.028$). It is noteworthy that less dense fresh-frozen blocks lost more volume than denser grafts (61% versus 16%). According to these 6-month results, only denser fresh-frozen bone graft may be an acceptable alternative to autologous bone for horizontal ridge augmentation.¹²

CONCLUSION

From the above results, the authors concluded that iliac crest specimens cannot predict mandibular canal porosity. However, future studies are recommended.

REFERENCES

1. Quinn JMW, Neale S, McGee JOD, Athanasou NA. Human osteoclast formation from blood monocytes, peritoneal macrophages, and bone marrow cells. *Calcif Tissue Int.* 1998;62:527–531.
2. Jacquin C, Gran DE, Lee SK, Lorenzo JA, Aguila HL. Identification of multiple osteoclast precursor populations in murine bone marrow. *J Bone Miner Res.* 2006;21:67–77.
3. Vries TJ, Schoenmaker T, Hooibrink B, Leenen PJ, Everts V. Myeloid blasts are the mouse bone marrow cells prone to differentiate into osteoclasts. *J Leukoc Biol.* 2009;85:919–927.
4. Everts V, Vries TJ, Helfrich MH. Osteoclast heterogeneity: lessons from osteopetrosis and inflammatory conditions. *Biochim Biophys Acta.* 2009;1792:757–765.
5. Tchanque-Fossuo CN, Donneys A, Deshpande SS, Farberg AS, Nelson NS, Boguslawski MJBS. Amifostine Mitigates the Untoward Effects of Radiation on the Mineralization Capacity of Irradiated Bone in the Murine Mandible. *Plastic and reconstructive surgery.* 2011;127(5S):83.
6. Bergot C, Wu Y, Jolivet E, et al.; The degree and distribution of cortical bone mineralization in the human femoral shaft change with age and sex in a microradiographic study. *Bone.* 2009 45(3):435–42.
7. Misof BM, Paschalis EP, Blouin S, et al.; Effects of 1 year of daily teriparatide treatment on iliac bone mineralization density distribution (BMDD) in postmenopausal osteoporotic women previously treated with alendronate or risedronate. *Journal of bone and mineral research : the official journal of the American Society for Bone and Mineral Research.* 2010 25(11):2297–303.
8. Monson L, Farberg A, Jing L. [Accessed August 2, 2010]; Human Equivalent Radiation Dose Response in the Rat Mandible. *Plastic and.* 2009 124(4S):2
9. Tolga TahaSönmez et al. Comparative clinicoanatomical study of ilium and fibula as two commonly used bony donor sites for maxillofacial reconstruction. *British Journal of Oral and Maxillofacial Surgery.* 2013; 51(8): 736-741.
10. Wower NV, Melsen F. Comparative bone morphometric analysis of mandibles and iliac crests. *European Journal of Oral Sciences.* 1979; 87(5): 351- 357.
11. Wower NV, Worsaae N. Bone Mineral Content of the Maxilla Estimated by Dual-photon Absorptiometry after Augmentation with Bone or Hydroxyapatite. *J Dent Res.* 1988; 67(11): 67- 69.
12. Lumetti S, Galli C et al. Correlation between Density and Resorption of Fresh-Frozen and Autogenous Bone Grafts. *Biomed Res Int.* 2014; 2014: 508328.

Source of support: Nil

Conflict of interest: None declared

This work is licensed under CC BY: *Creative Commons Attribution 3.0 License.*