

## Case Report

### Prosthetic Rehabilitation of a Marginal Mandibulectomy patient with a Cast Partial Denture: A Case Report

<sup>1</sup>Tridib Nath Banerjee, <sup>2</sup>Subhas Chakraborty, <sup>3</sup>Rajarshi Banerjee

<sup>1</sup>Assistant Professor, <sup>2</sup>Associate Professor, Dept of Prosthetic Dentistry, North Bengal Dental College & Hospital, Darjeeling, India;

<sup>3</sup>Professor, Dept of Oral & Maxillofacial Surgery, Haldia Institute of Dental Sciences & Research, Haldia, India

#### ABSTRACT:

Prosthetic management of intra-oral postsurgical defect is a big challenge for any prosthodontist. Marginal Mandibulectomy patient presents with various problems because of deviation of mandible on affected side, obliteration of buccal and lingual vestibule and macroglossia. Main objectives of treatment is to preserve remaining teeth and supporting structures, improvement of mastication and restoration of esthetics, health and quality of life of the patient. The treatment options for such patients are surgical reconstruction of resected part and or prosthetic rehabilitation. This case report describes the fabrication of a removable cast partial denture for a patient with marginal mandibulectomy in anterior and posterior edentulous area.

**Keywords:** Marginal Mandibulectomy, Partial edentulism, Cast Partial Denture.

Received: 08 July, 2022

Accepted: 13 August, 2022

**Corresponding author:** Tridib Nath Banerjee, Assistant Professor, Dept of Prosthetic Dentistry, North Bengal Dental College & Hospital, Darjeeling, India

**This article may be cited as:** Banerjee TN, Chakraborty S, Banerjee R. Prosthetic Rehabilitation of a Marginal Mandibulectomy patient with a Cast Partial Denture: A Case Report. J Adv Med Dent Res 2022;10(9):1-4.

#### INTRODUCTION

The integral part of human masticatory apparatus essential for normal function and pleasing esthetics are the teeth. Every individual has a desire to possess a full complement of healthy teeth. Surgical procedures are used for the eradication of pathological conditions occurring in jaw. In partial resection, a tumor is removed by resecting a full thickness portion of the jaw; in the mandible this can vary from a small continuity defect to a hemi mandibulectomy, where the jaw continuity is disrupted [1]. Whereas in marginal mandibulectomy, a tumor resection is done without disruption of the continuity of the bone [1,2,3,4]. In such situations rehabilitation of the patient can be done with cast partial denture, where the remaining teeth present in the normal side of the mandible are healthy and stable, which could be used for retention and support.

Usually mandibular deviation occurs due to unilateral mandibular discontinuity defects caused by surgery or trauma, resulting in lack of occlusion and altered maxilla-mandibular relationship [3,4]. The success in rehabilitating a patient with hemi-mandibulectomy depends upon the nature and extent of surgical defect,

treatment plan, type of prosthesis and patient cooperation [3]. This case report describes the fabrication of definitive cast partial denture in a patient who had undergone marginal mandibulectomy with reconstruction with split thickness skin graft due to squamous cell carcinoma and reported with obliteration of buccal and lingual vestibule. As the lower border of the mandible was kept intact during surgery, which resulted in minimum deviation so a guiding restoration with the cast partial denture was not considered necessary.

#### CASE REPORT

A 45 yrs. old, male patient reported to the Department of Prosthetic Dentistry with missing teeth on the left side of lower jaw. His chief complaint was difficulty in chewing and speech. He had a history of undergoing marginal mandibulectomy in the left side of jaw for treatment of underlying well differentiated squamous cell carcinoma 2 years back. Medical history did not reveal any history of radiotherapy after surgery. On intraoral examination revealed (Kennedy class 2) partial edentulous situation with a long span on one side and a short span on the other due to loss

of mandibular anterior and posterior teeth on entire left side of the arch and central and lateral incisor teeth missing on the right side of the arch (figure 1,2). There was obliteration of buccal and lingual vestibule due to reconstruction of the defect with split thickness skin graft. An orthopantomogram further revealed the status of the remaining teeth and bone, which were quiet sound and healthy. Diagnostic casts were prepared for further evaluation of the case. On the basis of clinical examination and the study of diagnostic casts it was concluded that the vertical dimension of occlusion was within permissible limits and was desirable. Moreover, the case was a lengthy edentulous span with excessive bone loss and poor prognosis for complete denture due to residual ridge morphology. A decision regarding treatment was taken in this case for a planned cast partial denture in order to restore esthetics and function.

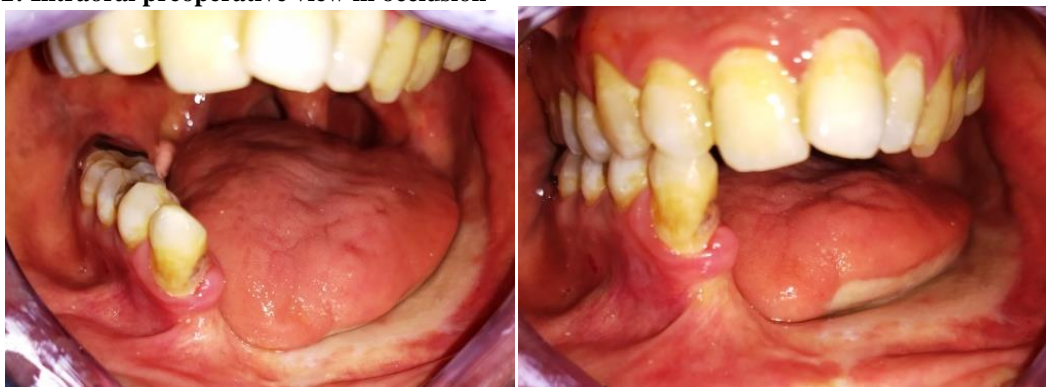**PROCEDURE**

Primary cast obtained for diagnostic evaluation was surveyed on a dental cast surveyor and four principal factors were evaluated, namely the path of insertion

and removal, aesthetic, interferences and guiding planes. Occlusal rest seats were prepared on mandibular right canine, first and second premolar and first molar with a round bur. Mouth preparations were then done in the next appointment following which final impressions were made using putty wash impression (Figure 3). A definitive cast made of die stone was made and surveyed. Refractory casts were made and the wax pattern was fabricated on it (Figure 4). The frame work was cast and evaluated intraorally and adjusted wherever needed (Figure 5). The metal framework for the RPD was then tried in the patient's mouth. Maxillomandibular relation was established, acrylic teeth were arranged and try in was done. Being satisfied with the esthetic and functional requirements, the denture was processed in heat cure acrylic resin. After finishing and polishing, the denture was inserted (Figure 6, 7,8) and post insertion instructions were given. The patient was advised to report every six months for check up. At every recall visit the teeth were to be examined thoroughly to see the condition and status of the remaining natural teeth and also the cast partial denture.


**Figure 1: Intraoral preoperative view open mouth**

**Figure 2: Intraoral preoperative view in occlusion**



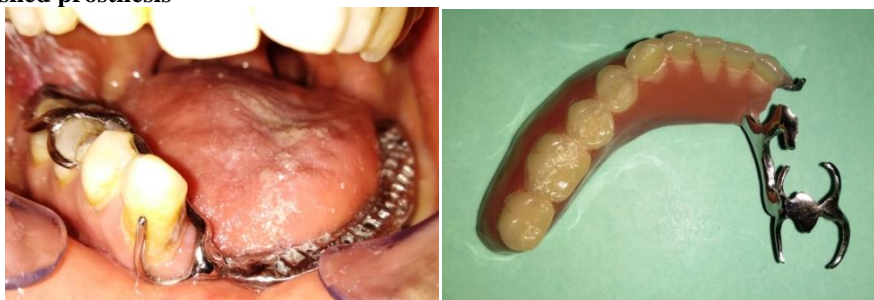**Figure 3: Impression of the defect**

**Figure 4: Wax pattern design of the framework**



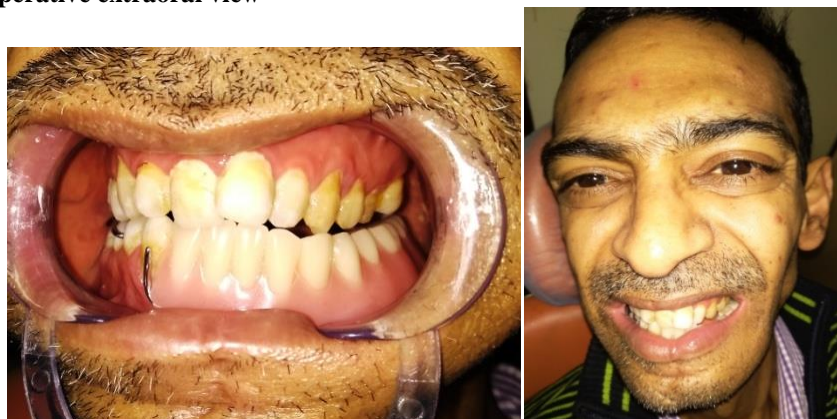
**Figure 5: Intraoral view of framework trial**

**Figure 6: Finished prosthesis**



**Figure 7: Postoperative intraoral view of finished prosthesis**

**Figure 8: Postoperative extraoral view**



## DISCUSSION

Present day maxillofacial surgery offers a wide range of good results in treatment of oral cancer. Depending upon the situation and extent of the tumor within the mandible, various surgery modalities like marginal, segmental, hemi, subtotal, or total mandibulectomy are often performed[2]. In marginal mandibulectomy cases the inferior border is intact and normal movements can be expected to occur. However, obliteration of buccal and lingual vestibule due to closure of defect with split thickness skin graft poses a major prosthodontic challenge[4,5]. This case report describes functional rehabilitation of marginal mandibulectomy patient who has undergone resection without reconstruction with a cast partial denture. Main objectives of treatment were focused on preservation of remaining teeth and supporting structures, improvement of mastication and restoration of health, comfort and quality of life of the patient[6,7]. In prosthetic dentistry, patients do not want to wear a removable partial denture due to various reasons like fear of becoming loosening of the denture, swallowing, hygiene and convenience. The significant motivation for this patient came when he was explained and understood about the cross-arch support and stabilization that was unique to the cast partial denture[4,8]. For a cast partial denture to be successful for a patient, the practitioner has to show determination in terms of making his patients understand the benefits of such treatment option.

## CONCLUSION

A cast partial removable denture is an outstanding mode of treating partially edentulous jaw where few teeth are lost due to various reasons including hemimandibulectomy. The remaining natural teeth that are used for support and retention are of critical importance for maintenance of health. A breakdown in their structure or problem in their periodontal support negates the treatment with cast partial denture. If we can control periodontal disease by periodontal therapy and proper home care regimen and can also control caries by home care and preventive measures, we can be relatively assured of a successful outcome for many years with treatment of patients with cast partial removable denture.

## ACKNOWLEDGEMENT

None.

## CONFLICTS OF INTEREST

None.

## SUPPORT

Nil

## REFERENCES

1. Beumer J, Marunick MT, Curtis TA, Roumanas E. Acquired defects of the mandible. In, Bemer J(ed). Maxillofacial Rehabilitation: Prosthodontic and Surgical Consideration, 1st edition St. Louis. Euro America, 1996;201.

2. Jacob RF, Prosthodontic rehabilitation of the mandibulectomy patient. In, Taylor TD(ed). *Clinical Maxillofacial Prosthetics*, 1st edition. Illinois. Quintessence Publishing, 1997;171-172.
3. Cantor R, Curtis TA. Prosthetic management of edentulous mandibulectomy patients: Part II, Clinical procedures. *J Prosthet Dent* 1971; 25: 546-555
4. Carr AB, McGivney GP, Brown DT. *McCracken's Removable Partial Prosthodontics*. Elsevier Health Sciences. 11th ed. Mosby, St. Luis, Missouri; 2005.
5. Arie Shifman, James B. Lepley, Prosthodontic management of postsurgical soft tissue deformities associated with marginal mandibulectomy. Part I: Loss of the vestibule, *J Prosthet Dent* 1982; 48: 178-183
6. Basker RM, Harrison A, Davenport JC, Marshall JL. Partial denture design in general dental practice--10 years on. *Br Dent J*. 1988 Oct 8;165(7):245-9.
7. De Rossi A, Albuquerque RF Jr, Bezzon OL. Esthetic options for the fabrication of removable partial dentures: a clinical report. *J Prosthet Dent*. 2001 Nov;86(5):465-7.
8. Ben-Ur Z, Gorfil C, Shifman A. Designing clasps for the asymmetric distal extension removable partial denture. *Int J Prosthodont*. 1996 Jul-Aug;9(4):374-8.