

CASE REPORT

Aesthetic Rehabilitation of the Patient with Enamel Hypoplasia and Malformation in Anterior Teeth

Hakan Kamalak¹, Kübra Tanyol¹

¹Department of Restorative Dentistry/ Firat University, Faculty of Dentistry, Turkey


ABSTRACT:

In order to prevent enamel hypoplasia and malformation in anterior teeth, direct composite veneers applications have become quite popular as minimally invasive and conservative treatment. Problems like discoloration, microleakage, low wear resistance can be encountered in direct composite resins with aesthetics and ease of application. However, prolonged use of the restoration is in question after regular checks. In this study, the dental treatment of the patient suffering from enamel hypoplasia and diastema in anterior teeth was discussed.

Key words: Aesthetic Rehabilitation, Discoloration, Enamel Hypoplasia.

Corresponding author: Dr. Hakan Kamalak, Department of Restorative Dentistry/ Firat University, Faculty of Dentistry, Turkey

This article may be cited as: Kamalak H, Tanyol K. Aesthetic Rehabilitation of the Patient with Enamel Hypoplasia and Malformation in Anterior Teeth. J Adv Med Dent Scie Res 2017;5(11):1-2.

Access this article online	
<p>Quick Response Code</p> 	Website: www.jamdsr.com
	DOI: 10.21276/jamdsr.2017.5.11.01

INTRODUCTION

Discoloration, hypoplasia, crowdings and gaps between teeth are the leading aesthetic problems in anterior region. Laminate veneers, a treatment choice to protect the tooth tissue as much as possible, is a frequently used restoration option in anterior teeth (1-3).

Veneers can be done in two ways, directly and indirectly. Direct laminate veneers can be applied directly in the clinic without the need for laboratory operation. Whereas indirect laminate are obtained through ready laminate veneers applied to the teeth and laminate veneers prepared on the model taken from the patient (4, 5).

Direct laminate veneers are more widely prepared owing to easy application in the clinic and the process to be completed in a single session. The aim of our assey is to provide aesthetic rehabilitation of the patient with enamel hypoplasia in anterior teeth and malformation in lateral teeth.

CASE REPORT

The patient was admitted to our clinic intraoral examination for being unpleasant with aesthetic appearance of the teeth and was diagnosed hypoplasia and diastema in teeth.

The 23-year-old female patient was reported that she was affected by hypoplasia in the upper central teeth, malformation in lateral teeth and diastema (Fig. 1).

The necessary information was given to the patient about treatment choices. Direct composite (VocoArabesk Composite Resin, Germany) veneers treatment which is a minimally invasive treatment method was applied to the patient after assessing the patient's expectations as well as taking economic condition into consideration. Hypoplastic areas were etched with diamonds minimally on the upper central tooth of the patient. Not any invasive procedures were applied to lateral incisors. All the enamel surfaces of the teeth were operated with 35 % of phosphoric acid gel and the bonding agent (Clearfil SE Bond Kuraray, Japan) and polymerized. Previously selected composite resin were in layers applied to the surface of the teeth. Finally, rubber finishers and polishing process were completed using disc sanders (Sof-Lex, 3M ESPE, USA).

DISCUSSION

Color, shape and position disorders on anterior teeth are the main aesthetic problems.^{6,7} Laminate veneers is the method of obtaining aesthetic and functional corrections in the most conservative way and carries the least risk of periodontal.⁸

Although the direct composite veneers are aesthetic (9), they don't provide reflectance similar to mine and light transmittance contrary to ceramic ones. In addition to this, composite veneers are susceptible to fracture opposite force.^{10,11}

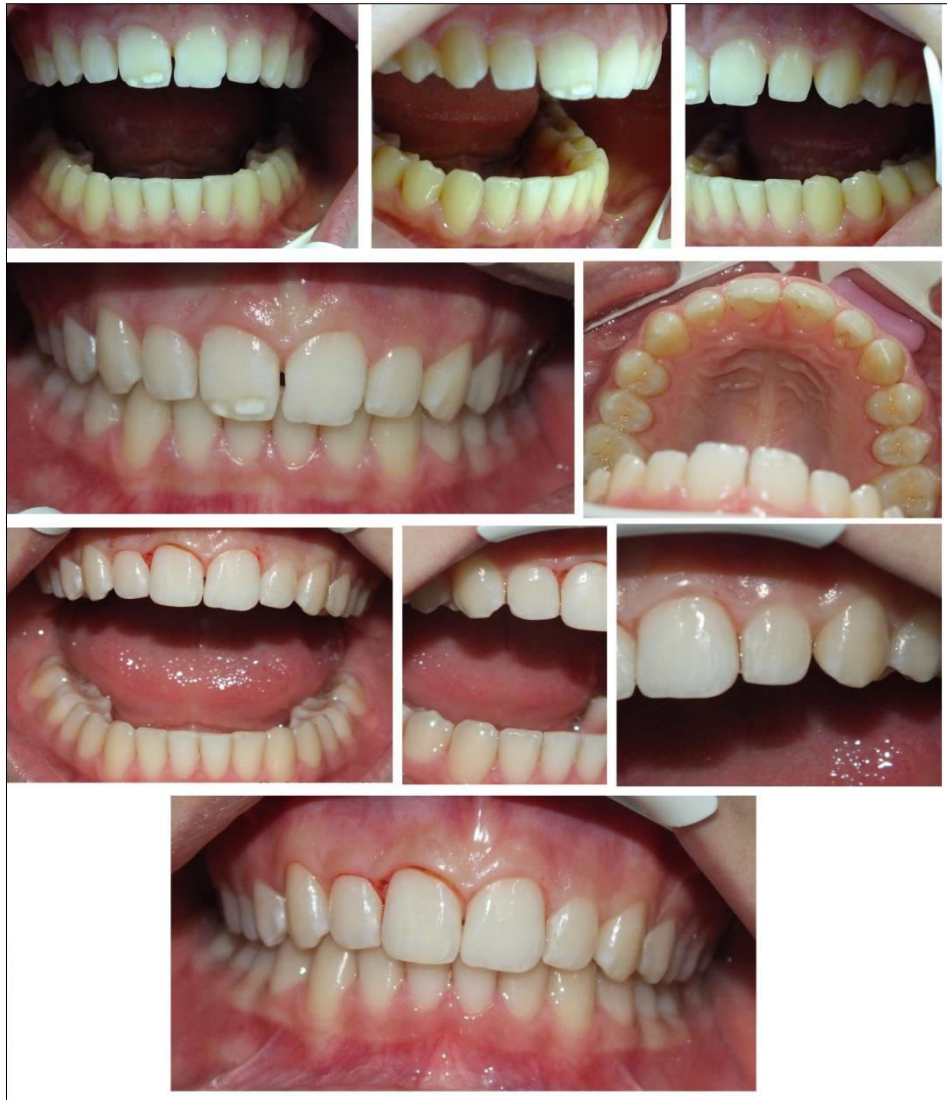

Figure 1: Pre-treatment and post-treatment images of the patient's teeth

CONCLUSION

Direct composite laminate applications made as a result of accurate indication is functionally and aesthetically adequate in enamel and restricted anterior teeth restorations. Ceramic veneers can be alternatively used in direct laminate veneer applications by financial situation and wishes of patients into consideration.

REFERENCES

- [1]. Kamalak H, Turgut H. Case Report Abrasion of Teeth (Tooth Wear), Journal of Advanced Medical and Dental Sciences Research 2(2), 2014,115-118.
- [2]. SeowWK. Enamel hypoplasia in the primary dentition: a review, ASDC J Dent Child, 58(6), 1990, 441-452.
- [3]. Nikiforuk G, FraserD. The etiology of enamel hypoplasia: a unifying concept, The Journal of pediatrics, 98(6), 1981, 888-893.
- [4]. Dumfahrt H, Schäffer H. Porcelain laminate veneers. A retrospective evaluation after 1 to 10 years of service: Part II--Clinical results, International Journal of prosthodontics, 13(1), 2000, 200-211.
- [5]. GürelG. Porcelain laminate veneers: minimal tooth preparation by design, Dent Clin North Am, 51(2), 2007, 419-431.
- [6]. Calamia J.R, CalamiaC.S. Porcelain laminate veneers: reasons for 25 years of success, Dent Clin North Am, 51(2), 2007, 399-417.
- [7]. ShainiF, Shortall A, Marquis P. Clinical performance of porcelain laminate veneers. A retrospective evaluation over a period of 6.5 years, J Oral Rehabil, 24(8), 1997, 553-559.
- [8]. Aristidis GA, DimitraB. Five-year clinical performance of porcelain laminate veneers, Quintessence Int, 33(3), 2002,
- [9]. KamalakH. Aesthetic Dentistry, International Journal of Dental and Health Sciences, 1(3), 2014, 375-379.
- [10]. Kamalak H, Umar İ. Aesthetic restoration of traumatized anterior teeth, IOSR-J Dent Med Sci, 13, 2014, 92-94.
- [11]. Kamalak H, TekinMG. Treatment of approximal caries in the anterior region, International Journal of Dental and Health Sciences, 1(3),412-422.

Source of support: Nil

Conflict of interest: None declared

This work is licensed under CC BY: *Creative Commons Attribution 3.0 License.*