

Review Article

Radicular Cyst –An Update with emphasis on Pathogenesis

Purshotam Nainani, Gagandeep Kaur Sidhu

Department of Oral Pathology and Microbiology, ¹Jodhpur Dental College Jodhpur
²Maharaja Ganga Singh Dental College and Research Center Sriganganagar (Rajasthan)

ABSTRACT:

Radicular cysts are the most common of all jaw cysts and comprise about 52% to 68% of all the cysts affecting the human jaws. Radicular cysts arise from the epithelial residues in the periodontal ligament as a result of inflammation. They generally result due to pulpal infection following dental caries. The objective of this review is to highlight the pathogenesis to understand between the two distinct categories of periapical cysts, namely, those containing cavities completely enclosed in epithelial lining, and those containing epithelium-lined cavities that are open to the root canals (bay cysts).

Key words: Radicular cyst, Non vital tooth, Inflammation.

Received: 29-07-2014

Revised: 19-08-2014

Accepted: 22-08-2014

Corresponding Author: Dr. Purshotam Nainani, Professor, Department of Oral Pathology and Microbiology, Jodhpur Dental College Jodhpur, Email: P_nainani@hotmail.com

This article may be cited as: Nainani P, Sidhu GK. Radicular Cyst –An Update with emphasis on Pathogenesis. J Adv Med Dent Scie Res 2014;2(3):97-101.

Introduction

A radicular cyst is generally defined as a cyst arising from epithelial residual (cell rests of Malassez) in the periodontal ligament as consequence of inflammation, usually following the death of dental pulp. Radicular cysts are the most common odontogenic cystic lesions of inflammatory origin affecting the jaws. They are most commonly found at the apices of the involved teeth, However they may also be found on the lateral aspect of the roots in relation to lateral accessory root canals.^{1,2} Most of the radicular cyst are symptomless and are discovered when periapical radiograph are taken of teeth with non-vital pulps. Patient often complains of slowly enlarging swellings.³ Radiographically most radicular cyst appears as round or pear shaped

unilocular radiolucent lesion in the periapical region. The cyst may displace adjacent teeth or cause mild root resorption.⁴ The Quite often a radicular cyst remains behind in the jaws after removal of the offending tooth and this is referred to as a residual cyst.² They are most commonly associated with permanent teeth and are rare in the primary teeth.⁵

Epidemiology: Radicular cysts are the most common of all jaw cysts and comprise about 52% to 68% of all the cysts affecting the human jaws.⁶ Actual prevalence of cysts is only about 15% of all apical periodontitis lesions. Their prevalence is highest among patients in their third decade of life, and higher among men than women.⁷

Pathogenesis: A radicular cyst is an odontogenic cyst of inflammatory origin

preceded by a chronic periapical granuloma and stimulation of cell rests of Malassez found in the periodontal membrane. Rests of Malassez are remnants of Hertwig's root sheath. Although the source of the epithelium is usually a rest of Malassez, other sources, such as crevicular epithelium, sinus lining, or epithelium lining of fistulous tracts, have been suggested.⁸ These cysts usually arise from the epithelial residues in the periodontal ligament as a result of inflammation. They generally result due to pulpal infection following dental caries. Bacteria from the gingival sulci or periodontal pockets have been suggested to reach the root canals of these teeth through severed periodontal blood vessels.⁹ Radicular cysts are inflammatory lesions leading to bone resorption and can reach great dimensions and become symptomatic when infected or with great size due to nerve compression.^{10,11} Pulpal infection can also occur through exposed dentinal tubules at the cervical root surface, due to gaps in the cemental coating. Microbes have also been claimed to 'seed' in the necrotic pulp via the blood circulation (anachoresis). Initially, the tooth pulp becomes infected and necrotic by an autogenous oral microflora. The endodontic environment provides a selective habitat for the establishment of a mixed, predominantly anaerobic flora. Collectively, this habitat-adapted polymicrobial community residing in the root canal has several biological and pathogenic properties, such as antigenicity, mitogenic activity, chemotaxis, enzymatic histolysis, and activation of host cells. The microbial invaders in the root canal can advance, or their products can egress, into the periapex. In response, the host mounts an array of defenses consisting of several classes of cells, intercellular messengers, antibodies, and effector molecules. The microbial factors and host defense forces encounter, clash with, and destroy much of the periapical tissue, resulting in the

formation of various categories of apical periodontitis lesions.² Periapical cysts are a direct sequel to chronic apical periodontitis, but not every chronic lesion develops into a cyst.³ There are two distinct categories of periapical cysts, namely, those containing cavities completely enclosed in epithelial lining, and those containing epithelium-lined cavities that are open to the root canals. The latter was originally described as 'bay cysts' and has been newly designated as 'periapical pocket cysts'. More than half of the cystic lesions are true apical cysts, and the remainder are apical pocket cysts.²

Pathogenesis of true cysts: The periapical true cyst may be defined as a chronic inflammatory lesion at the periapex that contains an epithelium-lined, closed pathological cavity. The pathogenesis of true cysts has been described by various authors. An apical cyst is a direct sequel to apical granuloma, although a granuloma need not always develop into a cyst. Due to still unknown reasons, only a small fraction (<10%) of the periapical lesions advance into true radicular cysts.¹² The pathogenesis of the true cyst has been described in three phases:

During the first phase, the dormant cell rests of Malassez begin to proliferate as a direct effect of inflammation probably under the influence of bacterial antigens epidermal growth factors cell mediators and metabolites that are released by various cells residing in the periapical lesion.

During the second phase, an epithelium-lined cavity comes into existence. There are two main theories regarding the formation of the cyst cavity:- Firstly, 'The nutritional deficiency theory' is based on the assumption that the central cells of the epithelial strands become removed from their source of nutrition and undergo necrosis and liquefactive degeneration, the accumulating products in turn attract neutrophilic granulocytes into the necrotic area. Such microcavities containing degenerating

epithelial cells, infiltrating mobile cells and tissue fluid coalesce to form the cyst cavity lined by stratified epithelium.²

Secondly, 'the abscess theory' postulates that the proliferating epithelium lines an abscess cavity formed by tissue necrosis and lysis because of the innate nature of the epithelial cells to cover exposed connective tissue surfaces. During the third phase the cyst grows, but the exact mechanism is still unknown. It is generally believed to be by osmosis. The presence of necrotic tissue in the cyst lumen attracts neutrophilic granulocytes, which extravasate and transmigrate through the epithelial lining into the cyst cavity where they perish. The lytic products of the dying cells in the cyst lumen release a greater number of molecules. As a result, the osmotic pressure of the cyst fluid rises to a level higher than that of the tissue fluid. The latter diffuses into the cyst cavity so as to raise the intra luminal hydrostatic pressure well above the capillary pressure. The increased intra cyst pressure may lead to bone resorption and expansion of the cyst. However, the fact that an apical pocket cyst with lumen open to the necrotic root canal can become larger suggests against osmotic pressure as a potential factor in the development of radicular cysts. Further, there is increasing evidence in support of a molecular mechanism for cyst expansion. The T-lymphocytes and macrophages in the cyst wall may provide a continuous source of bone resorptive metabolites and cytokines. The presence of effector molecules such as matrix metalloproteinase-1 and -2 have also been reported in the cyst walls.²

Pathogenesis of pocket cysts: The periapical pocket cyst contains an epithelium-lined pathological cavity that is open to the root canal of the affected tooth. As mentioned previously, such lesions were originally described as 'bay cysts'. It has been postulated that biologically, a pocket cyst constitutes an extension of the infected root

canal space into the periapex. The micro luminal space becomes enclosed in a stratified squamous epithelium that grows and forms an epithelial collar around the root tip. The epithelial collar forms an epithelial attachment to the root surface so as to seal off the infected root canal and the micro-cystic lumen from the periapical milieu and the rest of the body. The presence of microorganisms at the apical foramen attracts neutrophilic granulocytes by chemotaxis into the micro lumen. However, the pouch like lumen biologically outside the body milieu acts as a 'death trap' to the externalized neutrophils. As the necrotic tissue and microbial products accumulate, the sac-like lumen enlarges to accommodate the debris, forming a voluminous diverticulum of the root canal space into the periapical area. It has been pointed out that from the pathogenic, structural, tissue dynamic, host-benefit and protection stand points, the epithelium-lined pouch-like extension of the root canal space of such lesions has much in common with a marginal periodontal pocket.²

Site of Presentation: These cysts can occur in the periapical area of any teeth, at any age but are seldom seen associated with the primary dentition. Anatomically, the apical cysts occur in all tooth-bearing sites of the jaws but are more frequent in maxillary than mandibular teeth. In the maxilla, the anterior region appears to be more prone to cyst development whereas in the mandible the radicular cysts occur more frequently in the premolar region.⁷

Clinical Presentation: Most of the radicular cysts are symptomless and are discovered when periapical radiographs are taken of teeth with non-vital pulp. Patient often complains of slowly enlarging swellings. At first the enlargement is bony hard but as the cyst increases in size, the covering bone becomes very thin despite subperiosteal bone deposition and the swelling then exhibits

'springiness'. Only when the cyst has completely eroded the bone, there will be fluctuation. In the maxilla there may be buccal or palatal enlargement whereas in the mandible it is usually labial or buccal and only rarely lingual. Pain and infection are other clinical features of some radicular cysts. It is often said that radicular cysts are painless unless infected. Some patients with these lesions, however, complain of pain although no evidence of infection is found clinically and no evidence of acute inflammation is seen histologically after the cyst has been removed. Likewise, some patients have clinically infected and histologically inflamed cysts which are not painful. A sine qua non for the diagnosis of a radicular cyst is the related presence of a tooth with a non-vital pulp. Occasionally, a sinus may lead from the cyst cavity to the oral mucosa. Quite often, more than one radicular cyst may be found in a patient.⁷

Radiological Features: Radiographically most radicular cysts appear as round or pear-shaped unilocular radiolucent lesions in the periapical region. The cysts may displace adjacent teeth or cause mild root resorption. Radiographically, distinguishing between a granuloma and a cyst is impossible, although some say that if the lesion larger than 2 cm is more likely to be a cyst.^{13,14}

Pathological features: The gross specimens may be spherical or ovoid intact cystic masses, but often they are irregular and collapsed. The walls vary from extremely thin to a thickness of about 5 mm. The inner surface may be smooth or corrugated. Yellow mural nodules of cholesterol may project into the cavity. The fluid contents are usually brown resulting from the breakdown of blood and when cholesterol crystals are present they impart a shimmering gold or straw colour.⁷ Almost all radicular cysts are histopathologically lined wholly or in part by non-keratinized stratified squamous epithelium.

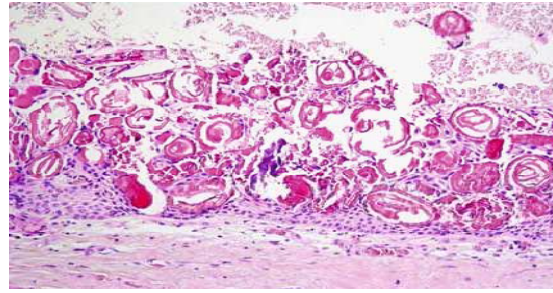


Figure 1: The photomicrograph showing a non-Keratinized stratified squamous epithelial lining of varying thickness containing Rushton Bodies.

These linings may be, discontinuous in part and range in thickness from one to 50 cell layers. The majority are between six and 20 cell layers thick. The epithelial linings may be proliferating and show arcading with an intense associated inflammatory process or be quiescent and fairly regular with a certain degree of differentiation. The inflammatory cell infiltrate in the proliferating epithelial linings consist predominantly of polymorphonuclear leucocytes whereas the adjacent fibrous capsule is infiltrated mainly by chronic inflammatory cells. In approximately 10 per cent of periapical cysts, hyaline bodies (often referred to as Rushton's hyaline bodies) are found in the epithelial linings. Such bodies within the epithelial lining are characterized by a glassy pink (hyalinized) appearance. The origin of such bodies is believed to be related to previous hemorrhage within the inflamed cyst wall.⁷

Treatment

The treatment options for radicular cyst can be conventional nonsurgical root canal therapy when lesion is localized or surgical treatment like enucleation, marsupialization or decompression when lesion is large.¹⁵ The choice of treatment may be determined by the factors such as the extension of the lesion, relation with noble structures, origin, and the clinical characteristics of the lesion, and cooperation and systemic condition of

the patient.^{16,17} The treatments of these cysts are still under discussion and many professionals option for a conservative treatment by means of endodontic technique.¹⁸ However in large lesions the endodontic treatment alone is not efficient and it should be associated to a decompression or a marsupialization or even to enucleation.^{19,20}

References

1. Narula H, Ahuja B, Yeluri R, Baliga S, Munshi AK. Conservative non-surgical management of an infected radicular cyst. *Contemp Clin Dent* 2011;2:368-71.
2. Latoo S, Shah AA, Jan SM, Qadir S, Ahmed I, Purra AR, Malik AH. Radicular Cyst. *JK Science*. 2009;11: 187-9.
3. Manwar NU, Agrawal A, Chandak MG. Management of infected radicular cyst by surgical approach. *International Journal Of Dental Clinics*. 2011;3:75-76.
4. Cawson RA, Odell EW, Porter S. Cawson's essentials of oral pathology and oral Medicine. 7thEd, Churchill Livingstone,Edn2002:102-21.
5. Lustman J, Shear M. Radicular cysts arising from deciduous teeth: Review of the literature and report of 23 cases. *Int J Oral Surg* 1985;14:153-61.
6. Nair PNR. Non-microbial etiology: periapical cysts sustain post-treatment apical Periodontitis. *Endodontic Topics* 2003;6:96-113.
7. Shear M. Cysts of the oral region, 3rd edition. Bostan wright. 1992: 136-70.
8. Amos.MJ, Dalghous.A, Alkhabuli.J. Massive maxillary radicular cyst resenting as facial fracture and abscess a case report. *Libyan J Med* 2007:211-13.
9. Grossman LI. Origin of microorganisms in traumatized, pulpless, sound teeth. *J Dent Res*. 1967; 46: 551-3.
10. Gibson G. M. et al. Case report: A large radicular cyst involving the entire maxillary sinus. *General Dentistry* 2001; 50:80-81.
11. Shafer W. G. A textbook of oral pathology. 5th ed. Philadelphia: WB Saunders 2006:376-378
12. Bhaskar SN. Periapical lesion-types, incidence and clinical features. *Oral Surg Oral Med Oral Pathol*. 1966; 21: 657-71
13. Cawson RA, Odell EW, Porter S. Cawsons essentials of oral pathology and oral medicine. 7th edition, Churchill Livingstone, Edinburgh . 2002; 15: 139-150.
14. Ragezi JA, Scubba JJ, Jordan Rck. Oral pathology: clinicalpathologic correlations. 4th edition, WB Saunders, St Louis. 2003: 241-54.
15. Ribeiro Paulo Domingos, Gonçalves Eduardo S., Neto Eduardo S. Surgical approaches of extensive periapical cyst. Considerations about surgical technique. *Salusvita Bauru* 2004; 23: 317-328.
16. Michael Mh, Gary LL. Conservative treatment of persistent periradicular lesions using aspiration and irrigation. *J Endod* 1990;16:182-6.
17. Neaverth EJ, Burg HA. Decompression of large periapicalcystic lesions. *J Endod* 1982;8:175-82.
18. Hoen.M.M. Conservative Treatment of Persistent Periradicular Lesions Using Aspiration and Irrigation. *Journal of Endodontics*1990; 16: 182-6.
19. Danin J. et al. Outcomes of periradicular surgery in cases with apical pathosis and untreated canals. *Oral Surgery and Oral Medicine and Oral Pathology and Oral Radiol. Endodontic* 1999; 87:227-32.
20. Rees. J.S. Conservative Management of a large maxillary cyst. *Int Endod Journal*1997; 30: 64-67.

Source of support: Nil

Conflict of interest: None declared