

Case Report

Customized Lubricating Eye Prosthesis - A Case Report

Mesari Koteswara Rao, K. Krishna Kishore, M. Suresh Babu, J. Ravi Rakesh Dev, H. Koteswara Rao

Department of Prosthodontics, Sibar Institute of Dental Sciences, Takkellapadu, Guntur, Andhra Pradesh, India

ABSTRACT:

Loss of an eye is an emotional and psychological problem to the human being. An ocular prosthesis was fabricated to restore the lost anatomical structure and to correct the defect of the anophthalmic sockets. The tear reflexes do not function at optimal levels in anophthalmic sockets which make prosthesis wear uncomfortable. In this case report presents an innovative hollow ocular prosthesis with functional lubricant reservoir which upon normal blinking would draw the lubricant from the reservoir through an exit hole by the blinking action creates capillary pressure which spreads over the prosthesis allowing a comfortable and long duration of prosthesis wear.

Keywords: Anophthalmic sockets, lubrication, capillary pressure, ocular prosthesis

Received: December 14, 2020

Accepted: January 17, 2021

Corresponding author: Dr. Mesari Koteswara Rao, Department of Prosthodontics, Sibar Institute of Dental Sciences, Takkellapadu, Guntur, Andhra Pradesh, India

This article may be cited as: Rao MK, Kishore KK, Babu MS, Dev JR, Rao HK. Customized Lubricating Eye Prosthesis – A Case Report. J Adv Med Dent Sci Res 2021;9(2):84-88.

INTRODUCTION:

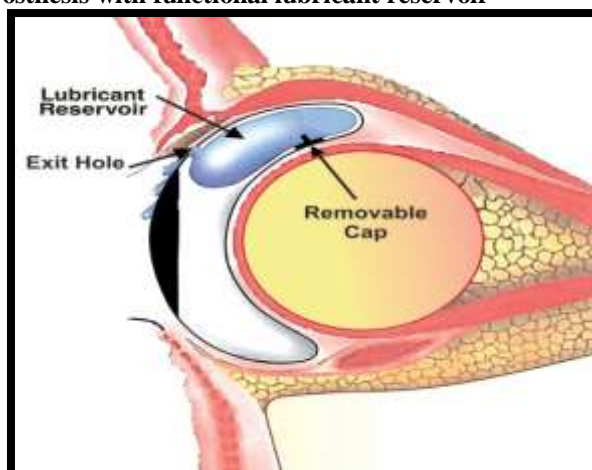
Physical defects that compromise appearance or function which prevents an individual from leading a normal life usually prompt the individual to seek treatment that will reinstate acceptable normally.

The loss of an eye impairs the patient's visual function, yet also results in noticeable deformity. A prosthesis should be provided as soon as possible to raise the spirit and ease the mind of the afflicted.

The fundamental objective in restoring the eye with a cosmetically acceptable prosthesis enables to cope better to face the outside world.

In addition to appearance, comfort is also a prime consideration to most wearers. Due to lack of lubrication in patients with anophthalmic sockets¹ blinking and tear reflexes are at optimal levels which lead to dryness, discomfort, irritation, bacterial infections².

Design of hollow ocular prosthesis with functional lubricant reservoir

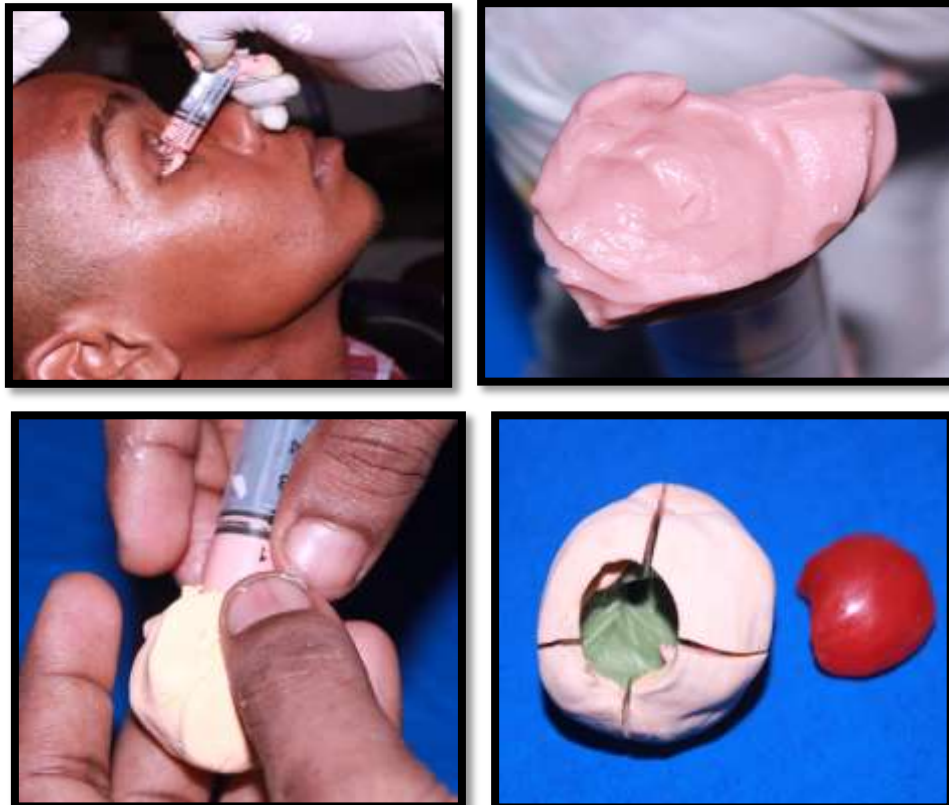


CASE REPORT

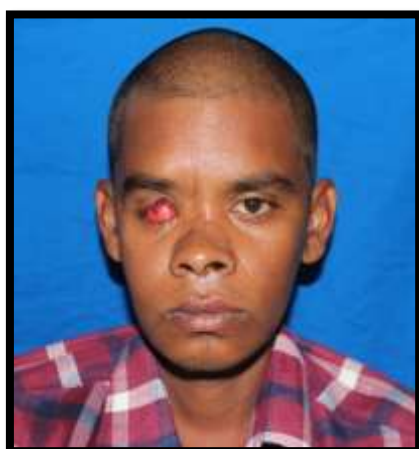A 28-year-old male patient reported to the Department of Prosthodontics for prosthetic rehabilitation of his lost right eye. On eliciting history, it was found that the patient had accident to his right eye, which necessitated a surgical evisceration of the eye. Clinical examination revealed a completely healed right eye socket. His left eye had normal vision. The patient had no other relevant medical history.

Procedure

The impression was made by injecting alginate impression material into the defected eye by using 5ml syringe. The patient was asked to move his eyes in all directions to facilitate flow of impression material into all aspects of the socket. Then, the patient was asked to look directly at a fixed point six feet away at the level of eye allowing impression of the site with the muscles in neutral gaze position.



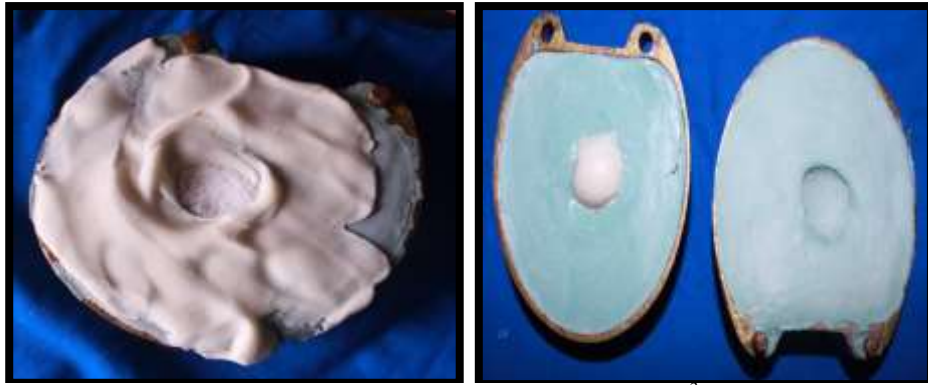- Impression is enclosed with light body, putty then it was indexed for exact location of borders and easy removal of wax pattern.



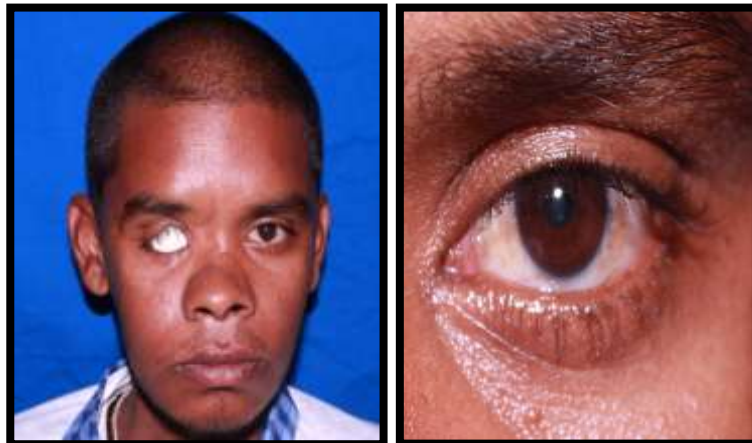Wax try in



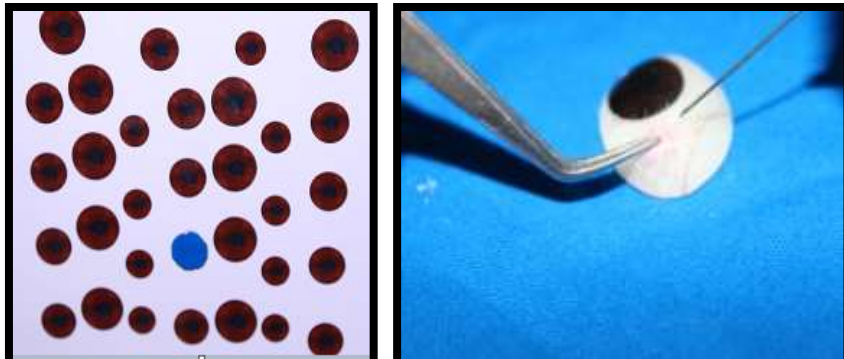
Flasking procedure



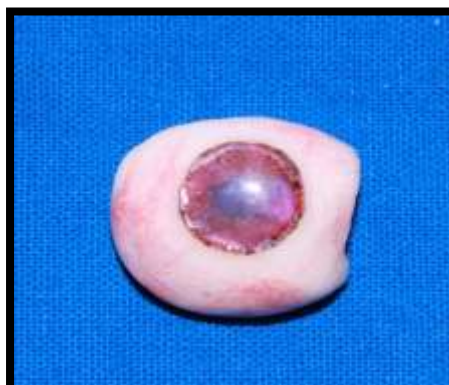Packing (done with mixture of heat cure clear acrylic resin and zinc phosphate³) is done by lost salt technique^{4,6}.



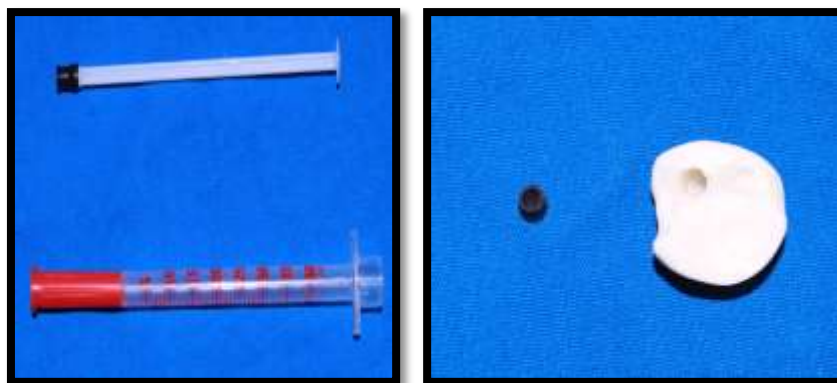
- Insertion was done and contra lateral eye life size photograph was taken for iris colour and position.



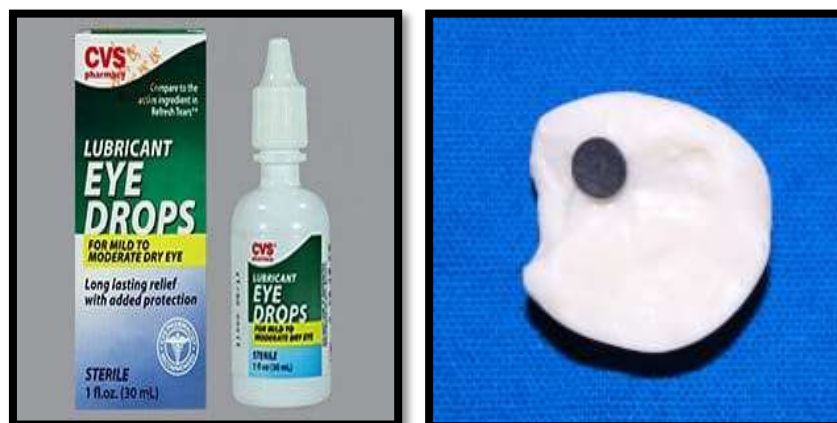Iris placement in exact position and characterization with veined acrylic was done.



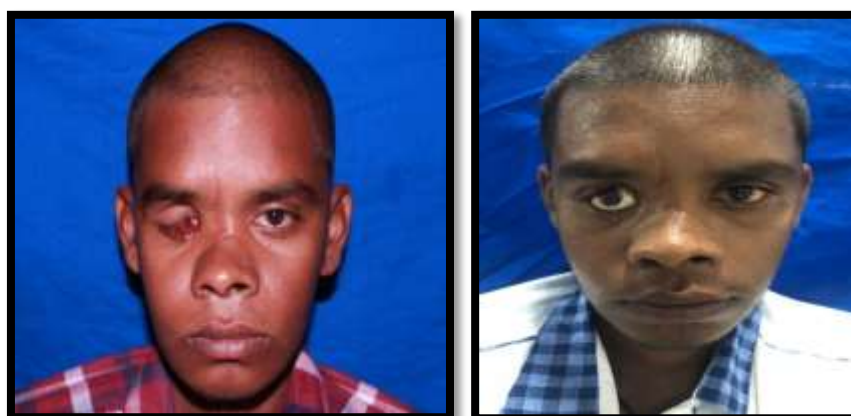Iris and veins incorporated and exit hole was prepared



Hollowing of prosthesis by removing salt and placing rubber cup in postero superior aspect of prosthesis.



Placing artificial lubricant and capping the prosthesis was done



Preoperative and postoperative pictures of the patient

DISCUSSION:

Anophthalmic sockets does not had blinking and tearing mechanisms of eye socket because they do not operate at all or are insufficient to allow the patient comfortable prosthesis use. In addition to the problem of dryness, continuing problems of bacterial infections are suffered by many prosthesis users.

This article is mainly to fabricate hollow ocular prosthesis with functional lubricant reservoir in an attempt to solve problems of inadequate lubrication such as dryness, discomfort, irritation, bacterial infections, and mucus deposition over prosthesis

thereby allowing long duration of the use of the prosthesis. The patient is instructed to load the lubricant into the reservoir via the removable cap. During the normal blinking action, the upper eyelid creates a negative pressure which draws the lubricating fluid from the reservoir to the anterior surface of the prosthesis through the exit hole which spreads over the prosthesis by blinking action. The hollow ocular prosthesis also improves comfort by reducing the weight of the prosthesis. The lubrication also gives a wet looking anterior surface which gives a life-like appearance. In cases of bacterial infections

instead of lubricant, antibacterial eye drops can be loaded in the reservoir.

Lost wax technique is used in fabrication of hollow ocular prosthesis to reduce the weight of the prosthesis. In this case report, the technique presented to fabricate the lubricant reservoir by lost salt technique is simple, easy to construct, affordable, uses readily available materials, is functional, and cleansable. However, it has certain drawbacks such as the design might not be feasible in patients with shallow sockets, difficulty in gauging resin thickness, and it depends on patient compliance for loading of lubricant reservoir.

This case report presents a simple technique to place and to match the exact position of the iris by using the life size photograph of the patients left eye to ensure that the same position of iris is achieved in the final prosthesis as it was during try-in thus avoiding squinted eye appearance. It can also be used to assess the orientation of visual axis during try-in.

A modified curing cycle called as reverse curing cycle was followed ensuring elimination of residual monomer by curing at an increased temperature. Veined acrylic is used for characterization and to match the natural eye color. Hollowing of prosthesis by removing salt and placing rubber cup in posterior superior aspect of prosthesis. Placing artificial lubricant⁴ and capping the prosthesis was done. Then exit hole was created on the anterior superior aspect of the prosthesis. During the normal blinking action, the upper eyelid creates a negative pressure which draws the lubricating fluid from the reservoir to the anterior surface of the prosthesis through the exit hole which

spreads over the prosthesis by blinking action. The patient is instructed to load the lubricant into the reservoir via the removable cap.

CONCLUSION:

Success of the ocular prosthesis largely depends on the artistic skills of the operator and maintenance and wearing of the ocular prosthesis by the patient. Through this technique, hollow ocular prosthesis with functional lubricant reservoir presented in this case report can help solve the multiple problems associated with dry eye socket, as a result provide, comfort for the longer duration of wear of the ocular prosthesis.

REFERENCES

1. Vasquez RJ, Linberg JV. The anophthalmic socket and the prosthetic eye. A clinical and bacteriologic study. *Ophthal Plast Reconstr Surg*. 1989;5:277-80.
2. Allen L, Kolder HE, Bulgarelli EM, Bulgarelli DM. Artificial eyes and tear measurements. *Ophthalmology*. 1980;87:155-7.
3. Beumer J 3rd, Curtis TA, Marunick MT. Maxillofacial Rehabilitation. Prosthodontic and Surgical Considerations. St. Louis: Ishiyaku EuroAmerica; 1996. p. 422-6.
4. Aggarwal H, Sunit KJ, Raghuwar DS, Chand P, Kumar P. Lost salt technique for severely resorbed alveolar ridges: An innovative approach. *Contemp Clin Dent* 2012;3:352-5.
5. Trawnik WR. Care of the ocular prosthesis. *Adv Ophthalmic Plast Reconstr Surg* 1990;8:146-8.
6. Kelley KV. Self-lubricating Ocular Prosthesis. US Patent 5,171,265; 1992.
7. Brito Edias R, Rezende JR, Carvalho JC. Light-weight ocular prosthesis. *Braz Dent J* 1994;5:105-8.

ACKNOWLEDGEMENTS:

I am using this opportunity to express my gratitude to everyone who supported me in completing the manuscript. First and foremost, my special word of thanks to **Dr. K. KRISHNA KISHOR, M.D.S**, Professor, H.O.D and **Dr. M. SURESH BABU, M.D.S**, professor, **Dr. J. RAVI RAKESH DEV, M.D.S**, Reader for their exemplary guidance, monitoring and constant encouragement throughout the course of this dissertation. I am indebted to them for their open-mindedness, constant support in doing the work of my choice.

I would also like to thank my teachers, friends and seniors **Dr.Vineela, Dr.Prathibha, Dr.Narayan, Dr.Priyanka, Dr.Raghunath, Dr.Manohar** for their constant guidance and my colleagues **Dr.Asritha, Dr. Sowmya, Dr.Gayathri, Dr.SivaShankar, Dr.Sirisha**, and my juniors **Dr. Krishnaveni, Dr.Koteswararao, Dr.Mounika, Dr.Pravallika, Dr.Ramya, Dr.Apoorva, Dr.Phani, Dr.Veena, Dr.Vineeth, Dr.Sravani, Dr.Kavya, Dr.Shabreen** for extending their invaluable support and timely help.