CASE REPORT

CONSERVATIVE MANAGEMENT OF TEMPOROMANDIBULAR JOINT DISLOCATION – A CASE REPORT

Ranjan Chauhan[1], Praval Pratap Singh[2], Shubhra Gupta[3], Udit Prakash[1]

[1]Department of Oral & maxillofacial surgery, [2]Department of Prosthodontics, Crown and Bridge, [3]Department of Conservative dentistry & Endodontics, Maharana Pratap College Of dentistry & Research Center, Gwalior

ABSTRACT

A dislocation of the temporomandibular joint (TMJ) represents one of the most common problem seen in temporormandibular joint. In majority of cases the etiology is non-traumatic and are often precipitated by yawning, eating, dental treatment, endoscopy, or oral intubation. Temporomandibular joint dislocation and subluxation is very distressing to the patient and sometimes even disturb the day to day life. TMJ dislocation or subluxation is an excessively abnormal condylar excursion secondary to flaccidity and laxity of the capsule. The most commonly symptom seen is open lock jaw. There are both conservative and surgical line of treatment for the management of temporomandibular joint dislocation. In the present case, a 54-year-old woman was diagnosed with a chronic TMJ dislocation that had lasted from last 6-7 months. For her conservative treatment was planned. For her we started with conservative management using bard bandage and muscle relaxant . Patient was satisfied with the result of conservative management and didn't wanted any surgical treatment.

Key words- Temporomandibular joint , Bard bandage, Conservative management.

Corresponding author: Dr Ranjan Chauhan, Assistant Professor, Department of Oral & maxillofacial surgery, Maharana Pratap College Of dentistry & Research Center, Gwalior, Email: drranjanchauhan@gmail.com

This article may be cited as: Chauhan R, Singh PP, Gupta S, Prakash U. Conservative Management Of Temporomandibular Joint Dislocation – A Case Report. J Adv Med Dent Scie Res 2015;3(3):107-109.

INTRODUCTION

A dislocation of the temporomandibular joint (TMJ) represents one of the most common problem seen in temporormandibular joint. In majority of cases the etiology is non-traumatic and are often precipitated by yawning, eating, dental treatment, endoscopy, or oral intubation[1]. Temporomandibular joint dislocation and subluxation is very distressing to the patient and sometimes even disturb the day to day life. TMJ dislocation or subluxation is an excessively abnormal condylar excursion secondary to flaccidity and laxity of the capsule. The most commonly symptom seen is open lock jaw[2]. There is both conservative and surgical line of treatment for the management of temporomandibular joint dislocation. In this paper we are presenting a case of 54-year-old woman who was diagnosed with a chronic TMJ dislocation that had lasted from last 6-7 months. For her first conservative treatment was planned. We started with placement of bard bandage and muscle relaxant. Patient was satisfied with the result of conservative management and didn't want any surgical treatment.

CASE REPORT

A 54-year-old female came to the department of oral & maxillofacial surgery with chief complain of inability to close her mouth and difficulty in eating and talking for the past 6-7 months .There is no history of any dental treatment, trauma or recent hospitalization was given. General physical examination revealed that the patient had an elongated face with bilateral fullness and at times she was not able to close her mouth. Her speech lacked clarity as she was not able to close her mouth properly. She gives history of insomnia since last 3-4 months.

On palpation, TMJ was non tender but masseter and temporalis muscles were slightly tender, no depression was found in the preauricular region with the condyle being palpated within the glenoid fossa on both the side.

Intraoral examination revealed dentulous upper and lower jaws with slightly compromised periodontal condition. Open and closed temporomandibular joint view revealed the right and left Condylar heads being positioned in the glenoid fossa only slightly high in the joint with slightly more anterior space than posterior space (Fig 1).

Following infiltration of local anaesthesia in the pterygoid region, condyles were reduced manually. After reduction the joint was immobilized with the Barton's bandage (Fig 2). The patient was advised not to open the mouth wide and not to remove the bandage for a week. Patient was placed on muscle relaxant for a week. Patient was recalled after a week for the removal of Barton's bandage and follow up. Patient was reviewed after 2 months and there was no dislocation and also patient was satisfied with the results.

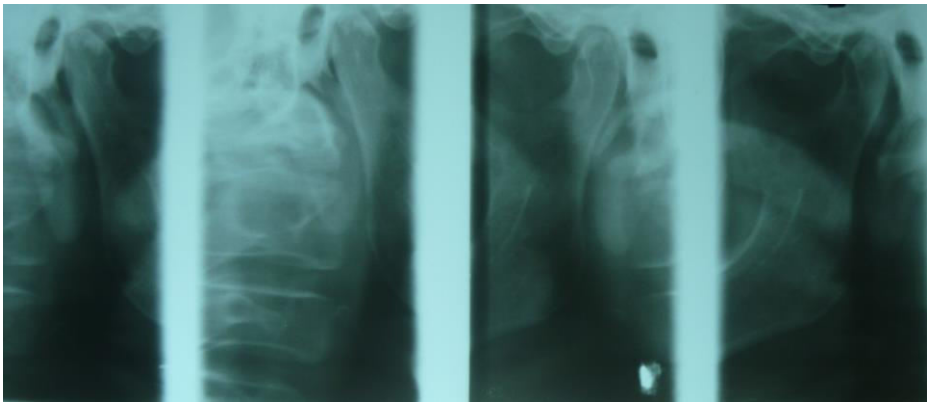

Figure 1: Radiograph showing open and closed mouth TMJ view for both right and left side

On the basis of radiographic interpretation we can say that there were no pathological changes seen in the joint space. A clinical diagnosis of bilateral chronic Condylar subluxation of TMJ secondary to muscle spasm was given. The reason of muscle spasm was not clear. Patient has given history of insomnia since last 3-4 months.

Figure 2: Showing Bard Bandage

DISCUSSION

Temporomandibular joint disorders is a vast term which embraces a number of clinical problems that involve the muscles of mastication and the temporomandibular joint (TMJ), and its associated structures.[3] TMJ problem can lead to so many symptoms like difficulty in mouth opening and closing, asymmetric jaw movements, joint noise and most common is pain.[4] The temporomandibular joint is formed by the articulation between two bony components, the condyle of the mandible and the glenoid fossa which is a concavity in the temporal bone of the skull. In front of the glenoid fossa there lies a bony projection known as articular eminence and at the back of the joint lies the external auditory meatus or the bony auditory canal. Lateral to TMJ lies the zygomatic arch and on medial side lies the styloid process. The movements of the TMJ are mainly controlled by the muscles of mastication: temporalis, masseter, lateral and medial pterygoids.[5] TMJ dislocation is a most distressing condition. Dislocation of the TMJ occurs when the condyle moves out of the glenoid fossa and becomes locked anterior or superior to the articular eminence and

this leads to patient inability in closing his /her mouth. When this occurs the surrounding muscular may begin to spasm causing discomfort to the patient and also causing hindrance in day to day normal activities.[6]

In 1832, Sir Astley Cooper proposed the principles for diagnosis and treatment of dislocation and used the term complete dislocations and imperfect dislocation for luxation and subluxation respectively[7]. TMJ dislocation represents 3% of all articular body luxation [8]. When this condition progresses and becomes frequent it is termed as recurrent dislocation or habitual dislocation. The problem can affect any age group from under the age of 10 years up to 79 years but more common in 2nd and 3rd decade [9.] Highest frequency of TMJ luxation is found in females, the cause for this is still unknown.[6]

There is both conservative and surgical line of treatment for the management of TMJ dislocation or subluxation. The results of conservative management are temporary and can condition can revert back. Surgical treatment is always better. In this case patient was not ready for any surgical intervention so we started with conservative management along with muscle relaxant. For her we manipulated the dislocated joint under local anesthesia by injecting lignocaine hydrochloride in one joint. Local anesthesia lead to relaxation of the joint and associated muscles. After reduction the joint was stabilized in reduced position by placement of bard bandage. Bard bandage is one of the oldest methods of non invasive method of joint stabilization.

CONCLUSION

Temporomandibular joint disorders are the most commonly seen disorders and are sometimes quite distressful to the patient also. There is both conservative and surgical line of management for these disorders. Conservative management should always precede the surgical management like in this case patient had good result only after conservative management and surgical management was not required. For any successful treatment correct diagnosis at correct time is very important.

REFRENCES

1. Casone P, Ungari C, Paparo F, Marianetti TM, Ramieri V, Falone M. A new surgical approach for the treatment of chronic recurrent temporomandibular joint dislocation. J Craniofac Surg. 2008;19(2):510-2.
2. Magge SN, Chen HI, Heuer GG, Carrasco LR, Storm PB. Dislocation of mandible into the middle cranial fossa -a case report. J Neurosurg. 2007;107(1):75- 8
3. Okeson J (1996) Guidelines for Assessment, Diagnosis, and Management of Orofacial Pain. Quintessence Publishing Co, Inc, Chicago.
4. Dimitroulis G (1998) Temporomandibular disorders: a clinical update. Br Med J 317(7152):190–4
5. Berkovitz B, Moxham B, Sloan A (2011) Master Dentistry. Vol 3. Oral biology. Churchill Livingstone Elsevier, Edinburgh.
6. Wong K, Cheng J (2004) Recurrent dislocation of temporomandibular joint treated by the dautrey procedure – a case report and literature review. Hong Kong Dent J 1(1): 31–4
7. Shorey CW, Campbell JH. Dislocation of thetemporomandibular joint. Oral Surg Oral MedOral Pathol Oral Radiol Endod. 2000;89(6):662-8.
8. Lovely FW, Copeland RA. Reduction eminoplasty for chronic recurrent luxation of the temporomandibular joint. J Can Dent Assoc. 1981; 47(3):179-84.
9. Tasanen A, Lamberg MA, Closed condylotomy in treatment of recurrent dislocation of mandibular condyle. Int J Oral Surgery. 1978;7(1):1-6.

Source of support: Nil
Conflict of interest: None declared