

## Original Article

### Analysis of Complications in Oral Surgical Procedures in Liver Transplant Patient- A Clinical Study

Vishal Garg<sup>1</sup>, Anmol Bagaria<sup>2</sup>, Gagandeep Kaur<sup>3</sup>, Shivam Bhardwaj<sup>4</sup>, Harikrishna Bachu<sup>5</sup>

<sup>1</sup>BDS (Maulana Azad Institute of Dental Sciences, Delhi), Fellow of forensic Odontology- SDM College of Dental Sciences & Hospital, Dharwad, Sattur, Hubli, Karnataka, India;

<sup>2</sup>BDS (Bharati Vidyapeeth Deemed to be University's Dental College & Hospital, Navi Mumbai), Private practitioner, Mumbai, Maharashtra, India;

<sup>3</sup>BDS final year, ITS Dental College, Muradnagar, Ghaziabad, Uttar Pradesh, India;

<sup>4</sup>BDS (Shree Bankey Bihari Dental College, Ghaziabad), Fellow of forensic Odontology- SDM College of Dental Sciences & Hospital, Dharwad Hwy, Sattur, Hubli, Karnataka, India;

<sup>5</sup>Intern-BDS, Geetanjali Dental and Research Institute, Udaipur, Rajasthan, India

#### ABSTRACT:

**Background:** Liver diseases are common among various age groups. The present study was conducted to assess complications in oral surgical procedures in patients with liver diseases. **Materials & Methods:** The present study was conducted on 158 patients requiring dental tooth extraction who had history of liver transplantation in last 2 years of both genders. Patients were divided into 2 groups. In group I local pressure was applied using gauze soaked with tranexamic acid at 250 mg per 5 mL and in group II (control) local pressure with gauze without tranexamic acid was used. Complications were recorded. **Results:** Hemocrit value in group I was 48.2 and in group II was 41.4. The difference was significant ( $P < 0.05$ ). Platelet level in group I was 86.5 and in group II was 64.2, INR was 1.58 in group I and 1.76 in group II and PTT ratio was 2.42 in group I and 2.31 in group II. The most common complication was excessive bleeding seen in 7 in group I and 2 in group II, delayed healing 4 in group I and 2 in group II and shock 2 in group I and 1 in group II. The difference was significant ( $P < 0.05$ ). **Conclusion:** Authors found that liver transplant patients require special care before performing any surgical procedure. Post extraction bleeding is main complication in such patients.

**Key words:** Bleeding, Complication, liver transplant

Received: 8 February, 2019

Revised: 27 March, 2019

Accepted: 28 March, 2019

**Corresponding Author:** Dr. Anmol Bagaria, BDS (Bharati Vidyapeeth Deemed to be University's Dental College & Hospital, Navi Mumbai), Private practitioner, Mumbai, Maharashtra, India

**This article may be cited as:** Garg V, Bagaria A, Kaur G, Bhardwaj S, Bachu H. Analysis of Complications in Oral Surgical Procedures in Liver Transplant Patient- A Clinical Study. J Adv Med Dent Sci Res 2019;7(4): 70-72.

#### INTRODUCTION

Liver diseases are common among various age groups. Liver transplantation become essential in chronic diseases. Infection and rejection represent the most common postoperative transplant complications. Consequently, dental examination is an integral part of the pre-transplant work-up procedure and the eradication of all oral infectious foci is essential for preventing septic episodes of an oral origin in immunosuppressed transplant patients. Frequently, the urgency of liver transplant requires fast and radical treatments such as the extraction of all

compromised elements.<sup>1</sup> Despite the discussions in the literature about the role of oral infections in post-transplant complications, dental treatment for oral foci before transplantation is a good practice for providing oral health to patients receiving immunosuppressive therapy after organ transplants. These patients are exposed to significant post-extraction complications because of malnutrition, compromised immune defense and bleeding diathesis.<sup>2</sup> These conditions, which characterize chronic liver disease, affect the physiological processes of healing of the extracted socket, thereby exposing the wound to a higher

risk of complications. Furthermore, hyposynthesis of coagulation factors and thrombocytopenia can compromise the hemostatic process.<sup>3</sup> There are several complications in patients with liver diseases. Thrombocytopenia can be observed in 15 to 70% of these patients. Its pathogenesis is multifactorial, and its major cause is splenomegaly resulting from portal hypertension that can lead to an increased sequestration of platelets in the spleen. For all of these reasons, the hemostasis scenario in these patients is extremely complex and difficult to manage.<sup>4</sup> The present study was conducted to assess complications in oral surgical procedures in patients with liver diseases.

**MATERIALS & METHODS**

The present study was conducted by involving 158 patients requiring dental tooth extraction who had history of liver transplantation in last 2 years of both genders. All were

informed regarding the study and written consent was obtained. Ethical approval was obtained prior to the study. General information such as name, age, gender etc. was recorded. Complete blood count was performed atleast 1 day before going for extraction. Blood examinations showing platelet count of 30,000/mm<sup>3</sup> were considered. Antibiotic prophylaxis such as 500 mg amoxicillin in addition to 500 mg of metronidazole 1 hour before the procedure was given.

Patients were divided into 2 groups. In group I local pressure was applied using gauze soaked with tranexamic acid at 250 mg per 5 mL and in group II (control) local pressure with gauze without tranexamic acid was used. Complications were recorded. Results thus obtained were subjected to statistical analysis. P value less than 0.05 was considered significant.

**RESULTS**

**Table I Distribution of patients**

Groups	Group I	Group II
Ingredients	Suture with tranexamic acid	Suture without tranexamic acid
Number	78	80

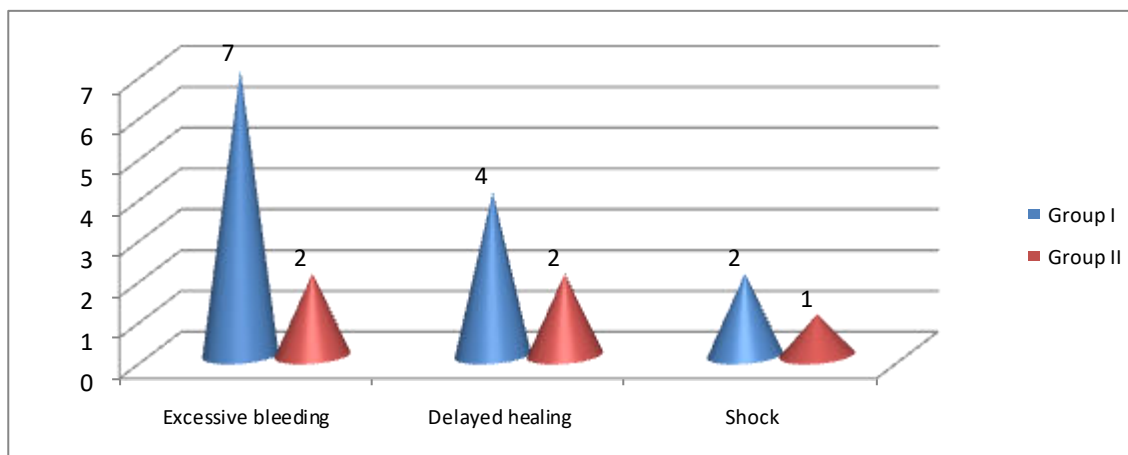
Table I shows that in group I (78) local pressure was applied using gauze soaked with tranexamic acid at 250 mg per 5 mL and in group II (80) (control) local pressure with gauze without tranexamic acid was used.

**Table II Comparison of blood indices in both groups**

Blood indices	Group I	Group II	P value
Hemocritic	48.2	41.4	0.01
Platelet level	86.5	64.2	0.5
INR	1.58	1.76	0.76
PTT ratio	2.42	2.31	0.21

Table II shows that hemocritic value in group I was 48.2 and in group II was 41.4. The difference was significant (P< 0.05). Platelet level in group I was 86.5 and in group II was 64.2, INR was 1.58 in group I and 1.76 in group II and PTT ratio was 2.42 in group I and 2.31 in group II.

**Graph I Complications in both groups**



Graph I shows that most common complication was excessive bleeding seen in 7 in group I and 2 in group II, delayed healing 4 in group I and 2 in group II and shock 2 in group I and 1 in group II. The difference was significant (P< 0.05).

## DISCUSSION

The circulation of coagulation factors in the blood is significantly reduced in association with an increasing severity of liver disease. Over 60% of patients with cirrhosis have reduced levels of factor VII, which results in increased values of prothrombin time (PT) and International Normalized Ratio (INR).<sup>5</sup> The need to assess the risk of bleeding in the presence of a high INR has been investigated in several studies on patients undergoing oral anticoagulant therapy (OAT). However, the outcome of these studies cannot be easily applied to patients with liver disorders for whom altered hemostasis can derive from chronic anemia, reduced liver production of blood clotting factors, depletion of vitamin K because of malnutrition, decreased intestinal absorption or impaired hepatic storage, increased fibrinolytic activity, or alcohol-induced bone marrow suppression.<sup>6</sup>

Studies with those types of patients do not provide reliable comparisons for understanding the risk of bleeding in liver disease patients. The difference is that in patients with liver disease, the impairment in hemostasis may be a reflection of anemia, decreased production of clotting factor because of hepatic synthetic dysfunction, depletion of vitamin K stores because of malnutrition or decreased intestinal absorption, increased fibrinolytic activity, and/or thrombocytopenia because of portal hypertension-induced splenic sequestration or alcohol-induced bone marrow suppression. In this way, the complexity of hemostasis impairment in these patients is higher than that in anticoagulated patients.<sup>7</sup>

In present study, in group I (78) local pressure was applied using gauze soaked with tranexamic acid at 250 mg per 5 mL and in group II (80) (control) local pressure with gauze without tranexamic acid was used. Hemocritic value in group I was 48.2 and in group II was 41.4. The difference was significant ( $P < 0.05$ ). Platelet level in group I was 86.5 and in group II was 64.2, INR was 1.58 in group I and 1.76 in group II and PTT ratio was 2.42 in group I and 2.31 in group II.

Hong et al<sup>8</sup> included 252 patients in study. 148 simple extractions were performed during 105 dental surgical procedures. The main preoperative blood tests such as hematocrit level, platelet counts and a mean INR were calculated. Postoperative bleeding occurred during only 1 procedure (2.8%), and local pressure with gauze was effective for achieving hemostasis. No statistically significant difference in the time to hemostasis was found between the 2 groups.

We observed that most common complication was excessive bleeding seen in 7 in group I and 2 in group II, delayed healing 4 in group I and 2 in group II and shock 2 in group I and 1 in group II. Ward et al<sup>9</sup> in a prospective study of 23 patients (including 35 dental surgical procedures), reported postoperative bleeding for one patient with INR=2.5 and PLTs=50'103/mL that occurred 3 days after extraction of a maxillary first molar. Bleeding was satisfactorily managed using local hemostatic measures, which allowed them to conclude in favor of a low risk of bleeding (4% per patient and 3% per procedure) as long as  $INR \leq 2.50$  and  $PLTs \geq 30 \times 10^3/mL$ .

## CONCLUSION

Authors found that liver transplant patients require special care before performing any surgical procedure. Post extraction bleeding is main complication in such patients.

## REFERENCES

1. Firriolo FJ: Dental management of patients with endstage liver disease. *Dent Clin North Am* 2006; 50:563.
2. Moia M, Mannucci PM, Vizzotto L, et al: Improvement in the haemostatic defect of uraemia after treatment with recombinant human erythropoietin. *Lancet* 1987;2:1227.
3. Rustemeyer J, Bremerich A: Necessity of surgical dental foci treatment prior to organ transplantation and heart valve replacement. *Clin Oral Investig* 2007;11:171.
4. Guggenheimer J, Eghtesad B, Stock DJ: Dental management of the (solid) organ transplant patient. *Oral Surg Oral Med Oral Pathol Oral Radiol Endod* 2003;95:383.
5. Tripodi A. Tests Coagulation in liver disease. *Clin Liver Dis* 2009; 13: 55
6. Nezam Afdhal et al. Thrombocytopenia associated with chronic liver disease. *Journal of Hepatology* 48 2008; 1000-1007.
7. Peck-Radosavljevic M. Thrombocytopenia in liver disease. *Can J Gastroenterol.* 2000;13: 1-7.
8. Hong CH., Scobey M.W., Napenas J., et al. Dental postoperative bleeding complications in patients with suspected and documented liver disease. *Oral Diseases* 2012; 18: 661-666.
9. Ward BB, Weideman EM. Long-term postoperative bleeding after dentoalveolar surgery in the pretransplant liver failure patient. *J Oral Maxillofac Surg* 2006; 64:1469.

Source of support: Nil

Conflict of interest: None declared

This work is licensed under CC BY: *Creative Commons Attribution 3.0 License*.