

CASE REPORT

Radicular cyst masquerading as a large Unilocular lesion in the Body region of the Mandible – Case Report

Saurabh Arya¹, Anish Poonia², Satisha T.S.³, Ankuritta Sharma⁴

¹Department of Oral and Maxillofacial Surgery, Armed Forces, India

²Department of Pedodontics and Preventive Dentistry, Armed Forces, India,

³Department of Periodontics and Implantology, Armed Forces, India,

⁴Dental Officer, Armed Forces, India

ABSTRACT:

Radicular cysts are common odontogenic cysts involving the apex of carious tooth/non-vital tooth that are slow growing and may cause bony expansion as well as involvement of the adjacent teeth and root resorption. The lesion consists of pathologic fluid-filled cavity lined by epithelium. Cyst can be managed surgically and or non-surgically. Choice of treatment depends on site and size of cyst. The present case, a characteristic large radicular cyst masquerading as a unilocular lesion, was managed with Enucleation and packing with Iodoform soaked gauze. The treatment of choice is dependent on the size and localization of the lesion, the bone integrity of the cystic wall and its close proximity to vital structures.

Key words: Enucleation, odontogenic cyst, radicular cyst, unilocular.

Received: 10 September 2018

Revised: 12 November 2018

Accepted: 13 November 2018

Corresponding Author: Dr. Saurabh Arya, Department of Oral and Maxillofacial Surgery, Armed Forces, India

This article may be cited as: Arya S, Poonia A, TS Satisha, Sharma A. Radicular cyst masquerading as a large Unilocular lesion in the Body region of the Mandible – Case Report. J Adv Med Dent Sci Res 2018;6(11):78-80.

INTRODUCTION

Radicular cyst is generally defined as a cyst arising from epithelial residues (cell rests of Malassez) in the periodontal ligament as a consequence of inflammation, usually following the death of the dental pulp.¹Radicular cysts are the most common odontogenic cystic lesions of inflammatory origin affecting the jaws. They are most commonly found at the apices of the involved teeth; however, they may also be found on the lateral aspects of the roots in relation to lateral accessory root canals.² This article presents a case of surgical management of a large radicular cyst masquerading as a unilocular lesion associated with mandibular first and second molar (46,47) in a 35 year-old male.

CASE REPORT

A 35 year old male presented with facial swelling on the right side of the face since 4 months. The swelling was approximately 7 × 3 cm in dimensions. On and clinical and Radiographic examination a large cystic lesion was seen involving the Right body region of the mandible.

Orthopantomogram and IOPA revealed radiolucent lesion associated with an incomplete RCT and broken post w.r.t mandibular right first molar. CBCT revealed the extent and size of the lesion. (Fig. 1, 2 and 3). Overall the patient was good health. A thorough intraoral examination was carried out which showed a well-defined fluctuant swelling with smooth surface, extending from Right mandibular first premolar to the right mandibular third molar. Vitality testing of the teeth revealed mandibular right second molar was non-vital. However, no mobility was seen w.r.t the mandibular molars.

Patient was taken up for Cyst Enucleation under General Anesthesia. The cyst was noted to have been attached firmly to the root of the mandibular first molar, which was subsequently extracted. Exposure of the lesion was carried out using an intra-oral crevicular incision along with a releasing incision extending from first premolar to the third molar region. (Fig. 4) Buccal corticotomy was performed using a piezoelectric saw that exposed the lesion in-toto. A careful enucleation was carried out taking care of the neurovascular bundle.(Fig 5,6) Cystic lining was sent for

histopathological examination and a confirmed as a Radicular cyst.(Fig 7) Root resorption was evident wrt Mandibular molars. An Iodoform soaked gauze was kept at the site of the cystic lesion. At six months follow-up there were no signs of recurrence of the cystic lesion.

Figure 1: Axial CT scan showing the extent of the lesion involving the Right body region of the Mandible

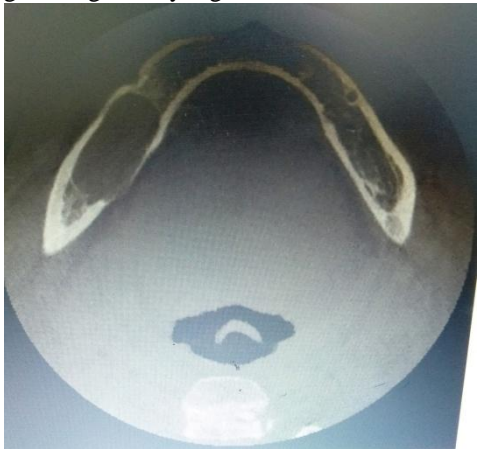

Figure 2: IOPA showing incomplete RCT

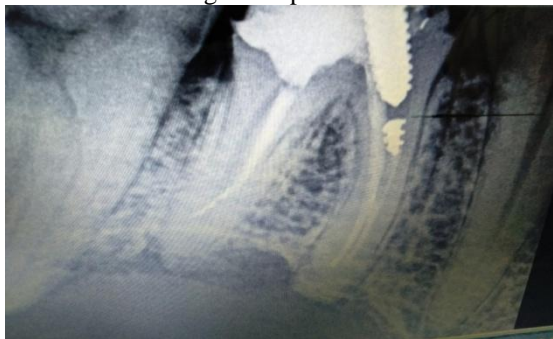

Figure 3: CBCT showing the size of the lesion

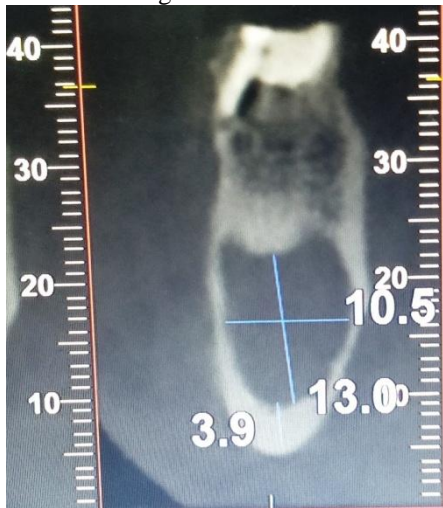

Figure 4: Intra-oral Exposure

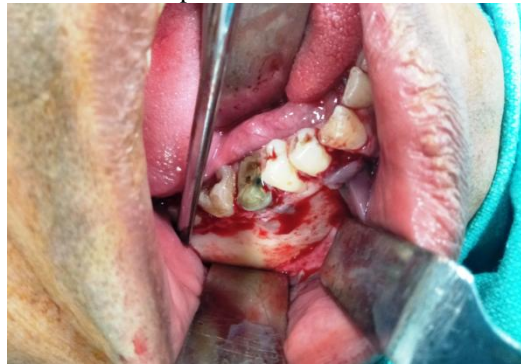

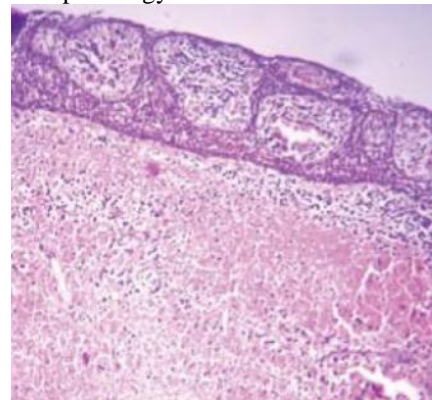
Figure 5: Exposure of the lesion

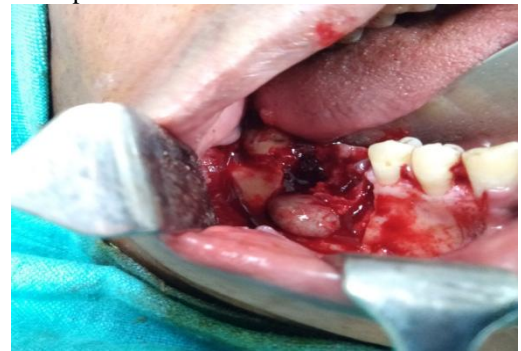

Figure 6: Enucleated lesion

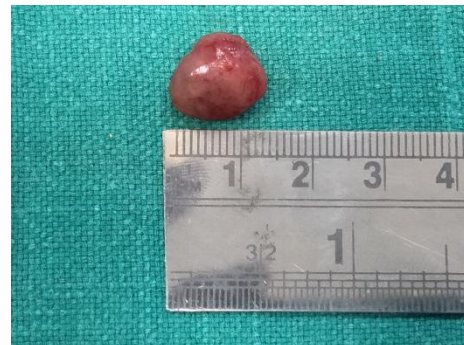

Figure 7- Histopathology of the lesion



DISCUSSION

Radicular cysts are odontogenic cysts that are derived from the inflammatory activation of epithelial cell rests of Malassez. Such lesions are inflammatory in nature and usually arise within a periapical granuloma relating to stimulation from a necrotic tooth.^{3,4} They are most commonly associated with permanent teeth and are rare in the primary teeth.⁵ Cysts constitute about 17% of all the tissue specimens submitted to oral pathology biopsy services.⁶ The choice of treatment may be determined by factors such as the extension of the lesion, relation with noble structures, origin, and clinical characteristics of the lesion, and co-operation and systemic condition of the patient.⁹ The treatment of these cysts is still under discussion and many professionals opt for a conservative treatment by means of endodontic therapy. However, in large lesions, as in this case, endodontic treatment alone is not efficient and it should be associated with decompression or marsupialization or even enucleation of the cyst.^{7,8} In the present case, a large radicular cyst was in association with a right mandibular 1st and 2nd molar, thus warranting surgical treatment rather than conservative approach.

CONCLUSION

The clinical case report of the large Radicular cyst masquerading as a unilocular lesion invading the right body region of the mandible is presented in this article that was managed successfully by Enucleation. In large cysts that extend to the lower border of the mandible, difficulties may be encountered due to the limited exposure and access for enucleation unless a generous incision is made. In specific situations where the size and extent of the lesion is of critical importance, surgical management is a viable option as compared to endodontic treatment.

REFERENCES:

1. Shear M. Cysts of the oral regions. 3rd ed. Boston: Wright; 1992. Radicular and residual cysts; pp. 136–62.
2. Bonder L. Cystic lesions of the jaws in children. *Int J Pediat Otorhinolaryngol.* 2002;62:25–9
3. Ten Cate AR. The epithelial cell rests of Malassez and the genesis of the dental cyst. *Oral Surg Oral Med Oral Pathol.* 1972;34:956–64
4. Main DM. Epithelial jaw cysts: 10 years of the WHO classification. *J Oral Pathol.* 1985;14:1–7
5. Nair PN. New perspectives on radicular cysts: Do they heal? *Int Endod J.* 1998;31:155–60
6. Lustmann J, Shear M. Radicular cysts arising from deciduous teeth: Review of the literature and report of 23 cases. *Int J Oral Surg.* 1985;14:153–61
7. Michael MH, Gary LL. Conservative treatment of persistent periradicular lesions using aspiration and irrigation. *J Endod.* 1990;16:182–6.
8. Rees JS. Conservative management of a large maxillary cyst. *Int Endod J.* 1997;30:64–7
9. Neaverth EJ, Burg HA. Decompression of large periapical cystic lesions. *J Endod.* 1982;8:175–82

Source of support: Nil

Conflict of interest: None declared

This work is licensed under CC BY: **Creative Commons Attribution 3.0 License.**