

CASE REPORT

AN EPIDERMOID CYST OF HEAD AND NECK AREA - A CASE REPORT

Chander Udey Singh¹, Ruby Bansal², Subhadeep Sarkar², Obaid Khursheed³

¹Department of Oral Medicine and Radiology, Santosh Dental College & Hospital, Ghaziabad, ²Oral and Maxillofacial Pathology, ³Pedodontics, K.D. Dental College & Hospital, Mathura

ABSTRACT:

Epidermoid cyst is the common cyst of the skin that is lined by epidermis like epithelium and rarely occurs in the head and neck region and more commonly are in the submandibular region; here we report a case of epidermoid cyst in the submandibular region, in a 50 year old male. The cyst was excised and on the basis of clinical and histopathological features the final diagnosis of epidermoid cyst was given.

Key words: Epidermoid, Sebaceous cyst, Dermoid cyst

Corresponding Author: Dr. Ruby Bansal, Department of Oral and Maxillofacial Pathology, K. D. Dental College and Hospital, Nh#2, P.O. Chatikkara, Mathura - 281006. E mail: ruby.bansal81@gmail.com

INTRODUCTION

Epidermoid and dermoid cysts of the oral cavity represent less than 0.01% of all oral cavity cysts.¹ These cysts are the benign cystic malformations that are derived from the ectoderm² and constitute 1.6 to 6.9% of all cysts in the head and neck area.³ Epidermoid cyst is the common cyst of the skin that is lined by epidermis like epithelium.² Within the oral cavity, the most common sites includes submandibular, sublingual and submental region. Rare cases have been found in oral cavity involving tongue, uvula, mandible, maxilla and palatine tonsil.⁴ These cysts are more likely to occur in young adults on the face whereas older adults are more likely to have these cysts on the back as in our case it is present in the submandibular region.

These cysts are termed “epidermoid” if they are enclosed in epithelium only, “dermoid” if they comprise skin appendages and “teratoid” if they include other tissues like muscle, cartilage or bone.⁵ It commences shortly after birth with slowly growing. That is why it draws little attention until it causes discomfort. These cysts present either as solid or cystic masses in the midline of the neck between suprasternal and submental region.⁶ Most clinicians and researchers believe that dermoid and epidermoid cysts that appear in the midline floor of the mouth are a result of entrapped ectodermal tissue of the first and second branchial arches, which fuse during the third

and fourth weeks in utero. A second theory suggests that midline dermoid and epidermoid cysts may be a variant of the thyroglossal duct cyst with ectodermal elements predominating.⁷ Nomenclature of these cysts varies in the literature. Though the term epidermoid cyst is used in a general context, in that irrespective of the source of epithelium the term persists. Name sebaceous cyst is also used in the literature to denote such cysts but now is considered as misnomer because these cysts are not of true sebaceous origin. Here we present a case of epidermoid cyst in the submandibular region of an elderly male.

CASE REPORT

A 50 year old male reported with the complaint of swelling in right lower back region of the face since 8-10 years. There was no history of any trauma, surgery or discharge from the swelling. Initially the swelling was small and gradually enlarged to the present size. On examination swelling was present extraorally on right side of the face on the body of the mandibular region measuring about 2.5x2.0x1.5cms in dimension. Swelling was oval, soft, non tender and freely mobile with well defined margins. The color of the overlying skin was normal. On palpation the swelling was soft and fluctuant in consistency. With these clinical findings, the differential diagnosis of epidermoid cyst and dermoid cyst were given. (Fig.1)

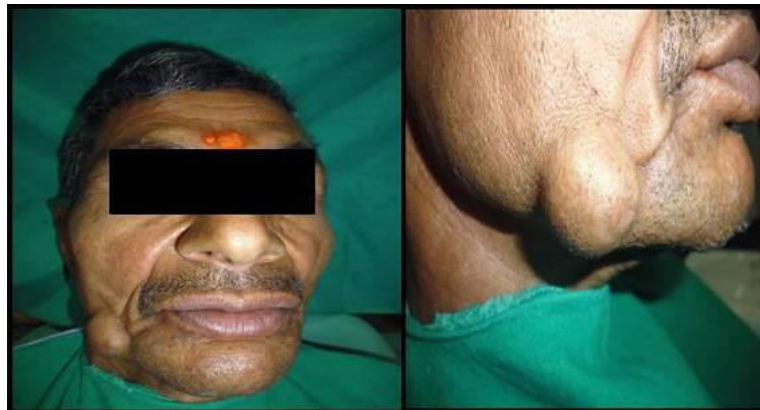

Figure 1: Clinical presentation of a dome shape swelling present on the right side on the lower border of the mandible

Excisional biopsy of the lesion was carried out. Gross specimen comprised of well circumscribed mass with smooth surface. On sectioning the white cheesy material was found. (Fig.2)

Microscopic examination revealed cystic cavity lined by orthokeratinized stratified squamous epithelium resembling epidermis with the prominent granular layer supported by connective tissue capsule having

consisting dense bundles of collagen fibers, endothelial lined blood vessels, areas of mild inflammatory cell infiltrates and adipose tissue. The lumen was filled with desquamated orthokeratin. No dermal appendages were found. Based on the clinical and histopathological features the final diagnosis of epidermoid cyst was given. (Fig.3)

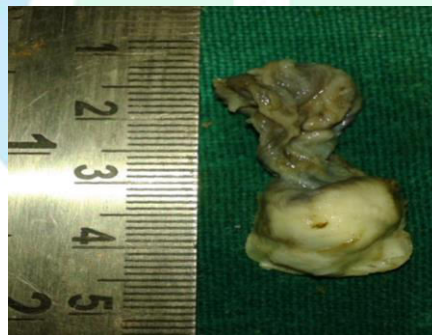

Figure 2: Specimen measuring approximately 3 x 1.5 cm in diameter delivered in total.

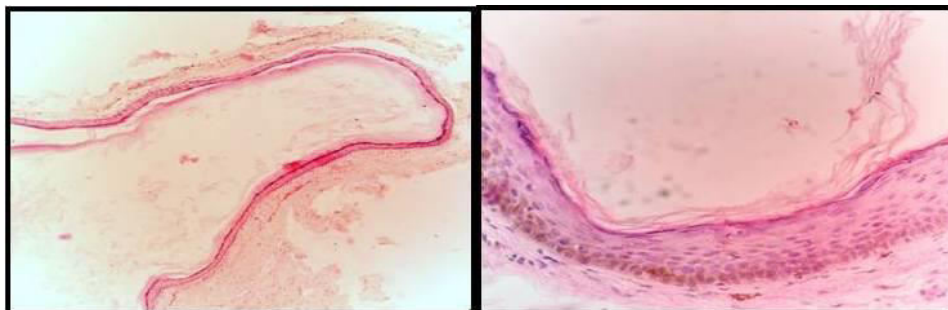


Figure 3: Low power (4x) Histopathological photomicroscopy showing cystic cavity lined by orthokeratinized stratified squamous epithelium supported by connective tissue capsule with no dermal appendages and lumen filled with desquamated keratin. High power (10x) orthokeratinized stratified squamous epithelium resembling epidermis with the prominent granular layer supported by connective tissue capsule.

DISCUSSION

Epidermoid cysts are rare lesions in the head and neck and are most often located in the submandibular region.⁸ It is a form of keratin cyst and need to be differentiated from other similar lesions such as Dermoid cysts, Teratoid cysts. These cysts are more likely to occur in young adults on the face whereas older adults are more likely to have these cysts on the back but in our case it was present on the submandibular region of an elderly male.

The origin of the epidermoid cyst is varied and believed to be formed by sequestration and implantation of epidermal rest during embryonal period, occlusion of pilosebaceous glands, iatrogenic or surgical implantation of epithelium into the mesenchyme.⁹

Epidermoid cyst is a slow growing and non tender mass. When present in dermis, it raises epidermis to produce a firm elastic dome-shaped protuberance which is mobile over the deeper structures. It may become inflamed and firm time to time. Suppuration may occur. In the oral cavity, it displaces tongue superiorly and presents with dysphagia, dyspnoea, and dysphonia. The content of a cyst sometimes escape slowly from the duct orifices and dry in successive layers on the skin, forming a sebaceous horn.¹⁰ Deeper lesions between the geniohyoid and mylohyoid muscles produce a submental swelling in the neck giving the patient a 'double-chin' appearance. The swelling may feel doughy or fluctuant. The cysts tend to be small in infancy and enlarge during adolescence.¹¹

In the our case the possibility of cyst originating as a result of entrapment is ruled out as there was no history of trauma and previous surgical treatment in that area. The term Traumatic Epidermoid cysts and Epidermoid Inclusion Cysts describe the same phenomenon, and both indicate a traumatic etiology. The epithelial implant theory is the most commonly accepted pathogenesis. It proposes that epidermal structures are driven into deeper tissues. The trapped epidermal structures assume the role of a skin graft and become independent. The tissue continues growing in its new position and produces keratin, thus forming a cyst. Seward (1965) suggested that the most likely site for their origin is anteriorly between the contributions from the mandibular arches to the tongue.¹² The problem with postulating an origin from contributions of mandibular arches to the tongue or from the first pharyngeal pouch is that it

implies endodermal derivation. This seems unlikely for a structure that contains skin adnexae.¹¹ On the other hand, Hamilton and Mossman (1972) stated that by the 32nd day of intra-uterine life, the endoderm of the floor of the mouth can no longer be distinguished from stomodeal ectoderm and there is probably a considerable amount of intermingling of the two epithelia.¹³ The boundary line is, however, behind that part of the epithelium of the mandibular process that gives origin to the teeth.¹¹

Histologically and in accordance with the classification described by Meyer in 1955, they are divided into three groups: epidermoid cysts which are covered by squamous epithelium that may be partially keratinized and dermoid cysts which also show skin appendages such as hair follicles, hair, sebaceous, and sweat glands. And finally the teratoid variant which also contains elements of the mesoderm, like bone, muscle, and respiratory or gastrointestinal tissue.²

Literatures also name such cysts as sebaceous cysts. But it is more appropriate to name them as epidermoid cysts because they have been observed not to be of sebaceous origin based on the analysis of their lipid pattern, which demonstrate similarities to the epidermis. In addition epidermoid cysts express cytokeratin 1 and 10 which are constituents of suprabasilar layers of epidermis. And now it is observed that epidermoid cysts result from proliferation of epidermal cells within a circumscribed space of the dermis.¹⁴

Treatment for these lesions is surgical excision of the cyst. It should be excised without opening because its contents could have an irritating effect on the surrounding fibro vascular tissue. Recurrence after surgery is rare. A malignant evolution has only been seen in the teratoid type and was reported to have an incidence of 0.5%.⁵

CONCLUSION

Epidermoid cyst is the rare entity to be found in the Head & Neck area, derived from developmental hamartomatous malformations, trauma or during surgery. Clinically these cysts are slow growing, non tender and enlarge when infected. The dentist should be familiar about the differential diagnosis of the tumour and cystic lesions of head and neck area, so that the proper diagnosis and treatment can be carried out.

REFERENCES:

1. P. Anantanarayanan, Darpan Bhargava, R. Manikandhan, B. Sivapathasundaram, Sub-Lingual Epidermoid Cyst, Head and Neck Pathol (2010) 4:136–138
2. Rossana Pascual Dabán, Beatriz González Navarro, Eloy García Díez, and José López-López, Epidermoid Cyst in the Floor of the Mouth of 3-Year-Old, Case Reports in Dentistry, Volume 2015, Article ID 172457.
3. Patrick J, Louis , Hudson Clint, Reddi S: Lesion of Floor of the Mouth. J Oral Maxillofac Surg 2002 , 60:804-807.
4. Jyoti Prakash Phukan, Anuradha Sinha, Subrata Pal, and Shilpa Jalan, Cytodiagnosis of Epidermoid Cyst of the Upper Lip: A Common Lesion in an Uncommon Site, J Lab Physicians. 2014 Jan-Jun; 6(1): 60–62.
5. Keles Erol, Kaplama Mehmet Erkan, Dolen Tolga, and Cobanoglu Bengu, Epidermoid cyst localized in the palatine tonsil, J Oral Maxillofac Pathol. 2013 Jan-Apr; 17(1): 148.
6. Nupur Banerjee, Abira Chattopadhyay, Ranendra N. Poddar, Subrat Kumar Padhiary, Krishna P. Das, Prasanta Bandyopadhyay, A Huge Epidermoid Cyst Endangering Life, J. Maxillofac. Oral Surg. (July-Sept 2011) 10(3):246–249
7. Jhams BC, Duraes GV, Jhams AC, Santos CR: Epidermoid cyst of the floor of the mouth: a case report. JCDA 2007 , 73:525-528.
8. Pancholi A., Raniga S., Vohra P A., Vaidya V. Midline Submental Epidermoid Cyst: A Rare Case :The Internet Journal of Otorhinolaryngology. 2006;4(2).
9. Rajendran R. Developmental disturbances of oral and paraoral structures. In: Rajendran R, Shivapathasundharam B, editors. Shafer's textbook of oral pathology. 7th edition, New Delhi, India: Elsevier; 2012. pp. 3–80.
10. Nitish Baisakhiya & Prasad Deshmukh, Unusual Sites of Epidermoid Cyst, Indian J Otolaryngol Head Neck Surg (July 2011) 63(Suppl 1):S149–S151;
11. Mervyn Shear and Paul M. Speight, Developmental cysts of the Head and Neck. In: Cysts of the Oral and Maxillofacial region, 4th edition, Blackwell Munksgaard 2012. pp.181-191
12. Seward G.R. Dermoid cysts of the floor of the mouth. British Journal of Oral Surgery, 1965; 3. 36-47.
13. Hamilton W.J. and Mossman H.W. Human Embryology, 4th ed. Cambridge: Heffer, 1972.
14. Neville BW, Damm DD, Allen CM, Bouquot JE. Developmental defects of the oral and maxillofacial region. In: Oral and Maxillofacial Pathology, 3rd ed. Pub: Saunders: an imprint of Elsevier; 2008. pp. 1-53.

This article may be cited as: Singh CU, Bansal R, Sarkar S, Khursheed O. An Epidermoid Cyst of Head and Neck Area - A Case Report. J Adv Med Dent Scie Res 2015;3(3):103-106.

Source of Support: Nil

Conflict of interest: None declared