

CASE REPORT

GARRE'S SCLEROSING OSTEOMYELITIS – A CASE REPORT

Parvind Gumber¹, Asmita Sharma², Kanchan Sharma³, Sonal Gupta¹, Bindu Bhardwaj⁴, Kamal Kant Jakhar⁵

¹Senior lecturer, Dept of Oral Pathology & Microbiology, ²Senior lecturer, Dept of Pedodontics & Preventive Dentistry, Mahatma Gandhi Dental College & Hospital, Jaipur, ³Senior lecturer, Dept of Oral Pathology & Microbiology, Rajasthan Dental College, Jaipur, ⁴Professor, Department of Oral Surgery, Mahatma Gandhi Dental College and Hospital, Jaipur, ⁵PG student, Dept of Oral Pathology & Microbiology, Maharaja Ganga Singh Dental College, Sri Ganganagar, Rajasthan, India

ABSTRACT:

Garre's sclerosing osteomyelitis is a specific type of chronic osteomyelitis that primarily affects children and adolescents. This disease is well described in dental literature and is commonly associated with an odontogenic infection resulting from dental caries. This paper describes a case of Garre's osteomyelitis in a 7-year-old-boy, in whom the condition arose following periodontal infection due to pericoronitis in relation to permanent mandibular left first molar. Clinically the patient presented with bony hard, non-tender swelling and the occlusal radiograph revealed pathognomonic feature of "onion skin" appearance. The elimination of infection was achieved by gingival curettage and the complete bone remodeling was seen radiographically after three months follow-up.

Key words: Garre's osteomyelitis, periostitis ossificans, chronic osteomyelitis, gingival curettage.

Corresponding author: Dr. Parvind Gumber, Senior lecturer, Dept of Oral Pathology & Microbiology, Mahatma Gandhi Dental College & Hospital, Jaipur, Rajasthan, India

This article may be cited as: Gumber P, Sharma A, Sharma K, Gupta S, Bhardwaj B, Jakhar KK. Garre's Sclerosing Osteomyelitis – A Case Report. J Adv Med Dent Sci Res 2016;4(2):78-83.

INTRODUCTION

Garre's Osteomyelitis is named after Carl Garre, who first observed the condition in 1893. He described a massive focal thickening of the periosteum of bones, with peripheral reactive bone as a result of irritation or attenuated infection. The condition was first observed in the tibia, and was most frequently found on the anterior surface.¹⁻⁴ Berger (1948) reported a case of perimandibular ossification with all the features of Garre's osteomyelitis, although it was Pell et al (1955) who first reported a case of Garre's osteomyelitis, involving the mandible in a 12-year-old Negro boy, caused by a deep carious lesion in the first molar.⁴ This disorder is characterized by chronic non-suppurative osteomyelitis with proliferative periostitis, which is caused by inert stimulation from low grade infection that primarily affects children and adolescents and frequently occurs in infants. Since then, many terms have been

used to describe this reactive proliferation of the periosteum. These include proliferative periostitis of Garre, Garre's osteomyelitis, periostitis ossificans, non-suppurative ossifying periostitis, osteomyelitis sicca, osteomyelitis with proliferative periostitis, and perimandibular ossification.⁵

In the maxillofacial region, the mandible is most frequently involved.⁵⁻⁷ Most reported cases are unifocal and unilateral. It has been noted that the highest incidence occurs in individuals less than 25 years of age. Eversole et al. (1979), in a report of 29 cases, found that the median age was 10.9 years (range 2.5-31 years).^{4,7} When it affects the jaw, this generally originates from an infection of low virulence, such as dental decay, mild periodontitis, periodontal defect, pericoronitis, developing tooth follicle, unerupted teeth, dental eruption or previous dental extraction in the lesion area or a consequence of infection of the underlying soft tissue that later involved the deeper periosteum, untreated fracture,

buccal bifurcation cyst, lateral inflammatory odontogenic cyst, non odontogenic infection and, rarely, no causative factor could be found.⁶⁻⁹ Clinically, this reactive process accounts for the hard swelling of the jaw and the subsequent facial asymmetry with which patients may present. The lesion is usually asymptomatic with no accompanying general and local signs of inflammation, although the clinical picture may vary widely.⁶ Garre's osteomyelitis presents a characteristic radiographic feature, showing new periosteal proliferation located in successive layers to the condensed bone formation. This is a typical radiographic feature of Garre's osteomyelitis and is well known as "onion skin" appearance.⁶ High quality radiographs reveal radiopaque bone laminations that are arranged roughly parallel to each other and to the underlying cortical surface. The periosteal reaction may be in single or multiple layers. These laminations vary from 1 to 12 in number, and radiolucent separations are often present between the new bone and the original cortex. The duplication is understood to be a result of periodic exacerbation and remission of the infection, which causes repeated perforation of the outermost new bone with restripping of the periosteum resulting in repetitive layering of bone.^{7,8} Periapical, occlusal and panoramic radiographs are often used for diagnosis of periostitis ossificans and have a high diagnostic value. However, at the initial osteomyelitis stage, there is no radiographic evidence and diffuse radiolucency begins to appear with time. Computed tomography may also be used and it is accurate for detecting not only typical alterations inside the bone, but also periosteal reactions and soft tissue involvement.^{7,8,10-12} Histologically, there is considerable new reactive bone or osteoid tissue subperiosteally, with osteoblasts surrounding many of the trabeculae, which are frequently oriented perpendicular to the cortex. The connective tissue between the trabeculae

is fibrous, and contains lymphocytes and plasma cells either in focal areas of dispersed diffusely.¹¹ Microorganisms which are isolated in most cases are *Staphylococci pyogenes*, variety *aureus* and *albus*, although various *Streptococci* and some mixed organisms can be associated.¹¹

Typical evolution of this lesion can be attributed to the fact that the high osteogenic potential in young patients allows an osteoblastic process which is superior to the osteolytic one. This pattern is identical to that of condensing osteitis, which is frequently seen in the periapical areas of carious teeth, except that the proliferation of bone is of periosteal origin rather than endosteal.¹¹

The classification of PO of the mandible by Kawai *et al.* is shown in Table 1. In this system of classification, Periostitis ossificans has been classified into two types, each with two subtypes, based on whether the original contour of mandible is preserved or not. Type I lesions are of shorter duration than type II. Both the subtypes of type I Periostitis ossificans occurs in the early stages of mandibular osteomyelitis. With adequate treatment there can be complete resolution of PO type I cases; however, if the disease continues, type I-1 may progress to type II-2 and type I-2 to type II-1, followed by type II-2. In type II cases where there has been loss of mandibular contour, deformity remains even when normal bony architecture has been restored and the disease process has been resolved. Mandibular osteomyelitis with bulbous bony enlargement in young patients is referred as gross periostitis ossificans (GPO). Kawai *et al.*'s classification of this more severe form of the disease is shown in Table 2. Type A is associated with carious tooth or followed extraction of tooth, showing onion skin appearance. In 36-8% of types B and C, no infectious source could be identified; it was suspected that it could be caused by a developing unerupted tooth or a dental follicle. Type D was seen in the chronic stage.⁸

Table 1: Classification of periostitis ossificans based on the radiographic appearance

	TYPE I <i>(original contours of mandible preserved)</i>	TYPE II <i>(original contour of mandible is lost)</i>
Subtype 1	Single lamella seen as a radiopaque line of periosteal new bone overlying the original cortex separated by a radiolucent line	Newly formed bony enlargement with resorption of original cortex and osteolytic areas usually visible.
Subtype 2	Visible hemi-elliptical newly formed bony enlargement, well outlined with a thin cortical surface located on the outer aspect of original cortex producing an onion skin appearance.	Deformation with a homogeneously dense osteosclerotic bone that made original cortex discernible. This subtype occasionally showed duplication of newly formed periosteal bone on the

outer aspect of the deformed mandible.

Table 2: Classification of gross periostitis ossificans-GPO

TYPE A	Showing an onion skin appearance, resulting from a non-vital tooth or following extraction of a tooth
TYPE B	Consolidation form shows fine bony spicules perpendicular to bone surface
TYPE C	Consolidation form shows coarse trabeculation with wide marrow spaces
TYPE D	Shows more osteosclerotic and osteolytic changes in the affected medullary bone and disappearance of original cortex or loss of the original bone contour

Other diseases which present with similar features to Garre's osteomyelitis are infantile cortical hyperostosis (Caffey's disease), hypervitaminosis A, syphilis, leukaemia, Ewing's sarcoma and metastatic neuroblastoma.^{4,6,11}

This paper describes a case of 7-year-old child, in whom the condition arose following a periodontal infection in first permanent molar. The lesion remained unresolved for a period of over 5 months as a result of misdiagnosis. The purpose of this report is to present a case of Garre's osteomyelitis of an unusual origin, because it resulted from a localized periodontal infection in a newly erupted first permanent molar. Identification of the true cause and treatment through periodontal surgery resulted in lesion resolution and resolved the diagnostic problem.

CASE REPORT

A 7-year-old female was referred to the department of pediatric dentistry for evaluation and treatment of a hard mass involving the left side of the mandible. According to the parents, approximately 5 months

earlier an asymptomatic swelling had appeared in the left side of the lower face, which within a period of a few days enlarged and caused difficulty in opening of the mouth. The patient was taken to a general practitioner who registered a sound erupting first permanent molar with no signs of periapical pathology. Oral amoxicillin was prescribed for 5 days and the swelling subsided until 3 months later when it reappeared. A second 5-day course of antibiotics was given and the patient referred to a pediatric dentist for the evaluation. Swelling subsided after the second course of antibiotics and the patient visited the pediatric dentist after a month. An occlusal radiograph taken at that time showed a buccal enlargement of the bone at the lateral side of the body of the mandible in the area of the second primary and first permanent molars (Fig.1). A tentative diagnosis of Garre's osteomyelitis was made and a third course of antibiotic therapy was prescribed for 5 days. The patient was well developed, well-nourished child in no acute distress and with an uneventful past medical history.

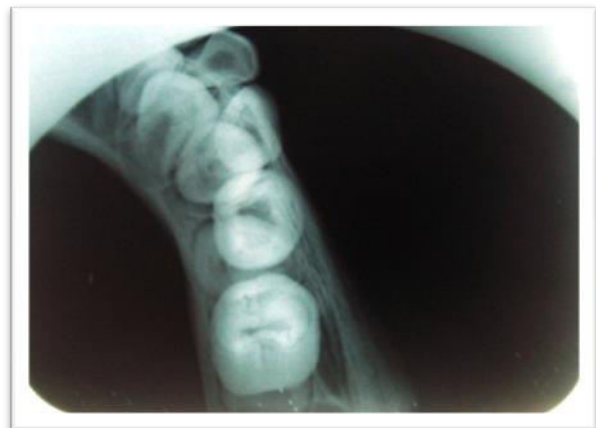
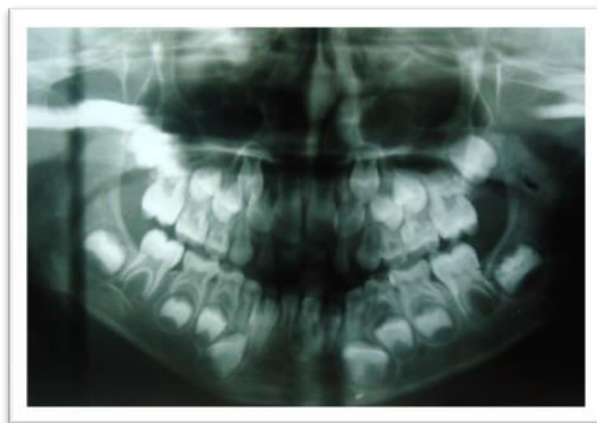
Figure 1: shows preoperative radiographs of the patient

Extraorally, there was a swelling overlying the left mandibular angle 2.0x1.0 cm in size not causing obvious facial asymmetry. The swelling was hard, firm, non-fluctuant and not tender on palpation. The overlying skin was normal. No cervical lymphadenopathy was present.

The intraoral examination revealed a bony hard swelling extending from the left first primary molar to the angle of the left mandible. The swelling was smooth and had eliminated the mucobuccal fold in the area of the first permanent molar. The overlying mucosa was in normal color and texture. The patient was in the mixed dentition with no signs and symptoms of carious lesions and periapical pathology associated with any tooth.

The radiographic pictures were in accordance with the clinical impression in providing no evidence of periapical pathology. In occlusal radiograph of mandible, a dull grey convex shadow was separated from the inferior border of the mandible by a thin, linear radiolucency (Fig.1). A prominent buccal cortex expansion extending from the involved area showed absence of clear cut opacity suggestive of osteolytic changes within the area of expansion. Radiographically, periosteal bone deposition alternating with areas of osteolysis was seen, hence suggestive of Periostitis Ossificans. The clinical and radiographic findings were considered to be indicative of Garre's osteomyelitis. Odontogenic infection consequent to caries was excluded as an

etiologic factor. Despite the absence of signs of acute inflammation in the periodontal tissues, examination with a periodontal probe showed an 8 mm periodontal pocket distal to the mandibular first permanent molar. The patient was subjected to the basic hematological investigations.

A full thickness buccal flap was elevated and gingival curettage performed with respect to 36. At surgery the buccal bone plate appeared intact. Pieces of bony tissue were shaved using a chisel. A bony biopsy was performed and the sample was submitted for histopathological evaluation. All the granulation tissue was removed and the flap was repositioned and sutured followed by application of periodontal pack. One week following curettage the patient was called for follow-up. Histopathology of the biopsied tissue revealed reactive bone formation together with findings of chronic inflammation (Fig 2). Trabeculae of bone and osteoid tissue are visible in a pool of fibrous connective tissue stroma with the osteoblasts bordering many trabeculae. Fibrous stroma displays irregular bundles of collagen fibers with abundant fibroblasts, fibrocytes and diffuse sprinkling of chronic inflammatory infiltrate predominantly lymphocytes and plasma cells. Numerous endothelial cell lined blood capillaries are discernible along with extravasated Rbcs. Deeper section also shows L.S and T.S of muscle fibers. These findings were consistent with a diagnosis of Garre's osteomyelitis.

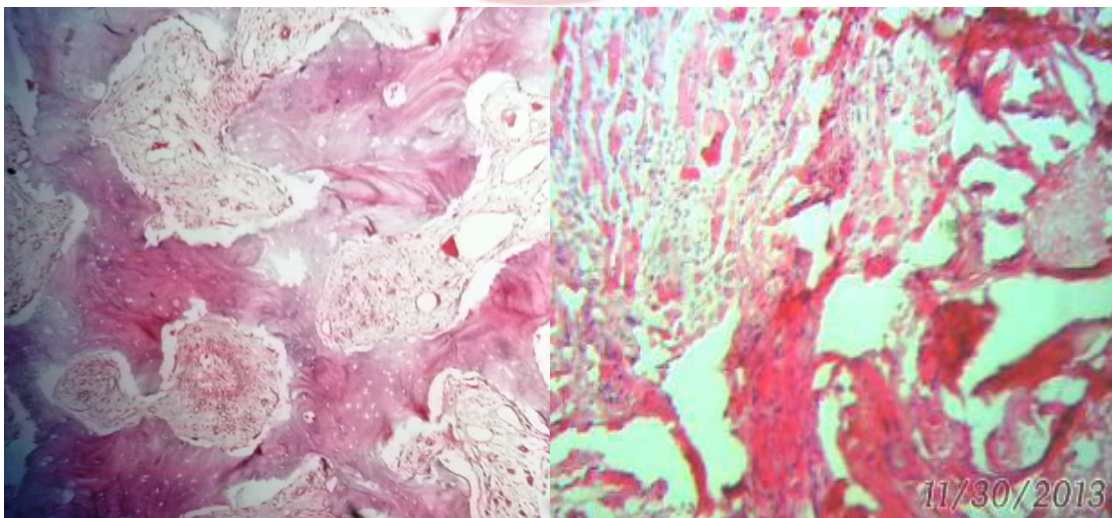


Figure 2: shows photomicrographs of histopathological tissue.

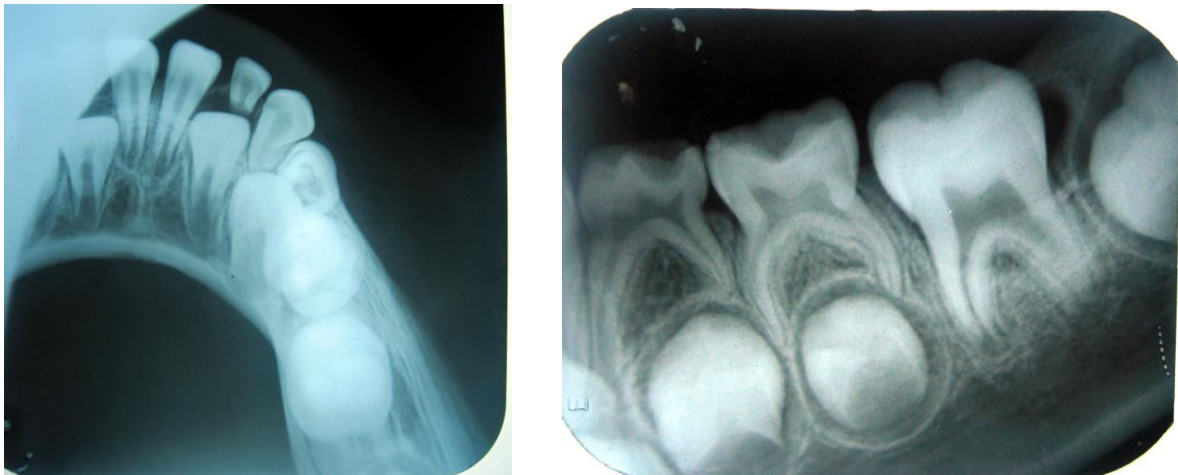


Figure 3: The post-operative radiographs of the patient

DISCUSSION

Garre's osteomyelitis is a well-documented pathologic entity in the dental literature. Because the majority of the reported cases are sequel to an odontogenic infection due to caries, the disease is most often associated with a deep carious lesion and periapical pathology.¹³

The periodontium has been reported by a number of authors as a potential source of infection for Garre's osteomyelitis where the inflammatory process may initiate and progress to a bony lesion. Loveman¹² reported a number of cases of mandibular subperiosteal swelling in children where no periapical pathology was found. The only feature in common with the case reported here was the presence of an erupting permanent molar. Gorman¹² presented a case of periostitis ossificans in the mandible where the tooth responsible was an erupting second molar covered partially by a gingival flap. The site of entry of infection was thought to be pericoronar. There have been other cases in the dental literature where the pathological process could not be explained by the factors more commonly involved with Garre's osteomyelitis. In only one of these reports was there any mention of the periodontium as a potential site of infection.¹²

In our case, the absence of evidence of periapical infection and the presence of a newly erupted first permanent molar accounts for the presence of pericoronitis and favor the development of bacterial infection. The history of the disease along with the diagnostic features justified a surgical exploration of the lesion. This verified the suspected etiologic involvement of the periodontium. Surgical removal

of the pathologic material produced resolution of the lesion, although antibiotic therapy alone had proved inadequate to eliminate the infection. Extraction of the tooth was not considered as a treatment of choice once the causative factor had been identified. Garre's osteomyelitis most often exhibits typical clinical and radiographic characteristics that help the clinician to reach a differential diagnosis. However, this case suggests that where no obvious cases can be found, one should be aware that the disease may originate from the periodontal tissues, although this is less common. Particularly in patients that present with a bony lesion indicative of Garre's osteomyelitis in the area of newly erupted first permanent molar, and where a necrotic pulp has been excluded as etiologic factor, the possibility of periodontal involvement should be explored. In such a case, a more conservative periodontal surgical approach has definite advantages over tooth extraction and should be sufficient to treat the disease.¹²

A review of the literature has shown that this supposedly rare form of bone infection is becoming more and more common.¹¹ Two reasons could account for this growing incidence:

1. As a result of the increase of health and living standards, people are responding in an "anabolic rather than catabolic manner."
2. The increased use of antibiotics has affected the virulence of microorganisms, turning an osteolytic process into osteoblastic one. However, the abuse of antibiotics could be harmful to the patient. In many cases, the evolution into le Garre's osteomyelitis could be prevented if the dentist had

thought about eliminating the causal factor rather than just instituting some antibiotic therapy. We all agree that, in the presence of an infected tooth, the microorganisms are responsible for the irritation causing the host's proliferative response. However, Thoma recalls that cultures from the bone of the tibia or femur are always sterile. Smith and Farman offer a diagram showing a sinus formation with pus from the periapical area tracking toward the surface of the bone. Rowe and Heslop¹¹ took a culture of such a sinus which proved to be sterile as well. It seems that the culprit of the tissue irritation is not the bacteria per se, but the product of their presence and degradation. The different toxins and endotoxins, spread to surrounding tissues can account for the maintenance of the chronic inflammation sites seen in microscopic examinations. The young host cannot entirely dispose of those byproducts, but can stimulate new bone formation in an attempt to encapsulate the lesion.¹¹ A fine balance is maintained between the resistance of the host and the number and virulence of present organisms, such that infection can continue at a low, chronic stage, invasive enough to stimulate new periosteal bone formation but not severe enough to induce bone resorption.^{14,15}

CONCLUSION

In conclusion, an abnormality of development of teeth can allow the entry of bacteria and result in periapical lesions. In this case, this persistent low-grade infection caused a response of the periosteal tissue known as proliferative periostitis. The proliferative periostitis is unusual because its development depends on the occurrence of a set of critically integrated conditions: that is a chronic infection in a young individual with a periosteum capable of vigorous osteoblastic activity and a equilibrium between the virulence of the infectious agents and the host resistance.

REFERENCES

1. Neville BW, Damm DD, Allen CM, Bouquot JE. Pulp and periapical diseases. In: Neville BW, editor. Oral and maxillofacial pathology. 2nd edn. Rio de Janeiro: W.B. Saunders; 2004. p.128-9.
2. Shafer WG, Hine MK and Levy BM. (1983) A Textbook of Oral Pathology. 4thedn. Saunders. Philadelphia.
3. Neelima M. Osteomyelitis and osteoradionecrosis of the jaw bones. Textbook Oral Maxillofac Surg 608-11.
4. BA Ferreira & AL Barbosa. Garre's osteomyelitis: a case report. International Endodontic Journal. 1992; 25: 165-68.
5. Nakano H, Miki T, Aota K, Sumi T, Matsumoto K, Yura Y. Garré's osteomyelitis of the mandible caused by an infected wisdom tooth. Oral Science International. 2008; 5: 150-4.
6. Suma R, Vinay C, Shashikanth MC, Subba Reddy VV. Garre's sclerosing osteomyelitis. J Indian Soc Pedod Prevent Dent. Supplement 2007; S30-33.
7. Luciana O, Thais O, Daniela M, Alynne M, Ieda R, Paulo C. Computed tomography findings of periostitis ossificans. Braz J Oral Sci. 2010; 9(1): 59-62.
8. Kannan SK, Sandhya G, Selvarani R. Periostitis ossificans (Garré's osteomyelitis): radiographic study of two cases. Int J Paediatr Dent. 2006; 16: 59-64.
9. Rafel S, Andre FL, Paulo F, Andre C, Debora FC, Eliete G and Nilce M. Proliferative periostitis with Dens In Dente: case report. Brasilia Med. 2009; 46(3):295-99.
10. Ebihara A, Yoshioka T, Suda H. Garré's osteomyelitis managed by root canal treatment of a mandibular second molar: incorporation of computed tomography with 3D reconstruction in the diagnosis and monitoring of the disease. Int Endod J. 2005; 38: 255-61.
11. Stephane S, Huan Pham. Garre's osteomyelitis: a case report. Pediatric Dentistry. 1981; 3(3): 283-86.
12. Oulis C, Berdousis E, Vadiakas G, Goumenos G. Garre's osteomyelitis of an unusual origin in a 8-year-old child: A case report. Int J Paediatr Dent. 2000; 10: 240-4.
13. Ozdemir A, Guven G, Dilsia A, Sencimen M. Diagnosis and treatment of mandibular extraoral sinus of periodontal origin in a 9-year-old boy: A case report. J Indian Soc Pedod Prevent Dent. Supplement 2008; S76-78.
14. Malini NS. Osteomyelitis with Proliferative Periostitis: Conservative management of a case. Journal of Indian Dental Association. 2010; 4(9): 327-29.
15. Eswar N. Garre's osteomyelitis: a case report. J Indian Soc Pedod Prevent Dent. 2001; 19: 157-9.

Source of support: Nil

Conflict of interest: None declared

This work is licensed under CC BY: *Creative Commons Attribution 3.0 License*.