

CASE REPORT

SUB-EPITHELIAL EXTERNAL ROOT RESORPTION OF TRAUMATIC ORIGIN ASSOCIATED WITH COMBINED ENDODONTIC PERIODONTIC LESION

Vipin Kumar¹, Vinisha Pandey², G. Rohini³, Neha Awasthi⁴

¹Consultant Periodontist and Implantologist, New Delhi, ²Reader, Department of Conservative dentistry and Endodontics, Institute of Dental studies and Technologies, Modinagar, Uttar Pradesh, India, ³Senior lecturer, Department of Periodontics, CSI college of dental sciences and research, Madurai, ⁴Senior lecturer, Department of Pedodontics and Preventive Dentistry, School of Dental Sciences, Sharda University, Greater Noida, Uttar Pradesh, India

ABSTRACT:

This case describes a successful management of external resorption combined with endodontic periodontic lesion. The combined use of periodontal surgery, mineral trioxide aggregate (MTA) and EMDOGAIN is a good approach to repair lesions with periodontal communication. It also describes the importance of diagnosis of such type of lesions and a need for a better classification of such conditions.

Key words: MTA, Emdogain, Endo-Perio lesions, communicating lesions, external root resorption.

Corresponding Author: Dr. Vinisha Pandey, Reader, Department of Conservative dentistry and Endodontics, Institute of Dental studies and Technologies, Modinagar, Uttar Pradesh, India

This article may be cited as: Kumar V, Pandey V, Rohini G, Awasthi N. Sub-epithelial external root resorption of traumatic origin associated with combined endodontic periodontic lesion. J Adv Med Dent Scie Res 2016;4(6):68-70.

Access this article online	
Quick Response Code 	Website: www.jamdsr.com
	DOI: 10.21276/jamdsr.2016.4.6.15

CASE REPORT

A 46 year old male patient reported to the department of Conservative dentistry and Endodontics with the chief complaint of pus discharge from maxillary right central incisor.

History of trauma 6 years back was positive on examination. On clinical examination cervical aspect of the central incisor appeared discoloured (Figure 1). The tooth was slightly mobile and tender to percussion with abundant exudate. Periodontal examination revealed 9 mm deep pocket on the distal and vestibular aspect of the root. Clinical attachment loss was around 13mm.

Radiographic examination revealed radio transparent lacuna on the middle third of the root (Figure 2). A mesio angular deep intra-bony periodontal defect was also seen. Based on the clinical findings a diagnosis of sub-epithelial external root resorption was made.

The patient was informed about the condition and the treatment procedures to be performed.

Access opening was done using Endo access bur (Dentsply Tulsa, UK) to allow access into the pulp chamber and preparation of the chamber walls, in one operation.

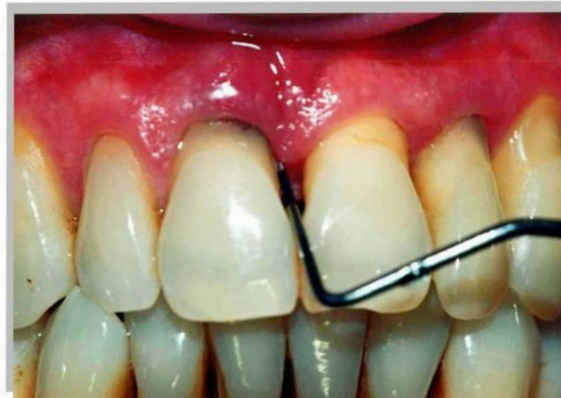

Figure 1: Pre operative picture showing discoloured of cervical aspect of the central incisor.

Working length was established using an apex locator (Root ZX mini, J. Morita, USA) which was confirmed using a radiovisiography (Kodak RVG 5100, Care stream dentals LLC, North America). Calcium hydroxide was used

To stop new resorptive tissue from growing into the root a barrier membrane was used. EMDOGAIN was used as it contains enamel matrix proteins which mediate formation of acellular cementum to cover the intra-bony defects (Figure 5). The resorptive defect was filled with MTA (Mineral Trioxide Aggregate). Suturing was done and after a week follow up was scheduled.

After a week sutures was removed, the tooth was asymptomatic and the patient was comfortable.

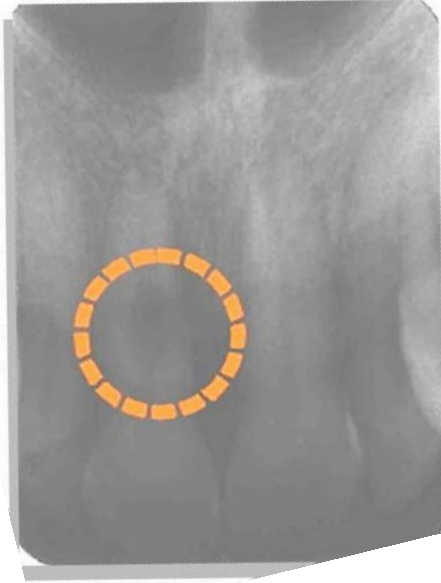

Figure 2: Radiographic examination revealed radio transparent lacuna on the middle third of the root.

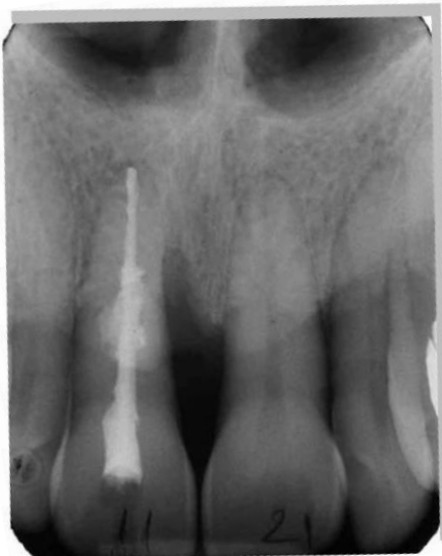

Figure 3: Endodontic treatment was performed

as an intracanal medicament for a week. Obturation was done after a week and the surgical procedure was performed (Figure 3). A full thickness mucoperiosteal flap was raised, lacunar root resorption and defect was exposed (Figure 4). A deep intra-bony mesial two wall defect with lack of vestibular cortical plate was seen. Thorough curettage of granulation tissue was done and trichloroacetic acid was used topically on the resorptive defect to control hemorrhage.

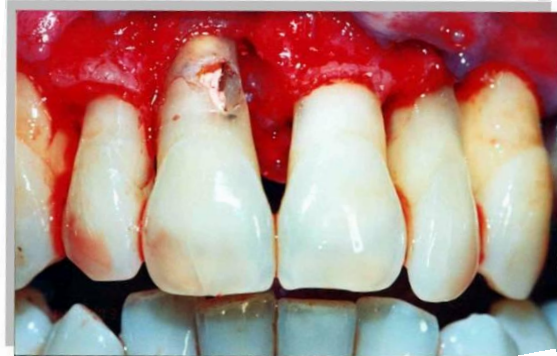

Figure 4: A full thickness mucoperiosteal flap was raised, lacunar root resorption and defect was exposed.

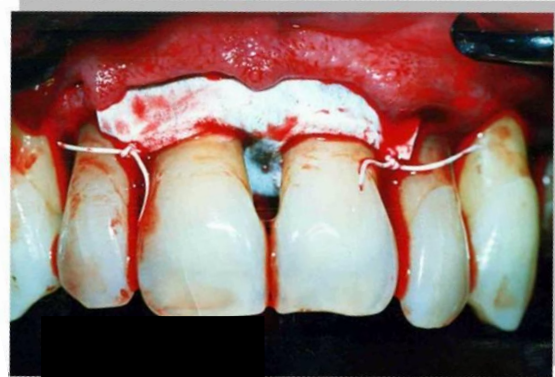


Figure 5: EMDOGAIN was used to cover the defect which mediate formation of acellular cementum.

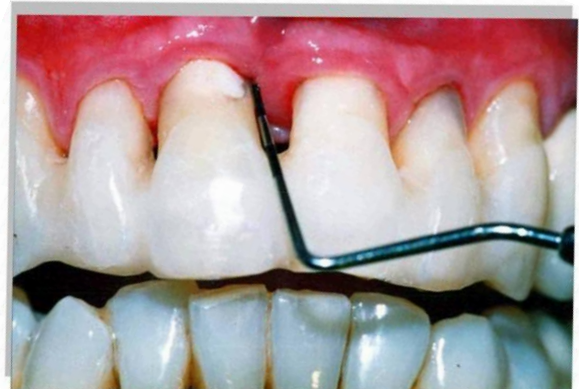


Figure 6: Follow up after 18 months

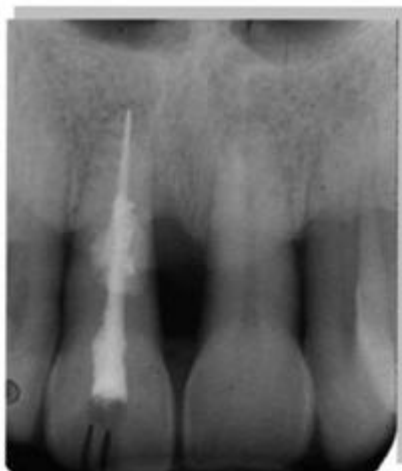

Figure 7: Radiographic examination showed that the defect was filled by about 80 %

The patient returned back after 18 months for a follow up (Figure 6). Periodontal examination revealed a reduction in pocket depth from 9 mm to 3 mm and a clinical attachment loss from 13mm to 10 mm. No exudate or discoloration was found. Radiographic examination showed that the defect was filled by about 80 % (Figure 7).

DISCUSSION

Root resorption is the physiologic or pathologic loss of dental hard tissue (dentin and cementum) due to odontoclastic action [1]. Resorptive defects present a great challenge to the clinician as well as the patient. The basic aim of treating the resorptive lesions is the complete removal of resorptive tissue and restoration of the defect.

The case was described as of cervical root resorption with a resorptive lesion seen below the epithelial attachment of the tooth but not exclusively in the cervical area of the tooth. The characteristic feature of this case was that pulp was normal to vitality testing. Localised medium sized defect was located in coronal and mid root dentin [2]. The anatomic location, pulpal and periodontal status often leads to diagnostic dilemma of such type of conditions so many attempts have been made to rename them. Looking at the associated history Martin trope in 2002 described it as sub-epithelial external root resorption of traumatic origin associated with combined endodontic periodontic lesion [2, 3].

Calcium hydroxide was used as a potent inflammatory stimulator, alkalizes pH in the surrounding dentinal tubules thus killing bacteria and neutralizing endotoxin. Trichloroacetic acid was used to control haemorrhage thus achieving a clean space for restoration of the defect [2,4]. To stop new resorptive tissue from growing into the root a barrier membrane was placed.

Certainly such types of cases have lengthy and costly procedures with an unpredictable outcome. In our case two treatment options was provided to the patient; extraction followed by an implant or efforts to save the tooth [3,4]. The patient's preference was to save the tooth irrespective of the prognosis. The endodontic literature lacks long term follow up of such type of cases treated by surgical intervention. So a long term follow up was planned with a favorable outcome.

CONCLUSION

Clinicians should understand the importance of endodontic, periodontal, and restorative aspects of treating perforating root resorption.

The endodontic treatment is incomplete if the resorptive defect is not eliminated and the restorative aspects are not managed properly. Adequate management requires knowledge and skills in endodontics, surgery, and restorative dentistry. A new classification system should be developed to include such type of lesions for their proper management.

REFERENCES

1. Alberto Sierra-Lorenzo et al. Management of Perforating Internal Root Resorption with Periodontal Surgery and Mineral Trioxide Aggregate: A Case Report with 5-Years Follow-Up. *Int J Periodontics Restorative Dent.* 2013 Mar-Apr;33 (2):e65-71.
2. Martin trope. Root Resorption due to Dental Trauma. *Endodontic Topics* 2002, 1, 79–100.
3. Ahmed Kulsoom Siddiqui, Ramya Raghu, Ashish Shetty, Chinmaya Kumar Samantaroy. Management of an endo-perio lesion due to invasive cervical resorption: Literature review and a clinical report. *Journal of Interdisciplinary Dentistry;* May-Aug 2013: Vol-3 Issue-2.
4. Heithersay GS. Management of tooth resorption. *Australian Dental Journal Supplement.* 2007;52:(1 Suppl):S105-S121.

Source of support: Nil

Conflict of interest: None declared

This work is licensed under CC BY: *Creative Commons Attribution 3.0 License.*