

ORIGINAL ARTICLE

ASSESSMENT OF EFFICACY OF OFLOXACIN AND CHLORAMPHENICOL IN PATIENTS WITH EXTERNAL OCULAR INFECTION: A COMPARATIVE STUDY

Vijay Kumar Singh¹, Swarastra Prakash Singh²

¹Associate Professor, ²Assistant Professor, Department of Ophthalmology, Career Institute of Medical Sciences and Hospital, Lucknow, U.P., India

Abstract

Background: Pathogenic micro-organisms are the most commonly involved etiologic agents in causing external ocular diseases. Conjunctiva, lid and cornea are the most commonly affected parts of the eye. Ofloxacin is exceptionally potent against a wide range of Gram-positive and Gram-negative bacteria and obligate anaerobes. It is also reported to be effective against ocular pathogens. The action of chloramphenicol is usually bacteriostatic. Hence; we planned the present study to compare the effectiveness of ofloxacin and chloramphenicol in patients with external ocular infection. **Materials & methods:** The present retrospective study included retrospective assessment of all the patients with external ocular infections who underwent treatment with ofloxacin or chloramphenicol. Assessment of symptoms was done based on ophthalmic examination as done by visual acuity and ophthalmoscopy at three follow-up times; one day time, four days times and last visit at one week time. Colony-forming units were counted, bacteria identified, and sensitivity tests to ofloxacin and chloramphenicol were performed. A culture was considered positive if the colony count exceeded the threshold for any bacterial class. Clinical improvement was defined as a decline in symptoms of external ocular infection. At the third visit, both microbial and clinical improvement was assessed from the culture positive patients. All the results were analyzed by SPSS software. **Results:** 100 percent of the patients in the ofloxacin group and in the chloramphenicol group showed improvement against Haemophilus influenza. When assessed against Strept. spp, 91 and 100 percent of the patients in the ofloxacin and chloramphenicol group showed improvement respectively. 87 and 90 percent of the subjects in the ofloxacin and chloramphenicol group showed improvement against Staph. epidermidis respectively. Among the patients of the ofloxacin group, clinical and microbial improvement was shown by 100 and 82.5 percent of the subjects respectively while in the chloramphenicol group, clinical and microbial improvement was shown by 94.5 and 84.5 percent of patients respectively. **Conclusion:** For the treatment of patients with ocular infections, the efficacy of ofloxacin in comparison with chloramphenicol has clinical equivalence.

Key words: Chloramphenicol, Ocular infection, Ofloxacin

Corresponding author: Dr. Vijay Kumar Singh, Associate Professor, Department of Ophthalmology, Career Institute of Medical Sciences and Hospital, Lucknow, U.P., India

This article may be cited as: Singh VK, Singh SP. Assessment of efficacy of ofloxacin and chloramphenicol in patients with external ocular infection: a comparative study. J Adv Med Dent Scie Res 2017;5(2):49-52.

Access this article online	
<p>Quick Response Code</p> 	<p>Website: www.jamdsr.com</p>
	<p>DOI: 10.21276/jamdsr.2017.5.2.12</p>

INTRODUCTION

Ocular diseases are caused by pathogenic micro-organisms. Conjunctiva, lid and cornea are the most commonly affected parts of the eye. Bacteria are major causative agents that frequently cause infections in eye and possible loss of vision.¹ Conjunctivitis, scleritis, keratitis, blepharitis, canaliculitis and dacryocystitis are the most commonly encountered signs and symptoms associated with patients affected with ocular pathologies.² The most common cause of red eye is conjunctivitis. In developing countries, the most frequent cause of mono-ocular blindness is corneal ulceration. Infection, allergic reactions and irritation forms the three most common cause of conjunctivitis. Infective conjunctivitis is most commonly caused by bacteria and viruses.³

Viral conjunctivitis causes a watery discharge while the discharge from bacterial conjunctivitis contains pus. After cataract, vision loss and blindness is most commonly caused by infective keratitis.⁴ Blepharitis is an inflammation of the eyelid margins which can result in patient discomfort and decline in visual function while endophthalmitis may cause vision-threatening ocular complications following intraocular surgeries and during open-globe injuries.⁵ Inflammation of the lacrimal sac and duct is referred to as Dacryocystitis. Ofloxacin is exceptionally potent against a wide range of Gram-positive and Gram-negative bacteria and obligate anaerobes. It is also reported to be effective against ocular pathogens.⁶ The action of chloramphenicol is usually bacteriostatic, but it is bactericidal against Haemophilus influenza, Streptococcus pneumoniae, and Neisseria

meningitidis.⁷ Hence; we planned the present study to compare the effectiveness of ofloxacin and chloramphenicol in patients with external ocular infection.

MATERIALS & METHODS

The present retrospective study was conducted in the department of ophthalmology of the medical institute and included retrospective assessment of all the patients with external ocular infections who underwent treatment with ofloxacin or chloramphenicol from 2014 to 2016. Ethical approval was taken from the institutional ethical committee and written consent was obtained after explaining in detail the entire research protocol.

Assessment of symptoms was done based on ophthalmic examination as done by visual acuity and ophthalmoscopy at three follow-up times; one day time, four days times and last visit at one week time. On day 1 ocular culture were obtained from all patients as described below. Investigators applied the first drug dose, and patients were instructed to use their eye drops every 2-4 waking hours (according to severity as determined by the physician) on days 1 and 2 four times daily on days 3 through 7, and to stop treatment at least 12 hours before visit 3 on day 8. Symptoms and drug tolerance were evaluated at visits 2 and 3. A second ocular culture was taken on visit 3 from patients whose first culture had given a positive result. For the ocular cultures, samples were taken from the lid margin and conjunctival cul-de-sac of each affected eye. After the culture sample was obtained, each swab was placed in a sterile tube containing 1-0 ml of transport dissolving buffer solution and were sent to the microbiological laboratory for testing. Colony-forming units were counted, bacteria identified, and sensitivity tests to ofloxacin and chloramphenicol were performed. A

culture was considered positive if the colony count exceeded the threshold for any bacterial class. Clinical improvement was defined as a decline in symptoms of external ocular infection. The composite severity score (CSS) of 10 factors (lid erythema, oedema and crusting, palpebral and bulbar conjunctival hyperaemia, conjunctival oedema and discharge, corneal oedema, foreign body sensation, and pain) was determined for all patients. At the third visit, both microbial and clinical improvement was assessed from the culture positive patients. All the results were analyzed by SPSS software. Univariate analysis and chi-square test were used for the assessment of level of significance.

RESULTS

Comparison of patients on ofloxacin therapy and chloramphenicol therapy is shown in **Table 1** and **Graph 1**. 100 percent of the patients in the ofloxacin group and in the chloramphenicol group showed improvement against Haemophilus influenza. When assessed against Strept. spp, 91 and 100 percent of the patients in the ofloxacin and chloramphenicol group showed improvement respectively. 87 and 90 percent of the subjects in the ofloxacin and chloramphenicol group showed improvement against Staph. epidermidis respectively. **Table 2** and **Graph 2** shows the clinical and microbial improvement of the patients in both the study groups after one week follow-up. Among the patients of the ofloxacin group, clinical and microbial improvement was shown by 100 and 82.5 percent of the subjects respectively while in the chloramphenicol group, clinical and microbial improvement was shown by 94.5 and 84.5 percent of patients respectively.

Table 1: Comparison of patients on ofloxacin therapy and chloramphenicol therapy

Micro-organism	Percentage of patients showing improvement	
	Ofloxacin group	Chloramphenicol group
Haemophilus influenza	100	100
Strept. spp	91	100
Staph. aureus	95	85
Staph. epidermidis	87	90

Graph 1: Comparison of patients on ofloxacin therapy and chloramphenicol therapy

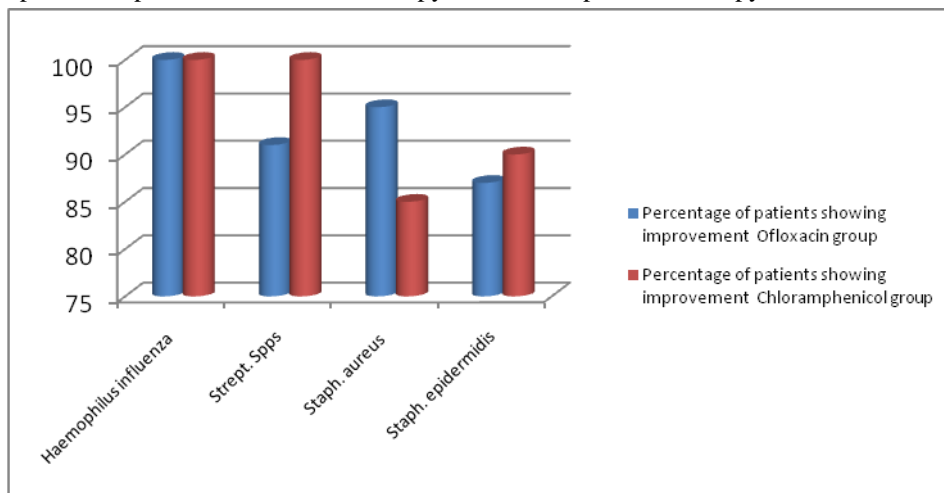
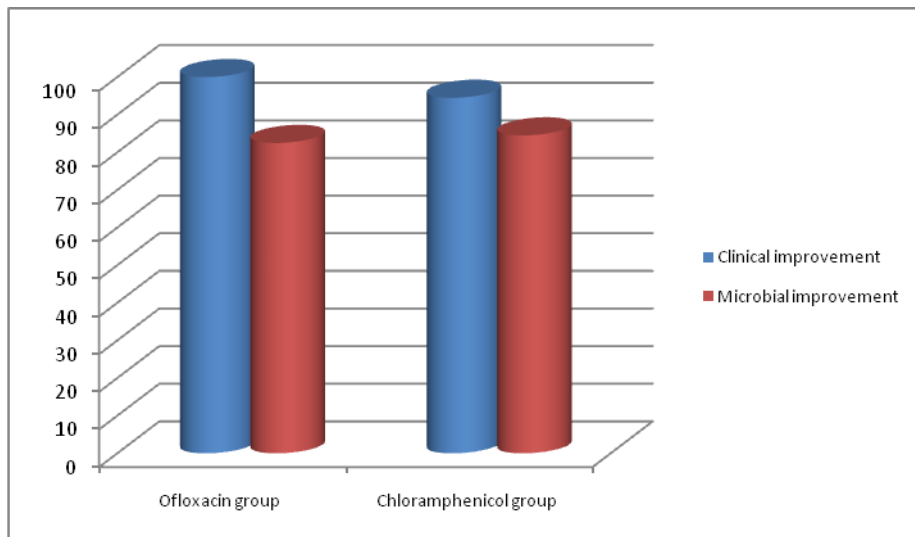


Table 2: Clinical and microbial improvement of the patients in both the study groups after one week follow-up

Percentage of Improvement	Ofloxacin group	Chloramphenicol group
Clinical improvement	100	94.5
Microbial improvement	82.5	84.5

Graph 2: Clinical and microbial improvement of the patients in both the study groups after one week follow-up



DISCUSSION

The severity of the ocular infections ranges from self-limiting in milder cases to sight threatening and blindness in severe cases. Microbial agents causing ocular infections are dependent upon a number of factors which determines their clinical outcomes the epidemiological patterns vary from one country to the other and in different geographical areas in the same country.^{6, 7} In Ethiopia the prevalence of blindness was reported about 1.6 % and it was estimated that 87.4 % of the cases were due to avoidable causes.⁸

Broad spectrum antibiotics form the main line of treatment for the cases of bacterial ocular infections. The indiscriminate use of antibiotics led to the development of resistance to many commonly used antimicrobial medications.⁹ The emergence of bacterial resistance towards topical antimicrobial agents may increases the risk of treatment failure with potentially serious consequences.¹⁰ Hence; we planned the present study to compare the effectiveness of ofloxacin and chloramphenicol in patients with external ocular infection.

In the present study, we observed that in the treatment of external ocular infections, ofloxacin is a safer antimicrobial agent (Table 1). In promoting both clinical and microbial outcomes, both ofloxacin and chloramphenicol performed approximately equally in cases of ocular infections (Table 2). Shiferaw et al determine the prevalence of bacterial isolates and their antimicrobial susceptibility pattern among patients with external ocular infections. A cross sectional study was conducted among 160 patients with external ocular infections at Borumeda hospital, Northeast Ethiopia. Socio-demographic and clinical data were collected using structured

questionnaire. External ocular specimens were collected using sterile swabs and inoculated on MacConkey agar, Chocolate agar and Blood agar culture Medias. The overall prevalence of bacterial pathogens among external ocular samples was 59.4 %. The majority of the isolates were Gram positive and the other 6.3 % (6/95) Gram negative bacteria. The prevalence of bacterial pathogens among external ocular samples was high and the predominant isolate was coagulase negative *Staphylococci*.¹¹

Mshangila et al evaluated the external ocular surface bacterial isolates and their antimicrobial susceptibility patterns among pre-operative cataract patients at Mulago National Hospital. This cross sectional study enrolled consecutively 131 patients scheduled for routine cataract surgery in the Department of Ophthalmology at Mulago National Hospital in Kampala, Uganda. Eyelid margin and conjunctival swabs were collected and processed using standard microbiological procedures to identify bacterial isolates and their respective antimicrobial susceptibility patterns. Of 131 patients involved, 54.2% were females. The eyelid margin and conjunctival samples were culture positive in 59.5% and 45.8% respectively. The most common organisms identified were Coagulase-negative Staphylococci (CoNS) and *Staphylococcus aureus*. CoNS and *S. aureus* are the most common bacterial isolates found on the external ocular surface of the pre-operative cataract patients. Ciprofloxacin, gentamicin, tobramycin and vancomycin showed the lowest resistance rates to all bacterial isolates, therefore may be used to reduce bacteria load in the conjunctiva sac among cataract patients prior to surgery.¹² Bron et al compared the safety and efficacy of 0.3% ofloxacin in treating bacterial ocular infections

with that of 0.5% chloramphenicol in a parallel-group, randomised clinical trial at five sites. Clinical and microbiological improvement rates were studied in 84 culture-positive patients. Patients with suspected bacterial ocular infections were evaluated for clinical improvement and were included in drug safety and comfort analyses. Clinical improvement did not differ significantly between drug treatments. All patients completing the study (79 assigned ofloxacin, and 74 chloramphenicol) showed clinical improvement. Clinical improvement in the culture-positive groups was 100% (41/41) after ofloxacin treatment, and 95% (41/43) after chloramphenicol treatment. Microbiological improvement rates were similar for the two drugs: 85% (33/39) improved with ofloxacin, and 88% (38/43) improved with chloramphenicol. Both drugs were well tolerated.¹³

Hemavathi et al determine the prevalence of bacterial and fungal infections of the eye and also to assess the antibiotic susceptibility pattern of bacterial isolates at an eye care hospital in Bangalore, India. Two hundred thirty five samples were received from infections of the eye-conjunctivitis including dacryocystitis, corneal ulcers, endophthalmitis and post-traumatic infections. Culture, Gram's stain and potassium hydroxide (KOH) mount was done for all clinical specimens. Giemsa staining was done occasionally as required. Antibiotic susceptibility testing was performed for bacterial growth. Out of 235 samples processed, 81(34.5%) yielded bacterial growth and 32 (13.6%) yielded fungal growth. One corneal scraping showed the presence of *Acanthamoeba* by microscopy. Predominant bacterial isolates were- *Staphylococcus* species 36 (39.9%), *Pseudomonas* species 20 (22.2%) and *Escherichia coli* 12 (13.3%). Conjunctival specimens yielded mainly bacterial growth with *Staphylococcus* species being the predominant isolate followed by *Pseudomonas* species.¹⁴

CONCLUSION

From the above results, the authors concluded that for the treatment of patients with ocular infections, the efficacy of ofloxacin in comparison with chloramphenicol has clinical equivalence. However, future studies are recommended.

REFERENCES

- Ramesh S, Ramakrishnan R, Bharathi M, Amuthan M, Viswanathan S. Prevalence of bacterial pathogens causing ocular infection in south India. *Indian J Pathol Microbiol.* 2010;53(2):281–6.
- Tesfaye T, Beyene G, Gelaw Y, Bekele S, Saravanan M. Bacterial Profile and Antimicrobial Susceptibility Pattern of External Ocular Infections in Jimma University Specialized Hospital, Southwest Ethiopia. *Am J Ophthalmol.* 2013;1:13–20.
- Sharma S. Antibiotics and Resistance in Ocular Infections. *Indian J Med Microbiol.* 2011;29:218–22.
- Sthapit PR, Tuladhar NR, Marasini S, Khoju U, Thapa G. Bacterial Conjunctivitis and Use of Antibiotics in Dhulikhel Hospital - Kathmandu University Hospital. *Kathmandu Univ Med J.* 2011;9:69–72.
- Whitcher JP, Srinivasan M, Upadhyay MP. Corneal blindness: a global perspective. *Bull World Health Organ.* 2001;79:214–21.
- Gopinath U, Sharma S. Review of epidemiological features, microbiological diagnosis and treatment outcome of microbial keratitis. Experience over a decade. *Indian J Ophthalmol.* 2009;57:273–79.
- Sharma V, Sharma S, Garg P, Rao GN. Clinical resistance of staphylococcus keratitis to ciprofloxacin monotherapy. *Indian J Ophthalmol.* 2004;52:287–92.
- Klotz SA, Penn CC, Negvesky GJ, Butrus SI. Fungal and parasitic infections of the Eye. *ClinMicrobiol Rev.* 2000;13(4):662–85.
- Miller JJ, Scott IU, Flynn HW Jr, Smiddy WE, Newton J, Miller D. Acute onset endophthalmitis after cataract surgery (2000-2004): Incidence, clinical settings and visual acuity outcome after treatment. *Am J Ophthalmol.* 2005;139(6):983–87.
- Bharathi MJ, Ramakrishnan R, Shivakumar C, Meenakshi R, Lionalraj D. Infectious diseases and microbiology. *Indian J Ophthalmol.* 2010;58(6):497–507.
- Shiferaw B, Gelaw B, Assefa A, Assefa Y, Addis Z. Bacterial isolates and their antimicrobial susceptibility pattern among patients with external ocular infections at Borumeda hospital, Northeast Ethiopia. *BMC Ophthalmology.* 2015;15:103. doi:10.1186/s12886-015-0078-z.
- Mshangila B, Paddy M, Kajumbula H, Ateenyi-Agaba C, Kahwa B, Seni J. External ocular surface bacterial isolates and their antimicrobial susceptibility patterns among pre-operative cataract patients at Mulago National Hospital in Kampala, Uganda. *BMC Ophthalmology.* 2013;13:71. doi:10.1186/1471-2415-13-71.
- Bron AJ, Leber G, Rizk SN, et al. Ofloxacin compared with chloramphenicol in the management of external ocular infection. *The British Journal of Ophthalmology.* 1991;75(11):675–679.
- Hemavathi, Sarmah P, Shenoy P. Profile of Microbial Isolates in Ophthalmic Infections and Antibiotic Susceptibility of the Bacterial Isolates: A Study in an Eye Care Hospital, Bangalore. *Journal of Clinical and Diagnostic Research: JCDR.* 2014;8(1):23-25. doi:10.7860/JCDR/2014/6852.3910.

Source of support: Nil

Conflict of interest: None declared

This work is licensed under CC BY: *Creative Commons Attribution 3.0 License.*