

Original Article

A Retrospective Study to assess Clinico-Pathological Characteristics of Appendicitis Patients

Rishi Kant Aryal¹, Rakchhya Gautam²

¹MS (General Surgery), Assistant professor / Consultant, Devdaha Medical College, Teaching Hospital, Rupendehi, Nepal

²MD (Paediatrics), Lecturer, Devdaha Medical College, Teaching Hospital, Rupendehi, Nepal


ABSTRACT:

Introduction- Acute appendicitis is the inflammation of appendix. It is clinical syndrome requires immediate surgery. The present study was conducted to assess the cases and associated symptoms of appendicitis recorded in the department of General Surgery. **Materials & Methods-** It included 238 cases of appendicitis of both gender. General information such as name, age, gender etc. was recorded and patients were operated and confirmed by histopathologically. **Results-** Out of 238 patients, males were 142 (62%) and females were 96 (38%). The difference was significant ($P < 0.05$). Age group < 10 had 7 males and 8 females, 10-20 years had 35 males and 20 females, 20-30 years had 50 males and 33 females, 30-40 years had 21 males and 12 females, 40-50 years had 18 males and 10 females and > 50 years had 11 males and 13 females. The difference was significant ($P < 0.05$). Common symptoms were pain abdomen (236), fever (210) and vomiting (125). Histopathologically patients were diagnosed as acute appendicitis (AP) (119), AP with periappendicitis (3), chronic appendicitis (4), lymphoid hyperplasia (50) and resolving appendicitis (60). The difference was significant ($P < 0.05$). **Conclusion-** Male predilection was observed in present study. Age group 20-30 showed higher prevalence over other age groups.

Key words- Appendicitis, Fever, Lymphoid hyperplasia

Corresponding author: Dr. Rishi Kant Aryal, MS (General Surgery), Assistant professor / Consultant, Devdaha Medical College, Teaching Hospital, Rupendehi, Nepal

This article may be cited as: Aryal RK, Gautam R. A Retrospective Study to assess Clinico-Pathological Characteristics of Appendicitis Patients. J Adv Med Dent Scie Res 2017;5(11):49-51.

Access this article online	
 <p>Quick Response Code</p>	Website: www.jamdsr.com
	DOI: 10.21276/jamdsr.2017.5.11.12

INTRODUCTION

Acute appendicitis is the inflammation of appendix. It is clinical syndrome requires immediate surgery. The vermiform appendix is considered by most to be a vestigial organ. It is very painful condition affecting higher amount of general population with males being affected more as compared to females with male: female ratio of 1.4:1. It affects all age groups.¹

The vermiform appendix is a tubular diverticulum which arises from the posteromedial wall of the cecum, about 30 mm below the ileocecal valve. The tip of appendix is variable in position and might lie in a retrocecal, subcecal, retroileal, preileal or pelvic location. The variability in location may influence the clinical presentation of appendicitis.²

Appendectomy is the gold standard of treatment for acute appendicitis whereby, inflamed appendix is removed. If untreated, it may lead to several clinical complications, which may be fatal eventually. Appendectomy is one of the most frequent surgical procedures performed. Clinical studies may determine the best practice in the management

of acute appendicitis. The knowledge about the clinical profile of appendicitis and appendectomy cases is an important milestone in public health.³

Still acute appendicitis has remained the most common acute surgical condition of the abdomen in all ages and evidently a common disease in surgical practice. Even after a long period of about more than 120 years from its first depiction this common surgical disease continues to remain a diagnostic problem and can confuse most of the clinicians. Delay in diagnosis definitely increases the morbidity, mortality, and expenditure of management and in equivocal ca destructive surgical approach too.⁴

The present study was conducted to assess the cases and associated symptoms of appendicitis recorded in the department.

MATERIALS & METHODS

The present study aimed at recording various symptoms and cases visiting the department with chief complaint of appendicitis. It included 238 cases of appendicitis of both gender diagnosed through ultrasonography.

Patients were informed regarding the study and written consent was obtained. Ethical clearance was obtained from institutional ethical committee. General information such as name, age, gender etc. was recorded and patients were

operated and confirmed by histopathologically. Results thus obtained were subjected to statistical analysis. Chi- square test was done and P value less than 0.05 was considered statistical significant.

RESULTS

Table Distribution of subjects

Total - 238		
Male	Female	P value
142 (62%)	96 (38%)	0.05

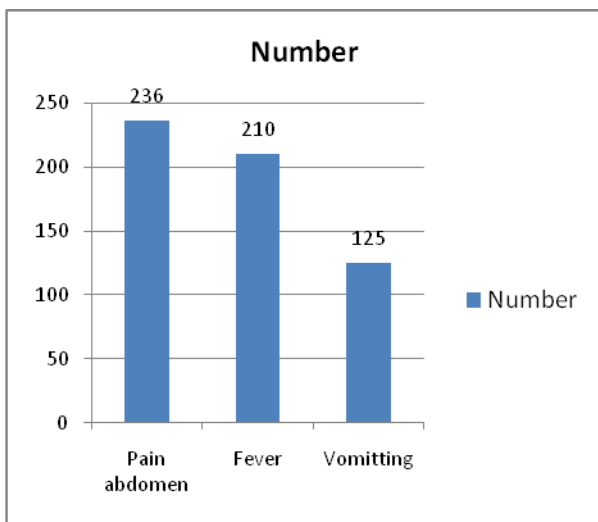
Table I shows that out of 238 patients, males were 142 (62%) and females were 96 (38%). The difference was significant (P- 0.05).

Table II Age wise distribution of patients

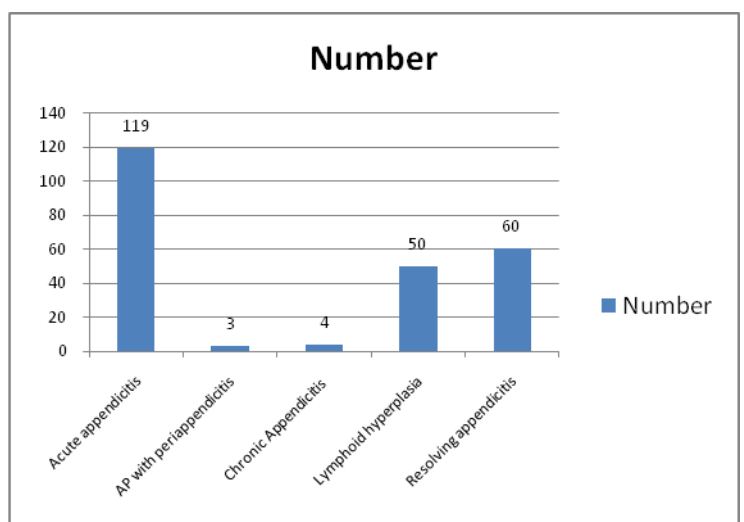
Age group (years)	Males	Females
<10	7	8
10-20	35	20
20-30	50	33
30-40	21	12
40-50	18	10
>50	11	13
Total	142	96

Table II shows that age group <10 had 7 males and 8 females, 10-20 years had 35 males and 20 females, 20-30 years had 50 males and 33 females, 30-40 years had 21 males and 12 females, 40-50 years had 18 males and 10 females and >50 years had 11 males and 13 females. The difference was significant (P<0.05).

Graph I Common symptoms recorded



Graph II Distribution of the patients as per the histopathological diagnosis



Graph I shows that common symptoms were pain abdomen (236), fever (210) and vomiting (125).

Graph II shows that histopathologically patients were diagnosed as acute appendicitis (AP) (119), AP with periappendicitis (3), chronic appendicitis (4), lymphoid hyperplasia (50) and resolving appendicitis (60). The difference was significant (P< 0.05).

DISCUSSION

Acute appendicitis is a common lesion nowadays. It causes severe pain which needs to be diagnosed immediately for the relief.⁵ In our study, out of 238 patients, males were 62% and females were 38%. This is in agreement with the results of study by Primatesta.⁶

A diagnosis of appendicitis was most likely in a patient with the presence of pain, vomiting, and fever. Severe pain at the peri-umbilical region to the right lower quadrant with rigidity is classical signs and symptoms of appendicitis. In retrocecal appendix, the patient with appendicitis experiences pain on extension of right hip joint due to tension. The anatomical factors producing inflammation may be due to the presence of fecolith, appendix supplied by an end artery, or even deficiency in the muscular wall. Sometimes, blockage of the appendix is due to a buildup of thick mucus within it. Owing to infection, the lymphatic tissue present in the appendix might enlarge and obstruct its lumen.⁷ This attracts the normal flora found within the appendix to invade its wall. The body responds to this process by attacking the bacteria. Untreated, patients with appendicitis develop complications such as gangrene, perforation, and abscess formation.

The inflammation may spread through the wall of the appendix which may result in rupture of the inflamed appendix. The consequence of rupture of appendix is spread of infection throughout the abdomen. However, mostly it is confined to a small area surrounding the appendix. Acute appendicitis may occur at any age, although it is relatively uncommon in the two extremes of life, i.e. in infants because of relatively wide lumen of the appendix and in elderly due to frequent obliteration of the lumen.⁸ In present study common symptoms were pain in abdomen recorded in all 236, fever in 210 patients and vomiting (125). This is in agreement with Rothrok SG.⁹

We found that maximum cases were recorded in age group 20-30 years (50 males, 33 females), 10-20 years (5 males, 20 females), 30-40 years (21 males, 12 females), 40-50 years (18 males, 10 females), >50 years (11 males, 13 females) and <10 had 7 males and 8 females. This is similar to Khairy G.¹⁰

After operating for appendicitis, we referred the tissue for histopathological diagnosis and lesions were diagnosed as acute appendicitis (AP) (119), AP with periappendicitis (3), chronic appendicitis (4), lymphoid hyperplasia (50) and resolving appendicitis (60). This is similar to Al-Omran.¹¹

CONCLUSION

Appendicitis found to be more in males as compared to females. Age group 20-30 years had significantly higher prevalence rate as compared to other age groups.

REFERENCES

1. Noudeh YJ, Sadigh N, Ahmadnia AY. Epidemiologic features, seasonal variations and false positive rate of acute appendicitis in Shahre-Rey, Tehran. *Int J Surg* 2007; 5: 95-98.
2. Oguntola AS, Adeoti ML, Oyemolade TA: Appendicitis: Trends in incidence, age, sex, and seasonal variations in South-Western Nigeria. *Ann Afr Med* 2010; 9: 213-217.
3. Sanda RB, Zalloum M, El-Hossary M, Al Rashid F, Ahmed O, Awad A, Farouk A, Seliemt S, Mogazy K. Seasonal variation of appendicitis in northern Saudi Arabia. *Ann Saudi Med* 2008; 28: 140-141.
4. Birnbaum BA, Wilson SR. Appendicitis at the millennium. *Radiology* 2000; 215: 337- 348.
5. Piccinni G, Sciusco A, Gurrado A, Lissidini G, Testini M. The "BASE-FIRST" technique in laparoscopic appendectomy. *J Minimal Access Surg* 2012;8: 6-8.
6. Primatesta P, Goldacre MJ. Appendicectomy for acute appendicitis and for other conditions: an epidemiological study. *Int J Epidemiol* 1994; 23: 155-160.
7. Chang FC, Hogle HH, Welling DR. The fate of negative appendix. *Am J Surg* 1973; 126: 752-754.
8. Bell MJ, Bower RJ, Ternberg JL. Appendicectomy in childhood. Analysis of 105 negative appendixes. *Am J Surg* 1982; 144: 335-337.
9. Rothrock SG, Pagane J. Acute appendicitis in children: Emergency department diagnosis and management. *Ann Emerg Med* 2000; 36: 3951.
10. Khairy G. Acute appendicitis: Is removal of a normal appendix still existing and can we reduce its rate? *Saudi J Gastroenterol* 2009;15:167170.
11. Al-Omran M, Mamdani M, McLeod RS. Epidemiologic features of acute appendicitis in Ontario, Canada. *Can J Surg* 2003; 46: 263-268.

Source of support: Nil

Conflict of interest: None declared

This work is licensed under CC BY: *Creative Commons Attribution 3.0 License*.