

CASE REPORT

Surgical management of combined apico-marginal and through & through peri-radicular lesion with GTR using bio-resorbable membrane, microscope and cone beam computed tomography: A Case Report

Pragnesh D Parmar¹, Ramandeep Kaur², Natwar Singh³

¹MDS, Department of Conservative Dentistry & Endodontics, Post Graduate Institute of Dental Sciences (PGIDS), Rohtak(Haryana), India

²Post graduate student, Department of Periodontology, Government Dental College & Hospital, Amritsar (Punjab), India

³Post graduate student, Department of Conservative Dentistry & Endodontics, Post Graduate Institute of Dental Sciences (PGIDS), Rohtak (Haryana), India

ABSTRACT

A number of diagnostic and management challenges exist for achieving complete regeneration of large through and through periapical lesions. An unfavorable endodontic outcome may occur as a result of uncontrolled infection or unpredictable bone healing. The presence of an apicomarginal defect is also one of the reasons for the failure of endodontic treatment. The best treatment option to treat an apicomarginal defect is to perform endodontic surgery using Guided Tissue Regeneration (GTR) membranes. A few recent studies have reported favorable outcome for treatment of apicomarginal and through & through defects using GTR. CBCT imaging provides clinicians with a clear view of the anatomic relationship between root apices and neighboring structures, such as the mandibular canal, mental foramen, and maxillary sinus it also suggests where access osteotomies can be performed enabling minimally invasive surgery. This article presents a case with a large through and through periapical lesion and apicomarginal defects. Endodontic microsurgery and guided tissue regeneration were performed using a resorbable membrane. Preoperative and one year post-operative CBCT were compared for healing of lesion. 1 year post-operative CBCT showed more than 90% healing of periapical lesion and significant healing of apico-marginal lesion.

Key words: Through & through lesion, apico-marginal lesion, CBCT, microsurgery, guided tissue regeneration, bio-resorbable membrane.

Received: 14 October 2018

Revised: 27 October 2018

Accepted: 28 October 2018

Corresponding author: Dr. Pragnesh D Parmar, MDS, Department of Conservative Dentistry & Endodontics, Post Graduate Institute of Dental Sciences (PGIDS), Rohtak(Haryana), India

This article may be cited as: Parmar PD, Kaur R, Singh N. Surgical management of combined apico-marginal and through & through peri-radicular lesion with GTR using bio-resorbable membrane, microscope and cone beam computed tomography: A Case Report. J Adv Med Dent Scie Res 2018;6(11):42-47.

INTRODUCTION

Most large periradicular defects occur in patients with sustained periapical inflammation¹ combined with periodontal-endodontic lesions^{2,3}, a trauma history^{4,5}, developmental anomalies such as dens invaginatus⁶⁻⁸, or cystic lesions.^{4,9} To manage large periapical lesions, conventional nonsurgical endodontic treatments or further surgical interventions are generally considered. However, the prognosis for treating large periapical lesions might not be as good as that of small

lesions. With large endodontic lesions, there is often the chance for an enhanced inflammatory reaction and prolonged infection. Unreliable tissue repair following conventional root canal therapy may occur.^{4,10} With nonsurgical endodontic treatment, Weigeretal¹¹ and Matsumoto et al¹² demonstrated an elevated risk of failure when apical lesions were > 5 mm. Caliskan⁴ also reported that teeth with larger periapical lesions showed a lower rate of complete healing and a higher incidence of failure. In cases treated with conventional periapical

surgery, Hirsch et al¹³ showed that teeth with apical destruction of >5 mm had a healing frequency of 39%, while teeth with destruction of ≤5 mm exhibited a healing frequency of 55%. Furthermore, if the apical lesion had neither buccal nor lingual walls, complete healing was significantly reduced to 25%. They concluded that more extensive periapical destruction had a tendency toward less predictable healing. The use of a membrane technique in guided tissue regeneration (GTR) is widely applied in periodontology and implant dentistry. The GTR principle involves the use of a physiologic barrier over the bone defect to preclude the oral epithelium or gingival connective tissue from growing into the bone space so that cells with osteogenic potential can repopulate the defective area^{14,15}. Based on favorable outcomes with periodontal applications, the GTR principle is currently applied as an adjunct to enhance bone healing for various advanced endodontic lesions, such as furcation perforations^{16,17}, soft tissue fenestration defects¹⁸ and combined periodontal-endodontic lesions such as communication of dehiscence bony defect with periapical lesions^{2,19} large periapical bony defects^{20,21} and through and through periapical lesions.²² Reports in the literature on the clinical efficacy of GTR used for through and through periapical lesions are limited. Taschieri et al²² claimed an 88% success rate using periapical surgery with a barrier membrane and osseous graft to treat cases of through and through lesions in a 1 year prospective clinical study. However, there are limited reports in the literature on long-term evaluations of the GTR technique for such lesions. The purpose of this article was to present a case of a large through and through and apicomarginal lesion treated with GTR that showed promising results.

CASE REPORT

A 32-year-old male patient, in general good health, presented to department of Conservative Dentistry and Endodontics, PGIDS Rohtak with a mandibular central incisors exhibiting vague, non-specific symptoms. Radiographic examination (radiovisualgraphy) revealed the presence of a large periradicular lesion of endodontic origin as probing depths were within normal limit even though x-ray clearly suggesting absent of inter-radicular bone (Fig. 1A). The right and left central incisors had no vital signs and symptoms (EPT and COLD test). CBCT revealed the presence of a through and through lesion and combined apico-marginal lesion (Fig 1D-1H). Baseline clinical attachment level (CAL), probing depth (PD) and gingival marginal position (GMP) were within normal limit (Fig 2A). Based on primary examination diagnosis of primary endodontic lesion with secondary periodontal involvement was made with necrosis of both mandibular central incisors. So thorough prophylaxis and conventional endodontic treatment was initiated (Fig. 1B & 1C). Patient was kept on regular follow up for 3 months, but even after 3 months no radiographic improvement was noticed and

patient also reported occasional pain during same period. As a consequence, a periradicular surgical approach of both the teeth using a new GTR technique was decided.

SURGICAL TECHNIQUE

With the exception of incisions, flap elevation and suturing, all surgical procedures were performed under operating microscope in an operating room under 8x to 16x magnification.

The full thickness (mucoperiosteal flap) was reflected under aseptic condition by the following technique-

Preoperative mouth rinse with 0.2% chlorhexidine mouthwash was used for 1 minute. Local anaesthesia with lidocaine 2% with epinephrine 1:80,000 was achieved. Buccal intrasulcular incision was given up to the alveolar crest including one tooth mesial to the lesion & one tooth distal to the lesion, using no.15 blade on handle (Fig. 2B). Mesial and distal vertical releasing incision was given. Full thickness flap was gently reflected towards the apical area by periosteal elevator. The flap was frequently irrigated with sterile saline to prevent dehydration of periosteal surface. After complete elevation of the flap, debridement (periradicular curettage –enucleation) of the bony lesion was performed (Fig. 2C). For additional hemostasis during surgery, cotton pellets soaked in 0.1% epinephrine was applied topically as required. A 2-3mm root tip with a 0° to 10° bevel angle was sectioned with cylindrical surgical carbide burs (#557 SL) at high speed with sterile saline coolant (Fig. 2C). Root end preparations extending 3mm into the canal space along the long axis of the root was made by using a piezoelectric ultrasonic system with double angled retrotips (Satelac S12-70D) coated with diamond abrasives.

Isthmuses, fins, and other significant anatomic irregularities were identified in high magnification and were treated with the ultrasonic instruments. Then the resected root surfaces were stained with 1% methylene blue for 10 to 15 seconds with microbrush and were inspected with micromirrors under high magnification of 24x to examine the cleanliness of the root end preparation and detect any other overlooked anatomic details. Root end filling was done with mineral trioxide aggregate (MTA). The adaptation of the filling material to the canal apical walls was confirmed with the aid of an operating microscope at high magnification. After MTA retrofilling, resorbable collagen membrane (HEALIGUIDE) was applied on buccal side as such that the membrane extends 2-3 mm in apical, mesial and distal area of the defect (Fig. 2D), at the time of membrane application it was made sure that the operated area is not dried and bleeding was induced by irrigating the area with normal saline to keep the operated area wet. After cutting the membrane in proper shape and size membrane was stabilized by applying gentle pressure with finger and the flap was re-approximated and sutured with 5-0 reverse cutting black silk suture.

Figure 1: Pre-operative records

A- pre-operative x-ray, B- working length, C- obturation x-ray, D to F- axial, coronal and sagittal view cbct, G & H- 3D reconstructive buccal and lingual view

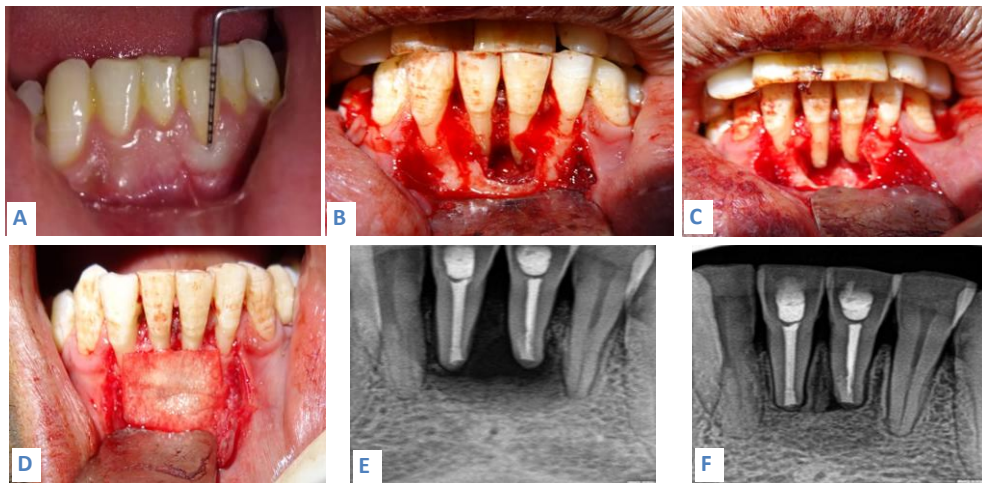
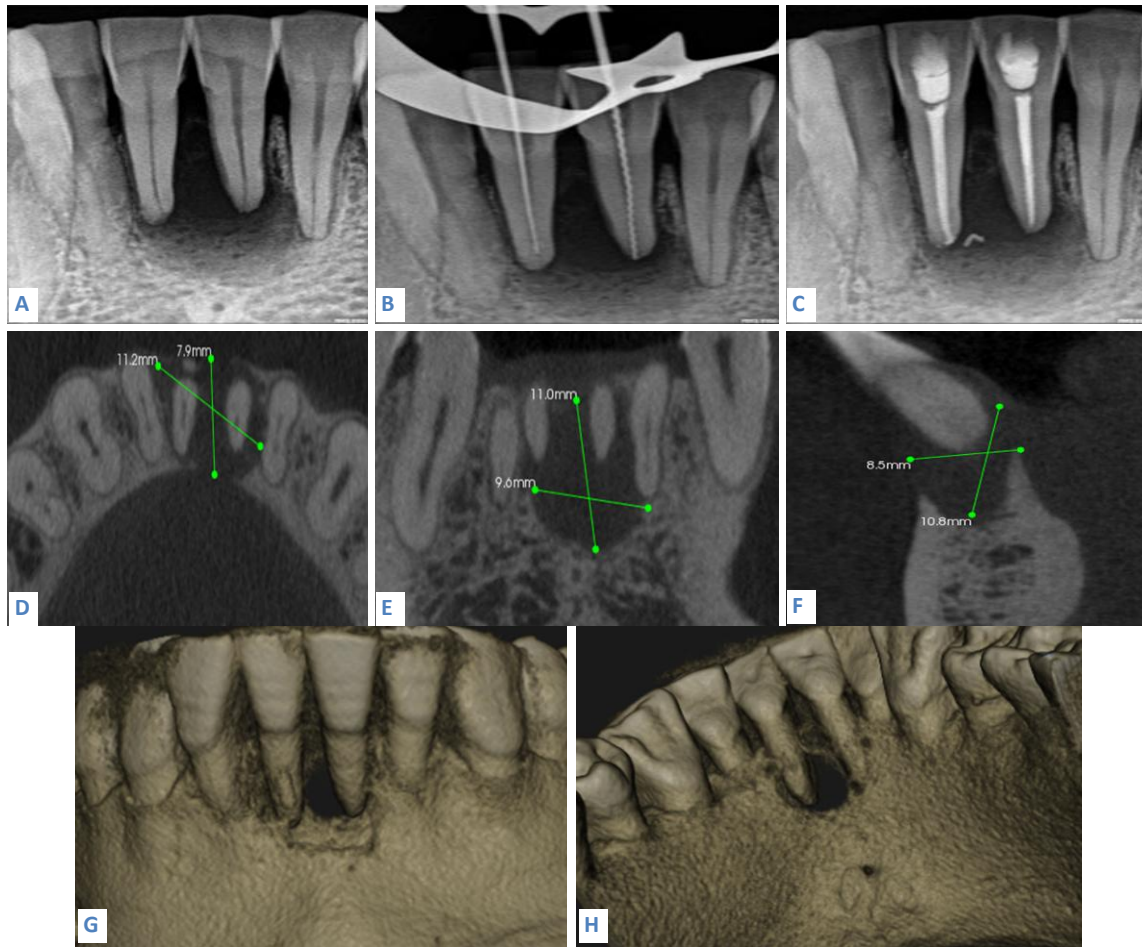


Figure 2: Intra-operative photograph and post-operative x-rays

A- probing depth, B- full muco-periosteal flap elevation, C- removal of pathology and root resection, D- application of membrane, E- immediate post-operative x-ray, F- 12 month x-ray

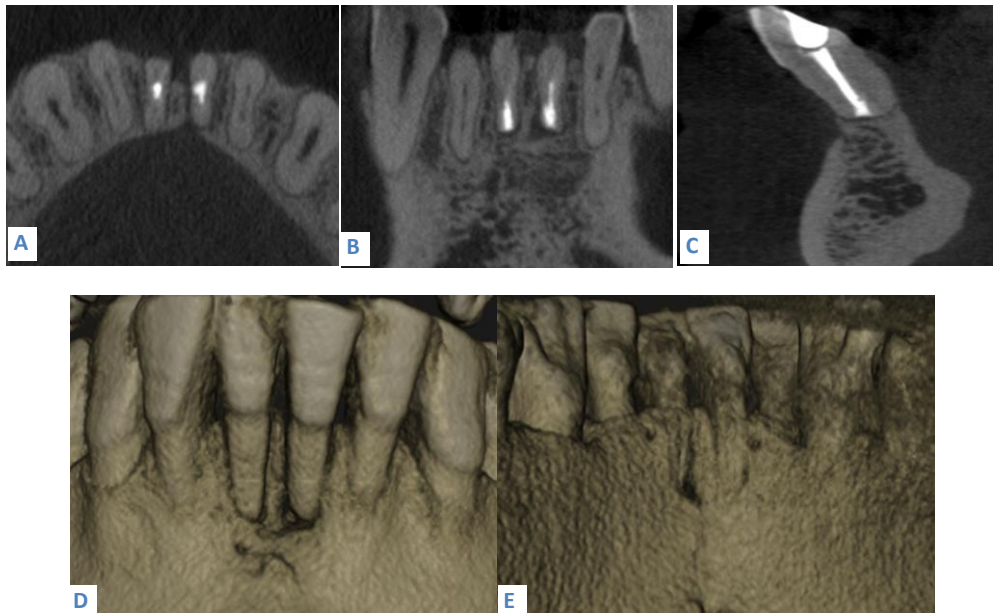


Figure 3: Post-operative CBCT
A to C- axial, coronal and sagittal view, D & E- 3D reconstructive buccal and lingual view

Antibiotics (500 mg amoxicillin 3 times daily), analgesics (25 mg diclofenac every 4 to 6 hours as needed for pain), and an oral rinse with 0.2% chlorhexidine gluconate were prescribed for 7 days post-operatively. All sutures were removed 1 week after surgery, and healing was uneventful. The patient was recalled periodically, and long term radiographic follow-up showed gradual improvement of the periapical radiolucency. X-rays suggested almost complete healing one year later (Fig. 2E & 2F), so to confirm it more evidentially post-operative CBCT was suggested. Coronal, sagittal and axial views confirmed more than 95% healing of periapical lesion but buccal bone regeneration was not significantly evident (Fig 3A-3E).

DISCUSSION

It is generally thought that endodontic lesions, even with large periapical radiolucencies, can heal or regress after complete removal of the intracanal irritants by conventional endodontic treatment alone^{4,10}. However, additional surgery may be required if nonsurgical root canal therapy is unsuccessful in resolving the periradicular pathosis. In this case, the large apical lesion remained unimproved and radiolucency persisted after long term calcium hydroxide root canal dressing and obturation. The patient was therefore scheduled for further periapical surgery that provides better access to clean the inflamed apical root canal and remove the periapical pathosis. In this case, the defect openings were covered with resorbable membranes. Although traditional endodontic surgery for large periapical lesions can be effective¹⁴, scar tissue formation during tissue repair is sometimes observed with through-and-through

periapical lesions.^{23,24} To achieve better tissue regeneration, GTR principles using a barrier membrane and/or an osseous graft were recently suggested as an adjunct to endodontic surgery for endodontic-related defects. Particularly, with through and through periapical defects, some animal and clinical studies demonstrated the effectiveness of GTR techniques. In surgically created through-and-through bone defects in conjunction with an apicectomy of the lateral maxillary incisors in monkeys, all expanded poly tetrafluoroethylene (e-PTFE) membrane-covered defects had healed with bone closure and only a minute portion exhibited connective tissue after a 3-month healing period. In contrast, defects that were not covered with membranes were filled with fibrous connective tissue.²⁵ In a clinical study conducted by Pecora et al²¹ the results revealed that the use of GTR principles enhanced the quality and quantity of bone regeneration in large periapical defects, especially in through-and-through lesions. Taschieri et al²² also found that 1 year postoperatively, through and through periapical defects treated by GTR techniques had a greater chance of complete radiographic healing than lesions in which grafts or membranes were not placed. In the present case, regression of the apical lesion was obvious at the 9-month follow-up, and the lesion had almost completely healed by the 12-month follow-up. A wide variety of membrane materials are applied in clinics. The most commonly used non absorbable membrane is the e-PTFE membrane, and widely used resorbable membranes include collagen, polylactic acid, polyglactin, and copolymers of glycolide and lactide.²⁶ Nonabsorbable membranes are more rigid and

capable of maintaining space for bone healing. However nonabsorbable membranes must be removed in a second operation. Although the space-making effect of resorbable membranes is not as good as that of nonabsorbable membranes, it is effective at promoting regeneration in apical defects.^{27,28}

A resorbable membrane provide enough rigidity for space maintenance; therefore, an osseous substitute was not combined as a scaffold for the GTR procedure. The benefits from the adjunctive use of an osseous graft in periapical surgery are controversial. Tobon et al²⁹ demonstrated that the combined use of bone grafting material in GTR procedures enhanced periapical tissue regeneration, whereas Britain et al²⁷ and von Arx et al³⁰ showed no additional effects. Further controlled clinical and histologic studies with large sample sizes are needed to confirm the biologic nature of new tissue formed after combining bone grafting materials and barrier membranes for through and through periapical lesions. Early extraction of the infected tooth with a large bony lesion was not considered in this case because removing a tooth with an extensive periapical defect may be accompanied by severe alveolar bone loss in the anterior mandible, which would compromise the esthetic outcome of future restorations. Through comprehensive multidisciplinary cooperation, the large periapical defect in the presented case had almost completely healed 1 years postoperatively. The 1 years success of this case infers that large through-and-through apical defects can be regenerated through combined endodontic and periodontal treatment. Complete bone healing provides periodontal health and soft tissue esthetics of the restored tooth, while also creating bone mass that facilitates implant placement if the tooth cannot be restored.

CONCLUSION

Based on 1 year post-operative CBCT findings this study concludes that periapical lesion generally heals within a year if proper protocol and microsurgery principles are followed. Resorbable membrane helps in regeneration of apical bone to a greater extent but according to post-operative CBCT, buccal bone regeneration in case of apico-marginal lesion generally takes longer time to heal completely than apical bone.

ACKNOWLEDGEMENTS

The authors reported no conflicts of interest related to this study.

REFERENCES

1. Ricucci D, Siqueira JF Jr. Anatomic and microbiologic challenges to achieving success with endodontic treatment: A case report. *J Endod* 2008;34:1249–1254.
2. Abramowitz PN, Rankow H, Trope M. Multidisciplinary approach to apical surgery in conjunction with the loss of buccal cortical plate. *Oral Surg Oral Med Oral Pathol* 1994;77:502–506.

3. Uchin RA. Use of a bioresorbable guided tissue membrane at an adjunct to bony regeneration in cases requiring endodontic surgical intervention. *J Endod* 1996; 22:94–96.
4. Caliskan MK. Prognosis of large cyst-like periapical lesions following nonsurgical root canal treatment: A clinical review. *IntEndod J* 2004;37:408–416.
5. Rodrigues CD, Estrela C. Traumatic bone cyst suggestive of large apical periodontitis. *J Endod* 2008;34:484–489.
6. Altuntas A, Cinar C, Akal N. Endodontic treatment of immature maxillary lateral incisor with two canals: Type 3 dens invaginatus. *Oral Surg Oral Med Oral Pathol Oral RadiolEndod* 2010;110:e90–93.
7. Er K, Kustarci A, Ozan U, Tasdemir T. Nonsurgical endodontic treatment of dens invaginatus in a mandibular premolar with large periradicular lesion: A case report. *J Endod* 2007;33:322–324.
8. Lichota D, Lipski M, Wozniak K, Buczkowska-Radlinska J. Endodontic treatment of a maxillary canine with type 3 dens invaginatus and large periradicular lesion: A case report. *J Endod* 2008;34:756–758.
9. Gibson GM, Pandolfi PJ, Luzader JO. Case report: A large radicular cyst involving the entire maxillary sinus. *Gen Dent* 2002;50:80–81.
10. Lin LM, Ricucci D, Lin J, Rosenberg PA. Nonsurgical root canal therapy of large cyst-like inflammatory periapical lesions and inflammatory apical cysts. *J Endod* 2009;35:607–615.
11. Weiger R, Rosendahl R, Lost C. Influence of calcium hydroxide intracanal dressings on the prognosis of teeth with endodontically induced periapical lesions. *IntEndod J* 2000;33:219–226.
12. Matsumoto T, Nagai T, Ida K, et al. Factors affecting successful prognosis of root canal treatment. *J Endod* 1987;13:239–242.
13. Hirsch JM, Ahlstrom U, Henrikson PA, Heyden G, Peterson LE. Periapical surgery. *Int J Oral Surg* 1979;8:173–185.
14. Lin L, Chen MY, Ricucci D, Rosenberg PA. Guided tissue regeneration in periapical surgery. *J Endod* 2010;36:618–625.
15. von Arx T, Cochran DL. Rationale for the application of the GTR principle using a barrier membrane in endodontic surgery: A proposal of classification and literature review. *Int J Periodontics Restorative Dent* 2001;21:127–139.
16. Duggins LD, Clay JR, Himel VT, Dean JW. A combined endodontic retrofill and periodontal guided tissue regeneration technique for the repair of molar endodontic furcation perforations: Report of a case. *Quintessence Int* 1994;25:109–114.
17. Goon WW, Lundergan WP. Redemption of a perforated furcation with a multidisciplinary treatment approach. *J Endod* 1995;21:576–579.
18. Tseng CC, Chen YH, Huang CC, Bowers GM. Correction of a large periradicular lesion and mucosal defect using combined endodontic and periodontal therapy: A case report. *Int J Periodontics Restorative Dent* 1995;15:377–383.
19. Blank BS, Levy AR. Combined treatment of a large periodontal defect using GTR and DFDBA. *Int J Periodontics Restorative Dent* 1999;19:481–487.
20. Brugnami F, Mellonig JT. Treatment of a large periapical lesion with loss of labial cortical plate using GTR: A case report. *Int J Periodontics Restorative Dent* 1999;19:243–249.
21. Pecora G, Kim S, Celletti R, Davarpanah M. The guided tissue regeneration principle in endodontic surgery: One-year

- postoperative results of large periapical lesions. *Int Endod J* 1995;28:41–46.
22. Taschieri S, Del Fabbro M, Testori T, Saita M, Weinstein R. Efficacy of guided tissue regeneration in the management of through-and-through lesions following surgical endodontics: A preliminary study. *Int J Periodontics Restorative Dent* 2008;28:265–271.
 23. Andreasen JO, Rud J. Modes of healing histologically after endodontic surgery in 70 cases. *Int J Oral Surg* 1972;1:148–160.
 24. Rud J, Andreasen JO, Jensen JF. A multivariate analysis of the influence of various factors upon healing after endodontic surgery. *Int J Oral Surg* 1972;1:258–271.
 25. Dahlin C, Gottlow J, Linde A, Nyman S. Healing of maxillary and mandibular bone defects using a membrane technique. An experimental study in monkeys. *Scand J Plast Reconstr Surg Hand Surg* 1990;24:13–19.
 26. Bashutski JD, Wang HL. Periodontal and endodontic regeneration. *J Endod* 2009;35:321–328.
 27. Britain SK, Arx T, Schenk RK, Buser D, Nummikoski P, Cochran DL. The use of guided tissue regeneration principles in endodontic surgery for induced chronic periodontic-endodontic lesions: A clinical, radiographic, and histologic evaluation. *J Periodontol* 2005;76:450–460.
 28. Douthitt JC, Gutmann JL, Witherspoon DE. Histologic assessment of healing after the use of a bioresorbable membrane in the management of buccal bone loss concomitant with periradicular surgery. *J Endod* 2001;27:404–410.
 29. Tobon SI, Arismendi JA, Marin ML, Mesa AL, Valencia JA. Comparison between a conventional technique and two bone regeneration techniques in periradicular surgery. *Int Endod J* 2002;35:635–641.
 30. Von Arx T, Britain S, Cochran DL, Schenk RK, Nummikoski P, Buser D. Healing of periapical lesions with complete loss of the buccal bone plate: A histologic study in the canine mandible. *Int J Periodontics Restorative Dent* 2003;23:157–167.

Source of support: Nil

Conflict of interest: None declared

This work is licensed under CC BY: ***Creative Commons Attribution 3.0 License.***