

CASE REPORT

Case Report of Creatine Transporter Deficiency

Suhani Patel¹, Nivedita Patil², Gargi Chaphekar³

^{1,3}Junior resident, ²Professor, Department of Pediatrics, D.Y. Patil hospital & Research Centre, Kadamwadi, Kolhapur-416003, Maharashtra, India

ABSTRACT:

The Cerebral Creatine Deficiency Syndromes (CCDS), are inborn errors of creatine metabolism which include Creatine Transporter Deficiency (CTD) and the two creatine biosynthesis disorders, guanidinoacetate methyltransferase (GAMT) deficiency and L-arginine:glycine amidino transferase (AGAT) deficiency.^{1, 2} Creatine Transporter Deficiency (CTD, SLC6A8 Deficiency, CRTR) is a rare X-linked inborn error of creatine metabolism, broadly classified as an Autism Spectrum Disorder and form of X-linked intellectual disability and developmental delay. CTD is caused by a defect in the SLC6A8 gene that encodes the creatine transporter protein necessary for the transport of creatine across the blood-brain barrier and across cell membranes. In the present study, we present a case report of Creatine Transporter Deficiency in a 1.5 years old male child.

Key words: Creatine Deficiency Syndromes, Creatine Transporter Deficiency.

Received: 13 September 2018

Revised: 12 November 2018

Accepted: 15 November 2018

Corresponding Author: Dr. Suhani Patel Junior resident, D.Y. Patil hospital & Research Centre, Kadamwadi, Kolhapur-416003, Maharashtra, India

This article may be cited as: Patel S, Patil N, Chaphekar G. Case Report of Creatine Transporter Deficiency. J Adv Med Dent Scie Res 2018;6(12):35-37.

INTRODUCTION:

The Cerebral Creatine Deficiency Syndromes (CCDS), are inborn errors of creatine metabolism which include Creatine Transporter Deficiency (CTD) and the two creatine biosynthesis disorders, guanidinoacetate methyltransferase (GAMT) deficiency and L-arginine:glycine amidino transferase (AGAT) deficiency.^{1,2} Creatine Transporter Deficiency (CTD, SLC6A8 Deficiency, CRTR) is a rare X-linked inborn error of creatine metabolism, broadly classified as an Autism Spectrum Disorder and form of X-linked intellectual disability and developmental delay. CTD is caused by a defect in the SLC6A8 gene that encodes the creatine transporter protein necessary for the transport of creatine across the blood-brain barrier and across cell membranes.³ Creatine is taken into cells via the creatine transporter, where it plays an essential role in energy homeostasis, particularly for tissues with high and fluctuating energy demands, such as neurons.⁴ Simply put, patients with CTD

lack creatine in the brain, which is an essential component of the energy system, and as a result the brain does not have the energy to function properly. This lack of energy results in the clinical signs and symptoms of CTD.⁵ In the present study, we present a case report of Creatine Transporter Deficiency in a 1.5 years old male child.

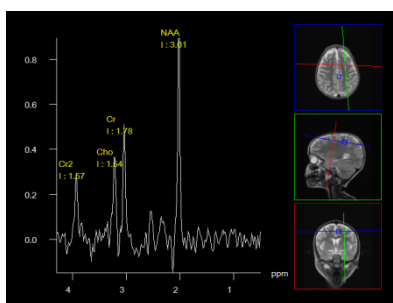
CASE REPORT:

A one and half years old male child, first issue of second-degree consanguineous marriage, brought with complaints of global developmental delay and 2 episodes of seizures in last 15 days, unprovoked, Generalized Tonic Clonic type, each episode lasted for maximum 4-5 min. No post ictal deficit. Baby was born full-term by LSCS, birth weight 2.2 kg, cried immediately after birth. Post-natal period uneventful.

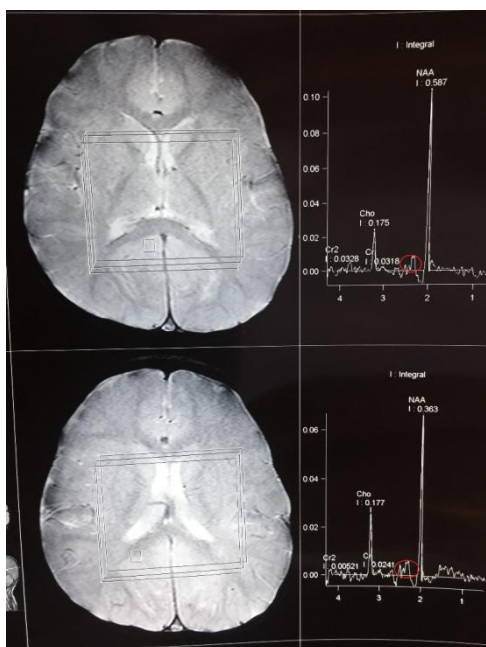Examination: He had microcephaly with head circumference of 44.5 cm. Had hypotonia – Grade 4.

Vision and hearing was normal. No motor deficit. Reflexes were preserved.

Lab investigations: Routine bio-chemistry was normal. EEG was normal. MRI brain was normal. MR Spectroscopy showed absent Cr peak confirming the diagnosis of CTD. The child was started on tablet Creatine 500mg bd. He had no seizures after that. He showed improvement in motor domain in the form of independent sitting achieved within 3 months after starting creatine supplement.



Normal MR spectroscopy



MR Spectroscopy shows Absence of Cr peak

DISCUSSION:

Creatine (Cr) plays an important role in the energy metabolism of cells and tissues with high and fluctuating energy demands such as the brain, as it facilitates the resynthesis of ATP from ADP through phosphocreatine.⁶ Creatine Transporter Deficiency (CTD) is an X-linked, inborn error of metabolism caused by mutations in the creatine transporter *SLC6A8* gene.⁷ The other two creatine deficiency syndromes are due to autosomal recessive defects of creatine synthesis: arginine:glycine amidinotransferase (AGAT) and guanidinoacetate methyltransferase (GAMT).⁸ In all of these disorders, the common manifestations are developmental delay leading to intellectual disability, language delay, and decreased brain creatine detected by magnetic resonance spectroscopy (MRS). CTD is characterized by moderate-to-severe intellectual disability, severe language delay, behavioral problems, seizures, gastrointestinal problems, normal plasma creatine and GAA levels, and elevated urine creatine/creatinine ratio (Cr/Crn); the diagnosis is confirmed by impaired creatine uptake in fibroblasts or identification of hemizygous mutations in *SLC6A8*. CTD is estimated to be present in 0.2–3.5% of males with intellectual disabilities (ID) or autism spectrum disorder (ASD), with average rates varying between 0.4% and 1.4%. Typically, Creatine Transporter Deficiency patients will present with missed standard developmental milestones around age of 1 or 2 years. As CTD is an X-linked disorder, male patients are the most severely affected, but females are carriers of the disease and may be asymptomatic or affected to a lesser degree.⁹⁻¹¹

Anselm IA et al reported two unrelated boys with the X-linked creatine transporter defect (CRTR) and clinical features more severe than those previously described with this disorder. These two boys presented at ages 12 and 30 months with severe mental retardation, absent speech development, hypotonia, myopathy and extra-pyramidal movement disorder. One boy has seizures and some dysmorphic features; he also has evidence of an oxidative phosphorylation defect. They both had classical absence of creatine peak on brain magnetic resonance spectroscopy (MRS). In one, however, this critical finding was overlooked in the initial interpretation and was discovered upon subsequent review of the MRS. Póo-Argüelles P et al described the first two unrelated Spanish patients with creatine transporter deficiency initially identified by brain proton magnetic resonance spectroscopy (MRS). The clinical phenotype was characterized by severe mental retardation, epilepsy, autism, severe speech delay and absence of brain creatine by MRS. Urine creatine/creatinine ratio was increased and creatine uptake in fibroblasts was impaired in both patients. On DNA sequence analysis of the *SLC6A8*/creatine transporter gene, one hemizygous mutation was found in each patient: one mutation was novel and consisted of a deletion of two nucleotides c.878-

879delTC in exon 5, resulting in a frameshift (p.Lys293fsX3), and in the other patient a known deletion of three nucleotides 1222-1224delTTC in exon 8 resulting in p.Phe408del. Creatine treatment for one year failed to improve the neurological symptoms and was associated with a striking increase in body weight in both patients (13 and 16 kg, respectively).^{12, 13} Mancardi MM et al reported a 5 year-old boy with known speech delay who presented with severe and refractory epilepsy. After extensive investigations, metabolite analysis and brain 1H-MRS suggested CRTR-D, which was confirmed by the detection of a known pathogenic mutation in the SLC6A8 gene (c.1631C>T; p.Pro544Leu).¹⁴

CONCLUSION:

Routine measurement of creatine by MRS should be considered in the evaluation of children with global developmental delay and unprovoked seizures as it is treatable condition.

REFERENCES:

1. "OMIM Entry - # 300352 - CEREBRAL CREATINE DEFICIENCY SYNDROME 1; CCDS1". www.omim.org. Retrieved 2016-11-27
2. L. Hanna-El-Daher, O. Braissant Creatine synthesis and exchanges between brain cells: what can be learned from human creatine deficiencies and various experimental models? *Amino Acids* (2016)
3. Akiyama T, Osaka H, Shimbo H, Nakajiri T, Kobayashi K, Oka M, Endoh F, Yoshinaga H. A Japanese adult case of guanidinoacetate methyltransferase deficiency. *JIMD Rep*. 2014;12:65–9.
4. Chilosi A, Leuzzi V, Battini R et al. (2008) Treatment with l-arginine improves neuropsychological disorders in a child with creatine transporter defect. *Neurocase* 14:151-161 [65]
5. Fons C, Sempere A, Arias A et al. (2008) Arginine supplementation in four patients with X-linked creatine transporter defect. *J Inherit Metab Dis* 31:724-728.
6. Wyss M, Kaddurah-Daouk R. Creatine and creatinine metabolism. *Physiol Rev*. 2000;80(3):1107–1213.
7. Salomons GS, van Dooren SJ, Verhoeven NM, et al. X-linked creatine-transporter gene (SLC6A8) defect: a new creatine-deficiency syndrome. *Am J Hum Genet*. 2001;68(6):1497–1500.
8. Longo N, Ardon O, Vanzo R, et al. Disorders of creatine transport and metabolism. *Am J Med Genet C Semin Med Genet*. 2011;157(1):72–78.
9. van de Kamp JM, Betsalel OT, Mercimek-Mahmutoglu S, et al. Phenotype and Genotype in 101 Males with X-Linked Creatine Transporter Deficiency. *J Med Genet*. 2013;50(7):463–472.
10. Ardon O, Amat di San Filippo C, et al. Creatine transporter deficiency in two half-brothers. *Am J Med Genet A*. 2010;152A(8):1979–1983.
11. Salomons GS, van Dooren SJ, Verhoeven NM, et al. X-linked creatine transporter defect: an overview. *J Inherit Metab Dis*. 2003;26(2–3):309–318.
12. Anselm IA, Alkuraya FS, Salomons GS, et al. X-linked creatine transporter defect: a report on two unrelated boys with a severe clinical phenotype. *J Inherit Metab Dis*. 2006;29(1):214-9.
13. Póo-Argüelles P, Arias A, Vilaseca MA, Ribes A, Artuch R, Sans-Fito A, Moreno A, Jakobs C, Salomons G. X-Linked creatine transporter deficiency in two patients with severe mental retardation and autism. *J Inherit Metab Dis*. 2006 Feb;29(1):220-3.
14. Mancardi MM, Caruso U, Schiaffino MC, Baglietto MG, Rossi A, Battaglia FM, Salomons GS, Jakobs C, Zara F, Veneselli E, Gaggero R. Severe epilepsy in X-linked creatine transporter defect (CRTR-D). *Epilepsia*. 2007 Jun;48(6):1211-3.

Source of support: Nil

Conflict of interest: None declared

This work is licensed under CC BY: *Creative Commons Attribution 3.0 License*.