

## Original Article

### A Histopathological Evaluation of Lesions of Small Bowel

Sanjay Agrawal

Assistant professor, Department of Pathology, Hind Institute of Medical Science Safedabad, Barabanki , U.P., India

#### **ABSTRACT:**

**Background:** Infections, inflammatory diseases, and tumours affect the small intestine accounting for a majority of diseases. The present study was conducted to histopathological assess lesions of small intestine. **Materials & Methods:** The present study was conducted on 148 intestinal specimens of both genders. The specimens were preserved in 10% formalin and fixed for 24 hours, processed for paraffin sectioning. All specimens were stained by routine hematoxylin and eosin stains. **Results:** Non- neoplastic lesions were 102 and neoplastic were 46. Among non- specific lesions, there were 6 cases of tuberculosis, non specific enteritis in 3, duodenal ulcer in 7, hamartoma in 3, ischemic bowel disease in 46 and crohn's disease in 37. Neoplastic lesions were adenoma in 14, lipoma in 12, adenocarcinoma in 6, myeloid sarcoma in 5, poorly differentiated carcinoma in 6 and lymphoproliferative disorder in 5 cases. **Conclusion:** Diseases of small intestine demands early identification and prompt treatment. Among all, IBD and crohn's disease was commonly seen.

**Key words:** Crohn's disease, Histopathology, Small intestine

**Corresponding author:** Dr. Sanjay Agrawal, Assistant professor, Department of Pathology, Hind Institute of Medical Science Safedabad, Barabanki , U.P., India

**This article may be cited as:** Agrawal S. A Histopathological Evaluation of Lesions of Small Bowel. J Adv Med Dent Scie Res 2013;1(1):107-109.

#### **INTRODUCTION**

The small intestine, which plays a role in the absorption of nutrients that are essential to maintain life, is an important immune organ that serves as a barrier against foreign antigens, and its functions are while intricately interrelated with the autonomic nerves and endocrine system.<sup>1</sup>

Infections, inflammatory diseases, and tumours affect the small intestine accounting for a majority of diseases. Inflammation of the small bowel is relatively common viz., specific infections-viral or bacterial and non-specific inflammation caused by chronic infection, inflammatory bowel diseases and the drugs. Earlier, only severe acute and chronic pathological conditions were brought to the attention through literature.<sup>2</sup>

Inflammatory bowel diseases are a group of inflammatory conditions in which the body's own immune system attacks parts of the digestive system. The two most common inflammatory bowel diseases are Crohn's disease (CD) and ulcerative colitis (UC). Most common lesions includes inflammatory bowel disease of the small intestine is Crohn's disease and the number of patients with the disease has been increasing yearly. Neoplastic diseases in the small intestine are not very common. In general, non-epithelial tumors are more common than epithelial tumors.<sup>3</sup>

About two-thirds of the small bowel tumours are malignant, with most being adenocarcinoma; other types of tumours are carcinoids, lymphomas and sarcomas. Most tumours originate in duodenum (55.2%), followed by jejunum (17.6%) and the ileum.<sup>4</sup> The present study was conducted to histopathological assess lesions of small intestine.

#### **MATERIALS & METHODS**

The present study was conducted in the department of general pathology. It comprised of 148 intestinal specimens of both genders. The duration of the study was 1 years. The study protocol was approved by the institutional ethical committee.

General information such as name, age, gender etc. findings was recorded. The specimens were preserved in 10% formalin and fixed for 24 hours, processed for paraffin sectioning. All specimens were stained by routine hematoxylin and eosin stains. Immunohistochemistry was done wherever required. Special stain like Zeil-Neilson was also used to confirm the histopathological diagnosis. Results were subjected to statistical analysis. P value less than 0.05 was considered significant.

**RESULTS**

**Table I Distribution of cases**

Total- 148		
Gender	Males	Females
Number	72	76

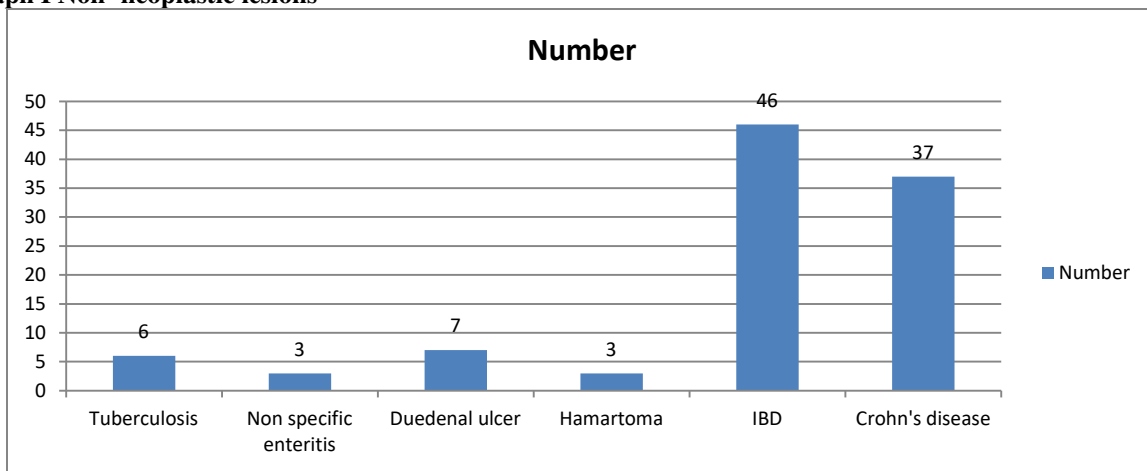
Table I shows that out of 148 specimens, 72 were of males and 76 of females.

**Table II Type of lesions**

Type	Number	P value
Non- neoplastic	102	0.01
Neoplastic	46	

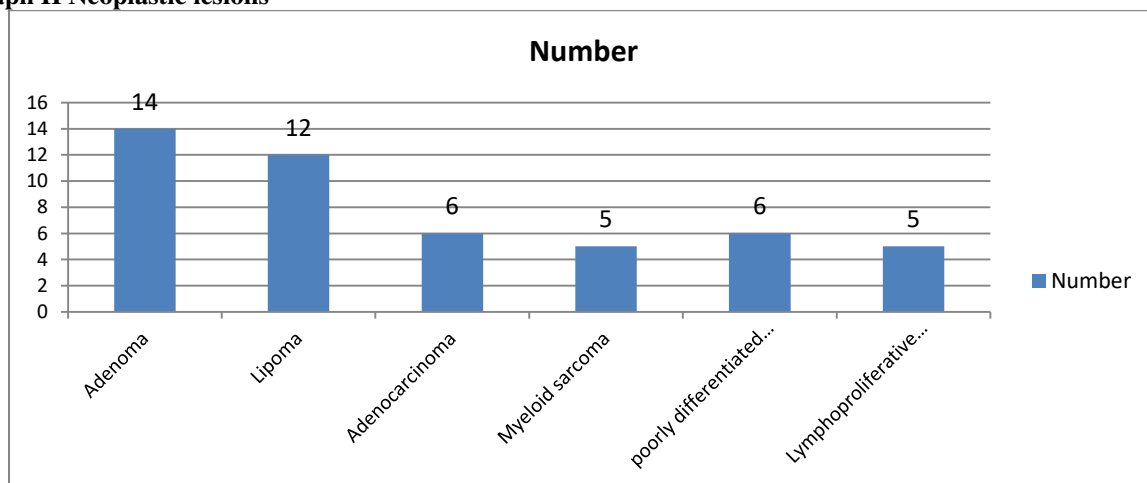
Table II shows that non- neoplastic lesions were 102 and neoplastic were 46. The difference was significant (P< 0.05).

**Graph I Non- neoplastic lesions**



Graph I shows that among non- specific lesions, there were 6 cases of tuberculosis, non specific enteritis in 3, duodenal ulcer in 7, hamartoma in 3, ischemic bowel disease in 46 and crohn’s disease in 37. The difference was significant (P< 0.05).

**Graph II Neoplastic lesions**



Graph II shows that neoplastic lesions were adenoma in 14, lipoma in 12, adenocarcinoma in 6, myeloid sarcoma in 5, poorly differentiated carcinoma in 6 and lymphoproliferative disorder in 5 cases. The difference was significant (P< 0.05).

## DISCUSSION

Diseases of small intestine require thorough evaluation in order to prevent further life threatening complications. Among various diseases, CD and UC cause chronic inflammation of the GI tract. CD can affect any part of the GI tract, but frequently affects the end of the small intestine and the beginning of the large intestine.<sup>5</sup> The inflammation in CD can affect all layers of the intestinal lining. Ulcerative colitis (UC) is characterized by inflammation in the large intestine (colon) and the rectum. The inflammation in UC occurs only in the innermost layer of the intestinal lining. The present study was conducted to assess diseases of small intestine histopathologically.<sup>6</sup>

We found that out of 148 specimens, 72 were of males and 76 of females. Among lesions, non- neoplastic lesions were 102 and neoplastic were 46.

Dutta et al<sup>7</sup> found that a total 124 cases of small intestinal lesions including the periampullary lesions were studied. Of these, 71 cases (57.25%) were non-neoplastic and 53 cases (42.75%) were neoplastic. Common age group was 5th-6th decade. A male preponderance was observed. Most common non-neoplastic lesions were non-specific enteritis (52.11%) and enteric fever (40%). Amongst neoplastic lesions, total 45 (84.91%) cases were malignant comprising adenocarcinomas of the periampullary region (49.06%) and carcinoid tumours (11.32%). Benign lesions were adenomas. Rare cases like myeloid sarcoma, metastatic adenocarcinoma and metastatic malignant melanoma were observed.

We observed that among non- specific lesions, there were 6 cases of tuberculosis, non specific enteritis in 3, duodenal ulcer in 7, hamartoma in 3, ischemic bowel disease in 46 and crohn's disease in 37. Neoplastic lesions were adenoma in 14, lipoma in 12, adenocarcinoma in 6, myeloid sarcoma in 5, poorly differentiated carcinoma in 6 and lymphoproliferative disorder in 5 cases.

Navaneethan et al<sup>8</sup> found that thirty-four percent patients were aged between 21 - 30 years and 22% patients aged between 41 - 50 years. There were 84% (n=42) males. Thirteen (26%) cases showed focal villous atrophy, 32 (64%) cases showed partial villous atrophy and 5 (10%) cases showed complete villous atrophy. Anti-tissue transglutaminase antibody was positive in 21 (42%) cases. CD3 immunomarker was positive for intraepithelial lymphocytes in all 50 cases while CD20 immunomarker showed focal positivity in areas with lymphoid follicle formation.

Lens et al<sup>9</sup> described the granulomas which are Small (<200 micrometer), discrete, very few / single, poorly organized, commonly located in the mucosa along with crypt centric inflammation and with aggregates of histiocytes. Microgranulomas helped in diagnosing Crohn's disease.

Zachariah<sup>10</sup> reported that 2 patients were of IBD in 6th and 8th decade similar to the findings observed by many authors. Five cases of our study were due to non occlusive cause. Male to female ratio was 4:1. Abdominal pain was the constant feature and all the patients belonged to 4-5th decade. Microscopically, gangrene and perforations were observed with ulcerations, hemorrhage and necrosis.

## CONCLUSION

Diseases of small intestine demands early identification and prompt treatment. Among all, IBD and crohn's disease was commonly seen.

## REFERENCES

1. Pan SY, Morrison H. Epidemiology of cancer of the small intestine. *World J Gastrointest Oncol.* 2011; 3(3):33-42.
2. Howe JR, Karnell LH, Scott-Conner C. The American College [8]of Surgeons Commission on Cancer and the American Cancer Society. Adenocarcinoma of the small bowel: review of the National Cancer Data Base, 1985-1995. *Cancer.* 1999; 86(12):2693-706.
3. Haselkorn T, Whittemore AS, Lilienfeld DE. Incidence of small bowel cancer in the United States and worldwide: geographic, temporal and racial difference. *Cancer Causes Control.* 2005; 16(7):781-87.
4. Agarwal N, Saha S, Srivastava A, Chumber S, Dhar A, Garg S. Peritonitis: 10 years' experience in a single surgical unit. *Trop Gastroenterol.* 2007; 28(3):117-20.
5. Iqbal T, Khan A, Iqbal A, Tahir F. Obstruction due to intestinal tuberculosis strictureplasty versus resection anastomosis. *Pak J Surg.* 2008;24(3):177-78.
6. Pulimood A, Ramakrishna B, Kurian G, Peter S, Patra S, Mathan V, et al. Endoscopic mucosal biopsies are useful in distinguishing granulomatous colitis due to Crohn's disease from tuberculosis. *Gut.* 1999;45(4):537-41.
7. Dutta AK, Sahu MK, Gangadharan SK, Chacko A. Distinguishing Crohn's disease from intestinal tuberculosis – a prospective study. *Trop Gastroenterol.* 2011; 32(3):204-09.
8. Navaneethan U, Cherian JV, Prabhu R, Venkataraman J. Distinguishing tuberculosis and crohn's disease in developing countries: how certain can you be of the diagnosis? *Saudi J Gastroenterol.* 2009;15(2):142-44.
9. Lens M, Bataille V, Krivokapic Z. Melanoma of the small intestine. *Lancet Oncol.* 2009;10(5):516-21.
10. Zachariah SK. Adult necrotizing enterocolitis and non occlusive mesenteric ischemia. *Journal of Emergencies, Trauma and Shock.* 2011;4(3):430-32.