

CASE REPORT

Conservative Management of Ameloblastic Fibroma: A Case Report with Review of Literature

Amit Bali¹, Pareedhi²

¹Professor, ²Post Graduate Student, Dept. of Oral and Maxillofacial Surgery, M.M. College of Dental Sciences and Research, M.M. University, Mullana, Ambala, Haryana, India

ABSTRACT:

This report presents a case of a rare tumour, ameloblastic fibroma, in 25 years old female patient. Treatment was carried out conservatively with surgical enucleation and peripheral osteotomy of the mandible while preserving the inferior alveolar nerve. This approach was found to be highly successful and there were no indicators of recurrence of disease even after 8 months of follow up. We therefore recommend this line of treatment in place of other, more aggressive approaches.

Key words: Ameloblastic Fibroma, Conservative Treatment, Excision, Peripheral Osteotomy.

Received: 3 January 2018

Revised: 16 May 2018

Accepted: 25 May 2018

Corresponding author: Dr. Pareedhi, Post Graduate Student, Dept. of Oral and Maxillofacial Surgery, M.M. College of Dental Sciences and Research, M.M. University, Mullana, Ambala, Haryana, India

This article may be cited as: Bali A, Pareedhi. Conservative Management of Ameloblastic Fibroma: A Case Report with Review of Literature. J Adv Med Dent Sci Res 2018;6(8):34-36.

INTRODUCTION

Ameloblastic fibroma (AF) can be considered a true mixed tumour of odontogenic origin. It is a relatively rare tumour that shows concurrent proliferation of both ectomesenchymal and epithelial tissue without formation of any discernible odontogenic tissue such as enamel or dentine. It arises most commonly in the posterior molar region of the mandible. It presents itself in young adults with no significant gender predilection. This case report describes the rare tumour AF of the mandible in a 25-year-old woman.

CASE REPORT:

A 25 years old female patient reported to the Department of Oral and Maxillofacial Surgery in August 2017 with a chief complaint of swelling in the right front region of the mandible since 25 days. History dated back to 1 month when patient first felt numbness over the right side of the lower lip. After 5 days, patient noticed a swelling in the same region which was gradually increasing in size. No history of associated pain, pus discharge or any other change was reported. After 10 days of the swelling, patient visited a local dentist who prescribed antibiotics for the same, but there was no improvement. Then the patient was referred to our institute for further treatment.

The general physical health and oral hygiene of the patient was good and there was no sign of any deleterious habits. Extraorally, a diffuse swelling was seen on the right lower 1/3rd of face in the parasymphiseal region extending about 2 cm from the midline of the chin posteriorly upto 1 cm anterior to angle of mandible and superiorly from angle of mouth to inferior border of mandible. Color of skin over the swelling was same as that of surrounding areas with no sign of secondary changes. Swelling was soft to firm in consistency, tender, non-compressible, non-reducible, non-pulsatile and immobile with no change in temperature. Paresthesia was present on the right side of lower lip and chin.

Intraorally, the swelling extended from 43 to 46 region, obliterating the buccal vestibule. No evidence of ulceration or pus discharge was present. On palpation, buccal cortical plate expansion could be elicited.

Computed tomographic scan of the region revealed a unilocular, well-defined, oval shaped radiolucency in the right parasymphiseal region extending antero-posteriorly from the periapical region distal to 41 to the periapical area involving the distal root of 46 and superiorly from apical region of teeth to the inferior border of the mandible. It also revealed resorption of roots with respect to 43, 44 and 45 [Figure 1].

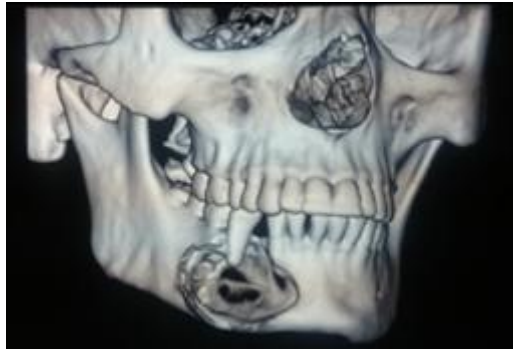

Figure 1: 3D reconstruction of CT scan showing extent of lesion and perforation of buccal cortex

Mandibular occlusal view revealed marked expansion of buccal cortical plate with continuity and thinning of border and slight expansion of lingual cortical plate with presence of thin septa.

Aspiration was negative.

Provisional diagnosis of ameloblastoma with differential diagnosis of keratocystic odontogenic tumor was established.

Conservative surgical excision with thorough bony curettage and extraction of the involved teeth was planned.

After a right mandibular parasymphiseal vestibular incision, the tumor was exposed and found to be encased in bone. The involved teeth i.e. 44, 45 and 46 were extracted. The tumor was excised and peripheral osteotomy of surrounding bone done. Every effort was made to maintain the integrity of the inferior alveolar nerve [Figure 2]. Post operatively, the wound was packed with ribbon gauze and sutured. The pack was removed after 48 hours and the suturing completed. The wound was allowed to heal without intervention afterwards.

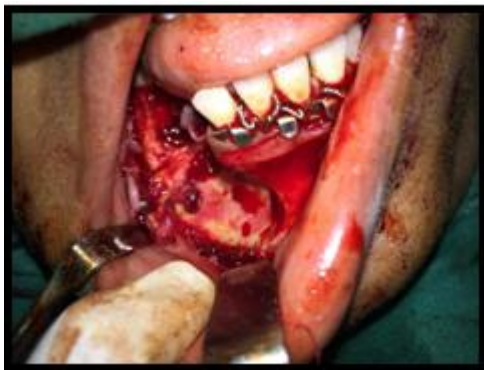

Figure 2: Intra-operative photograph showing bony cavity after enucleation and peripheral osteotomy

The excised mass, which was approximately 4 cm × 2 cm in size, soft in consistency and creamy white in color, was sent for histopathological analysis [Figure 3].

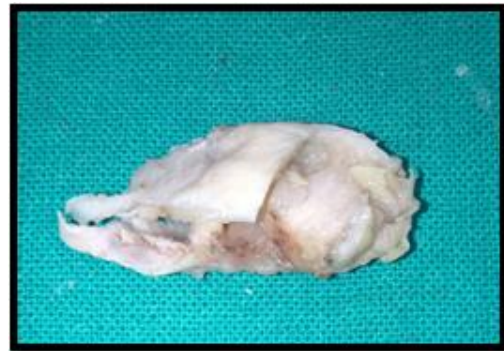


Figure 3: Excised specimen

The microscopic appearance of the neoplasm was characteristic [Figure 4]. The ectodermal component consisted of islands of epithelial cells in follicles, long finger-like strands, nests and cords pattern. The mesenchymal component was hypercellular and showed numerous blood vessels. There was opening up of the ameloblastic follicles, leading to stellate reticulum like appearance of the core tissue which is characteristic for ameloblastic fibroma.

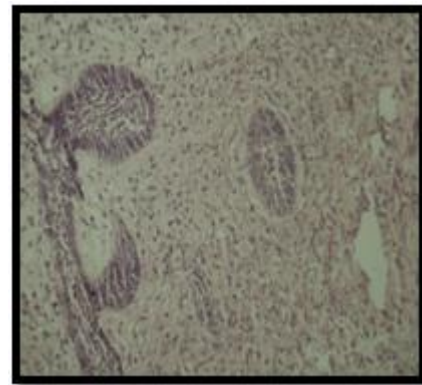


Figure 4: Microscopic appearance of specimen at 20X stained with H & E stain

The patient was kept on regular follow-up and no significant signs of recurrence were seen even after 8 months. The paresthesia of the right lower lip and chin persisted but did not worsen with time. There was uneventful soft tissue and bone healing. [Figure 5 and 6]

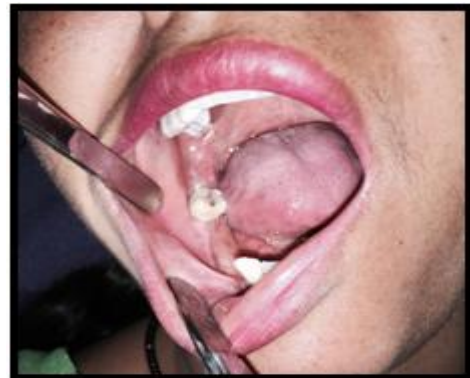

Figure 5: Post-operative Photograph after 8 months of enucleation

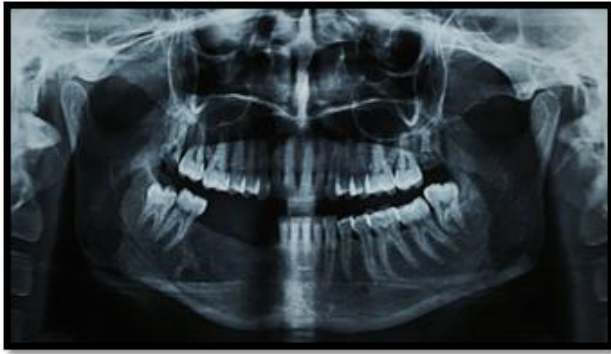

Figure 6: Post-operative OPG after 8 months of enucleation

DISCUSSION:

Ameloblastic fibroma is a mixed benign tumor of odontogenic origin. It is an uncommon tumor and comprises of approximately 2% of all odontogenic tumors. It occurs in the canine- molar region of mandible predominantly, however some cases in the maxilla have been reported [1, 2].

It has been reported as occurring at ages ranging from 6 months to 42 years, with an average from 14.6 to 15.5 years[2].Chen et al also reported that maximum number of patients (72.4 %) were under the age of 20 years [3]. Our patient was well above the average age of presentation.

It is imperative to distinguish AF from ameloblastoma and ameloblastic fibrosarcoma (AFS) [4].Both these tumors are locally invasive and have a larger potential for recurrence than AF. Clinically, AF occurs in younger patients as compared to ameloblastoma. Radiographic examination does not assist in differential diagnosis because all the three tumors may appear as uni- or multilocular, or circumscribed lesions. Biopsy and histologic examination, however, always establish the diagnosis.

The general consensus for the treatment of ameloblastic fibroma is conservative in nature, however debate still rages on regarding the recurrence of this disease.

Chen et al reported its overall recurrence rate of 33.3 % in patients treated with conservative (91.5 %) and radical methods (8.5 %)[3]. Investigators such as Trodahl and Zallen et al also suggest that conservative treatment was inadequate and concurrently reported recurrence rates of 44 % and 18.3 %, respectively [5, 6].

Nonetheless, Thoma and Goldman have recommended a conservative approach as early as 1946 [7]. This is unfalteringly supported till date by Dallera et al, Kim et al and Isobe et al, all of whom used the same line of treatment in their respective cases and reported no recurrences [1, 4, and 8].

It is rather challenging to explain this conflicting data. Some authors such as Zallen et al are of the view that recurrence can be attributed to incomplete intra-lesional debulking of the tumor during primary enucleation and/or the presence of satellite lesions [6].

Philipsen et al advocate that the innocuous behavior of the tumor doesn't validate aggressive initial treatment. Thorough surgical enucleation with extensive curettage of bony walls and regular clinical follow-up should suffice as primary treatment. They suggest that reappearance of the tumor is actually the regrowth of residual tumor rather than true recurrence. Such recurrences should be dealt with aggressive action [9].

More aggressive treatment modalities such as the resection of the wide regions of mandible specially in growing young patients is associated with numbers of complications such as forfeiture of bone support, deformity, dysfunction and psychological suffering even after reconstruction [8].

In this case report, we support a conservative approach towards this tumor as we have achieved above average results in terms of soft tissue and bony healing. We recommend this line of treatment with regular meticulous follow up examinations and radiographs.

REFERENCES:

1. Kim SG, Jang HS. Ameloblastic Fibroma: Report of a Case. *J Oral Maxillofac Surg* 2002; 60: 216-218.
2. Regezi JA, Kerr DA, Courtney RM. Odontogenic tumors: analysis of 706 cases. *J Oral Surg* 1978; 36: 771-8.
3. Chen Y, Wang JM, Li TJ. Ameloblastic Fibroma: A review of published studies with special reference to its nature and biological behaviour. *Oral Oncol* 2007; 43: 960-969.
4. Dallera P, Bertoni E, Marchetti C, Bacchini P, Campobassi A: Ameloblastic fibroma: a follow-up of six cases. *Int. J. Oral Maxillofac. Surg*, 1996; 25: 199-202.
5. Trodahl JN. Ameloblastic fibroma. A survey of cases from the Armed Forces Institute of Pathology. *Oral Surg Oral Med Oral Pathol* 1972; 33: 547-558.
6. Zallen RD, Preskar MH, McClary SA. Ameloblastic fibroma. *J Oral Maxillofac Surg* 1982; 40: 513-517.
7. Thoma KH, Goldman HM. Odontogenic tumors: A classification based on observations of the epithelial, mesenchymal, and mixed varieties. *Am J Pathol* 1946; 22: 433-471.
8. Isobe K, Morita K, Omura K. Enucleation and repeated dredging treatment for a large ameloblastic fibroma in growing young patient: Report of a case with difficult treatment planning. *Asian J Oral Maxillofac Surg* 2011; 23: 96-98.
9. Philipsen HP, Reichart PA, Praetorius F. Mixed odontogenic tumors and odontomas. Considerations on interrelationship. Review of the literature and presentation of 134 new cases of odontomas. *Oral Oncol*. 1997; 33: 86-99.

Source of support: Nil

Conflict of interest: None declared

This work is licensed under CC BY: **Creative Commons Attribution 3.0 License.**