

Case Report

Mandibular repositioning in a hemimandibulectomy patient using guide flange prosthesis: A Case Report

Anand V. Pradhan, S.P. Dange, Smita Vaidya

Dept of Prosthodontics, Govt. Dental College & Hospital, Aurangabad, Maharashtra University of Health Sciences, Maharashtra, India.

Corresponding Author:

Dr. Anand V. Pradhan,
Room No.231,
Post-graduate section,
Dept of Prosthodontics,
Govt. Dental College & Hospital,
Aurangabad-431001, Maharashtra,
India.
Email: Pradhananand87@gmail.com

Received: 25-04-2013

Revised: 18-05-2014

Accepted: 19-05-2014

Abstract

Loss of mandibular continuity following mandibular resection is a debilitating condition for patients. Mandibular deviation towards the defect side is a common sequela in such cases. Mandibular deviation results in impaired masticator function, poor control of salivary secretions and facial disfigurement. A mandibular guidance prosthesis helps the patient achieve normal maxilla-mandibular relationship and facilitates early progression to a nearly perfect permanent restoration. This case report describes simple mandibular guide flange prosthesis for a patient with a hemimandibulectomy defect with loss of continuity.

Key words- Discontinuity Defect, Mandibular Deviation, Guide Flange Prosthesis

This article may be cited as: Pradhan AV, Dange SP, Vaidya SA. Mandibular repositioning in a hemimandibulectomy patient using guide flange prosthesis: A Case Report. J Adv Med Dent Scie 2014;2(2):161-165.

Introduction

Odontogenic tumors of epithelial origin commonly seen in posterior mandible are often treated with surgical excision. Neoplastic lesions of the oral cavity requires resection involving mandible, floor of the mouth, tongue and also palate as per oral surgical assessment.¹ The prosthodontic rehabilitation of patients with acquired mandibular defect is a challenging task for a dentist. With continued improvement in surgical resection and reconstruction techniques, the prognosis of these patients has greatly improved. Prosthodontic management of patients with mandibulectomy defects can enhance appearance, function and speech.²

If mandibular continuity is not restored during surgical closure of wound, the remaining mandibular segment will retrude and deviate toward the surgical side at the vertical dimension of rest. When mouth is opened, the deviation increases, leading to an angular pathway of opening and closing.³ During mastication, the entire envelope of motion occurs on the surgical defect side.⁴ This mandibular deviation is mainly due to uncompensated influence of contralateral musculature particularly the internal pterygoid muscle and pull from the contraction of cicatricial tissue on resected side.^{5,6} The degree of deviation is dependent upon several factors which

include the location and extent of osseous and soft tissue resection, the method of surgical site closure, degree of impaired tongue function, the presence and condition of the remaining natural teeth, the degree to which innervations has been involved, the use of adjunctive procedures like radiation therapy and the timing of prosthodontic treatment.^{2,7} Several modalities to return the mandible to optimum maxilla-mandibular relationship have been described. These include intermaxillary fixation¹, vacuum formed PVC splints⁸, mandibular guidance prostheses³ and a widened maxillary occlusal table using a double row of teeth.⁹ A mandibular guidance prosthesis can be defined as a maxillofacial prosthesis used to maintain a functional position for the jaws (maxillae and mandible), improve speech and deglutition following trauma or/and surgery to the mandible or/and adjacent structures.¹⁰ The main objective of using a guidance prosthesis is to re-educate the mandibular muscles to re-establish an acceptable occlusal relationship (physiotherapeutic function) for residual hemimandible.¹¹

Case report

A 40 year old male patient was referred to the Department of Prosthodontics (Government Dental College and Hospital, Aurangabad, Maharashtra) for rehabilitation after a hemimandibulectomy defect (Figure 1). Patient history revealed that mandibular resection was carried out from the left condyle to the left parasymphysial following a diagnosis of follicular ameloblastoma with the left side of mandible. No reconstructive procedures were carried out during the surgery. Intraoral examination revealed thick buccal mucosa with scar formation and obliteration of alveolar ridge, buccal and lingual sulci in the region of defect. Mouth opening was found to be reduced to 25mm and mandibular deviation of 18-20 mm

towards left side was found on opening of jaw (Figure 2).



Figure 1: Extra-oral view

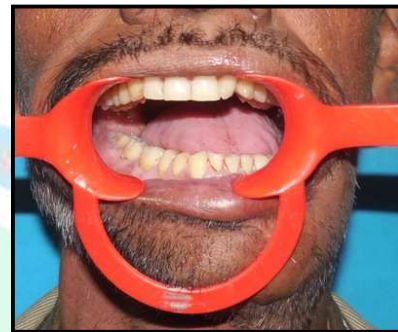

Figure 2: Intra-oral view

The patient was able to achieve an appropriate mediolateral position of the mandible but was unable to repeat this position consistently for adequate mastication. A decision was made to fabricate a mandibular guide flange prosthesis with orthodontic wire clasps and substructure and an acrylic resin guide flange. The impressions of maxillary and mandibular arches were obtained (Figure 3)

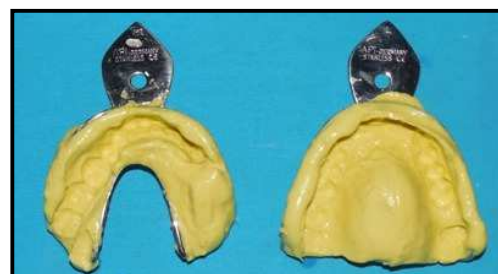


Figure 3: Impressions in irreversible hydrocolloid

using perforated rim-lock stainless steel impression trays with irreversible hydrocolloid impression material (Tropicalgin, Zermack, Rovigo, Italy). The casts were poured in type IV dental stone (Kalrock, Kalabhai Karson, Mumbai, India) (Figure 4). The casts were sealed in maximum intercuspation using sticky wax and were mounted on a mean value articulator with type II dental plaster.

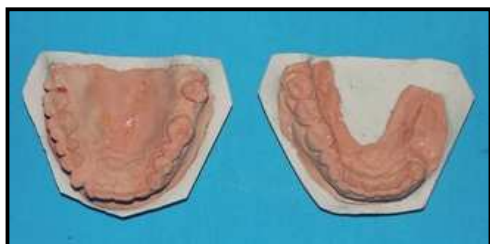

Figure 4: Casts poured in type IV dental stone

A 21 gauge stainless steel orthodontic wire was manipulated to obtain the framework of the guide flange prosthesis in mandibular arch. The framework consisted of a rectangular wire projection for the guide flange having width equal to the combined width of the opposing two maxillary premolars. The retentive arms of the framework passed to the lingual side mesial to mandibular first premolar and distal to mandibular first molar (Figure 5). The guide flange prosthesis was fabricated around the framework using clear autopolymerizing acrylic resin (DPI cold cure clear, Dental Products of India, Mumbai, India). A maxillary retentive plate

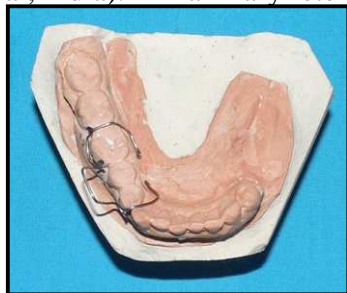


Figure 5: The wire framework for mandibular prosthesis

was fabricated with Adam's clasps on left and right maxillary first molars (Figure 6) to stabilize the maxillary teeth against the pressure exerted by the mandibular guide flange.

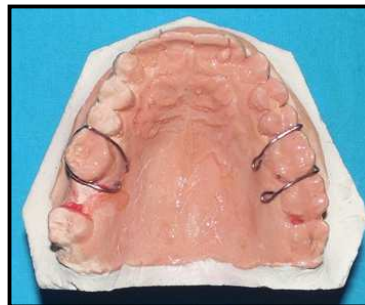


Figure 6: Clasps for maxillary prosthesis

Both the maxillary and mandibular prostheses were finished and polished (Figure 7). The guide flange prosthesis was tried in the patient's mouth for stabilization and retention. The projection of the prosthesis touching the opposing maxillary posterior teeth was slightly relieved so as not to encroach upon the teeth. A smooth gliding path from open-mouth position (Figure 8) to maximum intercuspation was ensured (Figure 9).

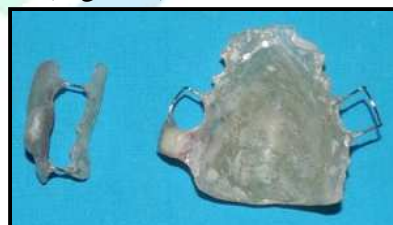

Figure 7: The final prostheses

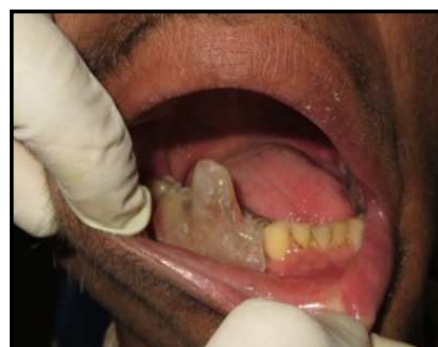

Figure 8: Prosthesis in open mouth position

Patient was instructed regarding the care and cleanliness of the prosthesis, and the exercise regime to follow concurrently, with the use of the prosthesis.

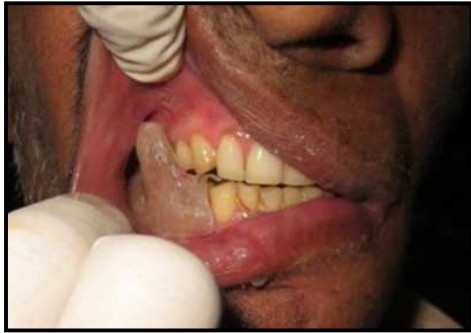

Figure 9: Prosthesis providing guidance for mandibular closure

Discussion

Following a segmental mandibular resection resulting in a discontinuity defect, masticatory function is compromised because of muscular imbalance that results from unilateral muscle removal, altered maxilla-mandibular relationship and decreased tooth to tooth contacts. Although immediate mandibular reconstruction aims to restore facial symmetry, arch alignment and stable occlusion, masticatory function often remains compromised.¹² During the initial healing period, early prosthodontic intervention by mandibular guide flange and maxillary stabilization prosthesis serve the purpose of reducing the mandibular deviation, preventing extrusion of the maxillary teeth and improving masticatory efficiency. Any delays in the initiation of mandibular guidance appliance therapy, due to problems such as extensive tissue loss, radiation therapy, radical neck dissection, flap necrosis and other post-surgical morbidities may result in an inability to achieve normal maxilla-mandibular relationship.¹³

Maxillo-mandibular fixation, as suggested by Aramany and Myers¹, was used extensively to prevent mandibular deviation. However, according to Beumer

et al³ it is feasible only in patients with resections confined to the mandible and with little associated soft tissue loss. The mandibular guidance prosthesis is, therefore, favored to achieve desired maxillo-mandibular relationship. The guide flange can be fabricated in cast metal or acrylic resin. If the mandible can be manipulated into an acceptable maxilla-mandibular relationship but the patient lacks the motor control to bring the mandible into occlusion, a cast mandibular resection restoration as suggested by Robinson and Rubright is appropriate.^{3,6} If some resistance is encountered in positioning of the mandible, then a guidance ramp of acrylic resin is suggested.³ The cast metal flange, however, is not as cost effective as an acrylic flange and the fabrication and corrections when required are difficult. The acrylic resin guide flange was the treatment chosen in the present case due to economic constraints of the patient and the ease of fabrication and modification provided by the acrylic resin. The prosthesis was fabricated in clear autopolymerizing acrylic resin and the retentive clasp arms in both maxillary and mandibular prosthesis were kept as posterior as possible to be unobtrusive and esthetic. A well organized mandibular exercise program should support any mandibular guidance therapy. McCasland suggested that patients use straight opening and closing exercise to train the neuromuscular system to avoid deviation of the mandible.¹⁴ The exercise as suggested by Beumer et al³ was suggested to the patient. In this procedure, following maximum opening, the patient manipulates the mandible by grasping the chin and moving the mandible away from the surgical side. These movements tend to loosen scar contracture, reduce trismus and improve maxilla-mandibular relationships.

Conclusion

The physical and psychological trauma associated with the surgical resection of mandible following neoplastic diseases is often compounded by the loss of proper function of the masticator apparatus. Early prosthodontic intervention is a necessary approach towards restoring the maxillo-mandibular relationship. A mandibular guide flange prosthesis is an important adjunct for achieving this goal. A well-fabricated prosthesis and an appropriate mandibular exercise regimen can go a long way in restoring the patient's physiological and psychological well being.

References

1. Aramany MA, Myers EN. Intermaxillary fixation following mandibular resection. *J Prosthet Dent* 1977; 37:437-444.
2. Schneider R, Taylor TD. Mandibular resection guidance prostheses: A literature review. *J Prosthet Dent* 1986; 55:84-86.
3. Beumer III J, Marunick MT, Esposito SJ. Maxillofacial rehabilitation. 3rd ed., 2011, Quintessence. Page 87-89, 118-120.
4. Curtis TA, Taylor RC, Rositano SA. Physical problems in obtaining records of the maxillofacial patients. *J Prosthet Dent* 1975; 34:539-554.
5. Moore DJ, Mitchell DL. Rehabilitating dentulous hemimandibulectomy patients. *J Prosthet Dent* 1976; 35:202-206.
6. Robinson JE, Rubright WC. Use of a guide plane for maintaining the residual fragment in partial or hemimandibulectomy. *J Prosthet Dent* 1964; 14:992-999.
7. Martin JW, Shupe RJ, Jacob RF, King GE. Mandibular positioning prosthesis for the partially resected mandibulectomy patient. *J Prosthet Dent* 1985; 53:678-680.
8. Monaghan AM, Bear AS. A simple appliance to correct mandibular deviation following hemimandibulectomy. *British J Oral Maxillofac Surg* 1990; 28:419-420.
9. Prakash V. Prosthetic rehabilitation of edentulous mandibulectomy patient: A clinical report. *Indian J Dent Res* 2008; 19:257-260.
10. Glossary of prosthodontic terms ed.8. *J Prosthet Dent* 2005; 94:50.
11. Desjardins RP. Occlusal considerations for the partial mandibulectomy patient. *J Prosthet Dent* 1979; 41:308-315.
12. Olson ML, Shedd DP. Disability and rehabilitation in head and neck cancer patients after treatment. *Head Neck Surg* 1978; 1:52-58.
13. Ufuk H, Sadullah U, Ahyan G. Mandibular guidance prosthesis following resection procedures: Three case reports. *Eur J Prosthodont Restor Dent* 1992; 1:69-72.
14. Keys SM, McCasland JP. Techniques and results of a comprehensive dental care program in head and neck cancer patients. *Int J Radiat Oncol Biol Phys* 1976; 1:859-865.

Source of support: Nil

Conflict of interest: None declared