

## Case Report

### Autologous Tooth Transplantation: Report of 5 cases

Geeta Singh, Shadab Mohammad, Somdipto Das, Nitin Mahajan, Department of Oral and Maxillofacial Surgery, King George's Medical University, Lucknow-226003, Uttar Pradesh.

#### Corresponding Author

Dr. Somdipto Das  
Senior Resident  
Department of Oral and  
Maxillofacial Surgery,  
King George's Medical  
University, Lucknow-226003,  
Uttar Pradesh  
E-mail: somdipto4u@gmail.com

Received: 23-11-2013

Revised: 04-01-2014

Accepted: 07-01-2014

#### Abstract:

The present article is clinical study on autogenous tooth transplantation. Although the indications for autotransplantation are quite narrow, careful patient selection coupled with an appropriate surgical technique can lead to exceptional esthetic and functional results. This article highlights the indications for autogenous tooth transplantation using 5 case reports. The procedure for tooth transplantation is usually not more traumatic for the patient than the removal of impacted third molars. Depending on patient preference, local anesthesia alone or in conjunction with some form of sedation is sufficient for the surgical procedure. Success of autotransplantation is viewed in terms of survival, with or without root filling. This technique seems superior to allotransplantation because of less problem of histocompatibility. The literature reports excellent success rates following tooth transplantation when the appropriate protocol is followed. 95% to 98% long-term survival rates were found in the cases of autogeneous tooth transplant.

**Key Words:** Autotransplant, Histocompatibility, Endodontics.

This article may be cited as: Singh G, Mohammad S, Das S, Mahajan N. Autologous Tooth Transplantation: Report of 5 cases. J Adv Med Dent Scie 2014;2(1):140-145.

#### Introduction

Advances in the field of scientific knowledge and technology has lead to improvement and better result of autologous tooth transplantation, which is the surgical movement in one individual of a vital or endodontically treated tooth from its original location in the mouth to another site<sup>1</sup>. The earliest reports of tooth transplantation involve slaves in ancient Egypt who were forced to give their teeth to their pharaohs.<sup>2</sup> However, allotransplantation of a tooth from one individual to another was eventually abandoned because of problems of histocompatibility and replaced with auto transplantation. This technique seems superior to allotransplantation because of less

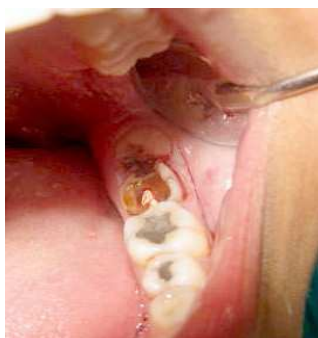problem of histocompatibility. Auto transplantation has previously been viewed with uncertainty because of lack of information on the topic and poor clinical results of reported cases. These poor results were due to a lack of understanding of the biological principles involved and poor clinical technique.<sup>3</sup> Another barrier to the acceptance of the technique has been the misconception that auto-transplantation can only be successful when immature, developing teeth are transplanted. Success of autotransplantation is viewed in terms of survival, with or without root filling. Autologous tooth transplantation was first well documented in 1954 by M.L. Hale.<sup>4</sup> The

major principles of his technique are still followed today. The science of autotransplantation has progressed, as evidenced by the high success rates reported in studies over the past decade.<sup>4,5</sup> The studies demonstrate that autotransplantation is a viable option for tooth replacement for carefully selected patients.

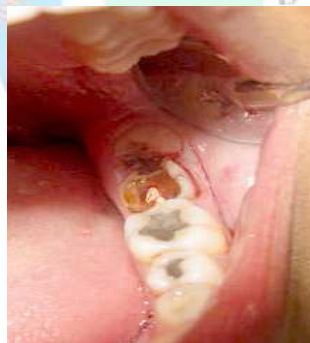**Case Report**

A 22 year old male patient reported to Department of Oral and Maxillofacial Surgery, King George’s Medical University with chief complaint of pain and decayed lower left molar teeth. On examination, he had grossly carious lower left second molar and impacted third molar. Preoperative orthopantomogram (OPG) was taken to assess the bone quality of recipient site and condition of donor tooth. The option of autotransplantation along with other options was explained to the patient. Using routine inferior mandibular nerve block anesthesia

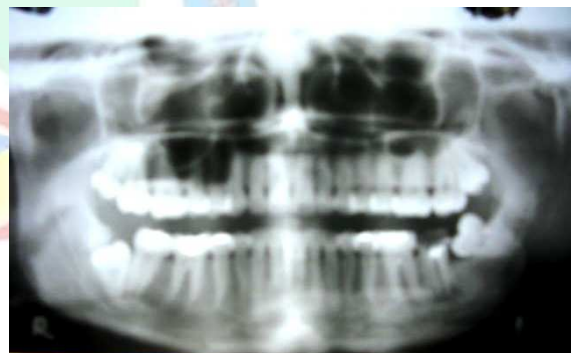and infiltration under aseptic technique, the left lower third molar and grossly carious lower second molar were extracted carefully to avoid root fracture (Figure 1-9). The lower left third molar was kept in normal saline (storage medium). RCT was completed with retro filling and sealing of root apex by MTA which has property of promoting healing and cementogenesis. The alveoli socket was widened using surgical bur and the stored lower left third molar was held in place by a composite splinting. Patient was asked to do warm saline gargles and was put under antibiotic coverage. On recall visit, the implanted tooth was examined for mobility, which was absent. The composite splint was removed after 2 weeks and post-operative orthopantomogram was taken to assess the condition of implanted tooth. Similarly a total of 5 cases were done under aseptic conditions and all of them were reviewed at regular intervals (Table-1).



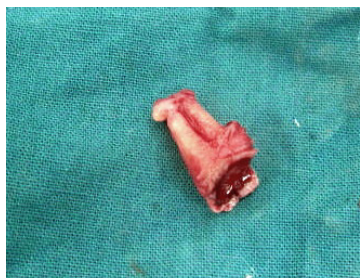
**Figure 1:** Grossly Carious Mandibular Second Molar and Impacted Third Molar



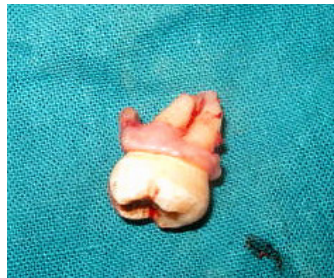
**Figure 2:** Surgical Incision



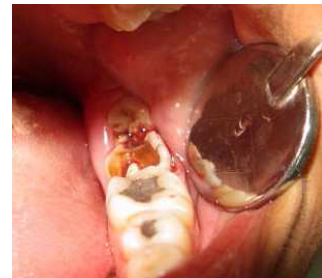**Figure 3:** O.P.G. Showing Impacted Mandibular Third Molar



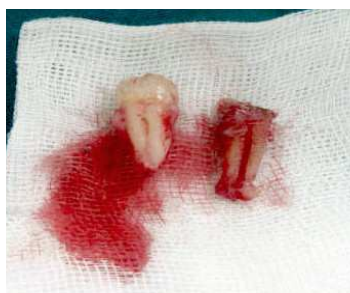**Figure 4:** Grossly Carious Mandibular Second Molar After Extraction



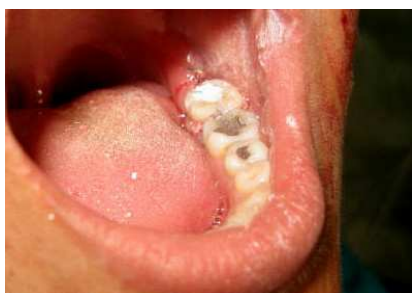**Figure 5:** Extracted Mandibular Third Molar



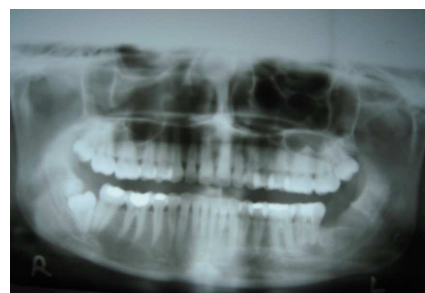**Figure 6:** Surgical Curettage of Periapical Lesion



**Figure 7:** Extracted Donor and Recipient Site Teeth



**Figure 8:** Post Operative View after Transplantation Of Mandibular Third Molar in Second Molar Socket



**Figure 9:** Post Operative O.P.G. After Autologous Tooth Transplantation

**Table 1:** Patient Particular of Selected Cases

S. No	Age/Sex	Recipient Site	Donor tooth	Result
1	22/M	Left lower first molar	Left lower third molar	Good
2	23/F	Right maxillary canine	Palately impacted ipsilateral canine	Good
3	28/M	Right lower Second molar	Right lower Third molar	Satisfactory
4	26/M	Right lower first molar	Right lower Third molar	Good
5	30/M	Left lower first molar	Right lower Third molar	Satisfactory

## Discussion

Although there are many reasons for autotransplanting teeth, tooth loss as a result of dental caries is the most common indication, especially when mandibular first molars are involved. First molars erupt early and often get carious. Autotransplantation in this situation involves the removal of a third molar which may then be transferred to the site of an unrestorable first or second molar. Other conditions in which transplantation can be considered include tooth agenesis (especially of premolars and lateral incisors), traumatic tooth loss, atopic eruption of canines, root resorption, large endodontic lesions, cervical root fractures, localized juvenile periodontitis as well as other pathologies.<sup>1,6,7</sup> Successful transplantation depends on specific requirements of the patient, the donor tooth, and the recipient site. Patient selection is very important for the success of autotransplantation. Candidates must be in good health, able to follow post-operative

instructions, and available for follow-up visits. They should also demonstrate an acceptable level of oral hygiene and be amenable to regular dental care. Most importantly, the patients must have a suitable recipient site and donor tooth. Patient cooperation and comprehension are extremely important to ensure predictable results. The recipient site must have adequate bone support. There must be sufficient alveolar bone support in all dimensions with adequate attached keratinized tissue to allow for stabilization of the transplanted tooth. In addition, the recipient site should be free from acute infection and chronic inflammation. Once sufficient anesthesia is obtained, the tooth at the recipient site is extracted and the recipient socket is prepared. Occlusal and periapical radiographs of the donor tooth should be used to determine its labiolingual and mesiodistal dimensions. Many practitioners use this information to

fabricate an acrylic replica of the tooth to be transplanted. This replica allows them to prepare the recipient site using a guide with dimensions similar to those required for the donor tooth. Next, the donor tooth is carefully removed to ensure minimal trauma to the periodontal ligament. When the donor tooth is unerupted, extraction involves flap elevation, bone removal, and gentle removal of the follicle from around the crown. Traumatic injury to the root surface of the donor tooth will impair the success of the transplant due to inadequate periodontal ligament regeneration. This is important for integration at the recipient site.<sup>1,8</sup> Once removed, the donor tooth should be handled as little as possible and the practitioner should be careful to touch only the crown. The tooth is then placed in the recipient socket. Minimal delay between extraction and transplantation is important to ensure maintenance of periodontal membrane vitality. If further adjustment of the recipient socket is required, the donor tooth can be easily stored in its original socket. Once the transplanted tooth is in its final position, occlusion is checked and, if needed, adjusted using a high-speed finishing bur. The tooth should be in slight infraocclusion to allow it to erupt into proper occlusion over the next few months. When proper positioning is obtained, the tooth can be stabilized with a suture splint for 1 to 2 weeks.<sup>9</sup> Alternatively, adhesive resin, light polymerizing resin, or a temporary bridge of autopolymerizing resin and wire splint can be used.<sup>5</sup> Post-operative instructions and sequelae are similar to those following the removal of an impacted tooth.<sup>2</sup> A soft diet should be followed for a couple of days after surgery and the patient should be instructed to avoid mastication on the transplanted site. Patients should be

instructed to maintain optimal oral hygiene. Some investigators feel that the patient should rinse with chlorhexidine gluconate mouth rinse.

Some authors think that for younger patients, autotransplantation may also be considered as a temporary measure. With appropriate patient selection, and presence of a suitable donor tooth and recipient site, autogenous transplantation should be considered as a viable option for treatment of an edentulous space.<sup>10</sup> Edetanlen et al shown that auto-transplant can be done in all ages. It concludes that autotransplant is a successful procedure if done under aseptic condition and it can be a normal routine procedure if required by patient.<sup>11</sup> More so, it is not equipment sensitive procedure. It only requires that the recipient cavity is wide enough not to disturb the periodontal tissues. It can also be done in a tooth with closed apex unlike where previous reports asserted that it is only successful in an open apex tooth<sup>11</sup>. For vital transplants of developing teeth with open apices, endodontic treatment of the transplant is not required as these teeth can be revascularized and reinnervated<sup>1</sup>. However, endodontic treatment is always required for transplants of mature teeth with complete root formation. Endodontic therapy begins approximately one month post-operatively with instrumenting of the canals and filling with calcium hydroxide. Gutta percha filling is completed 3 to 6 months post-transplantation.<sup>6</sup> The average extra oral time was 7.58 min (range: immediately after extraction up to 25 min). There was no relationship ( $P > .05$ ) between the extra oral time and either root resorption (4 cases, 2.4%) or ankylosis (18 cases, 10.7%) within the experimental time period. The poor results in the past were due to lack of understanding of the biological principles involved and poor clinical technique.<sup>3</sup> The

literature reports excellent success rates following tooth transplantation when the appropriate protocol is followed. Andreasen<sup>8</sup> found 95% and 98% long-term survival rates for incomplete and complete root formation of 370 transplanted premolars observed over 13 years. Lundberg and Isaksson<sup>12</sup> had success in 94% and 84% of cases for open and closed apices respectively in 278 autotransplanted teeth over 5 years. Kugelberg<sup>7</sup> achieved success rates of 96% and 82% for 45 immature and mature teeth transplanted into the upper incisor region over 4 years. Cohen<sup>2</sup> showed success in the range of 98-99% over 5 years and 80-87% over 10 years with transplanted anterior teeth with closed apices. Nethander<sup>8</sup> found 5-year success rates of over 90% for 68 mature teeth transplanted with a 2-stage technique. These consistently high success rates are a contrast to the variable results reported in many older studies. Schwartz and others<sup>13</sup> yielded success rates of only 76.2% at 5 years and 59.6% at 10 years. Similarly, Pogrel<sup>3</sup> found that his success rate for 416 autotransplanted teeth was 72%. However, other investigators of that era had more positive results. Kristerson,<sup>9</sup> for example, obtained a success rate of 93% when 100 autotransplanted premolars were observed for a mean of 6.3 years. The factors that lead to success have been extensively investigated. The most significant determinant for survival of the transplant is the continued vitality of the periodontal membrane. In cases where the periodontal ligament is traumatized during transplantation, external root resorption and ankylosis is often noted.<sup>2,3</sup> Schwartz<sup>13</sup> tried to link the loss of the graft to specific prognostic factors and found that success rates are highest when donor teeth are premolars, have one-half to two-thirds root development, and experience minimal trauma and limited extraoral time during

surgery. The experience of the surgeon also affects the success because this procedure is technique-sensitive<sup>11</sup>. Although retention of the tooth and restoration of the edentulous space is the desired outcome for patients, more specific parameters have been used to measure the health of the surviving transplant. These parameters include marginal periodontal attachment, mobility, pain, root resorption, root development, sensitivity to percussion, gingival pocket depth, presence of gingivitis, and presence of fistulae.<sup>6,8</sup> However, these studies are difficult to compare because each used different measures to determine success. Cameron et al<sup>10</sup> reported that with appropriate patient selection, and presence of a suitable donor tooth and recipient site, autogenous transplantation should be considered as a viable option for treatment of an edentulous space. Although the indications for autotransplantation are narrow, careful patient selection coupled with an appropriate technique can lead to exceptional esthetic and functional results. The most common cause of failure of the autotransplant is chronic root resorption.<sup>14</sup> More specifically, the causes of tooth loss following transplantation from most common to least common are inflammatory resorption, replacement resorption (ankylosis), marginal periodontitis, apical periodontitis, caries, and trauma.<sup>13</sup> Inflammatory resorption may become evident after 3 or 4 weeks, while replacement resorption may not become evident until 3 or 4 months after transplantation. The incidence of both types of resorption can be decreased with atraumatic extraction of the donor tooth and immediate transfer to the recipient site to minimize the risk of injury to the periodontal ligament.<sup>2</sup> The incidence of both types of resorption can be decreased with atraumatic extraction of the donor tooth and

immediate transfer to the recipient site to minimize the risk of injury to the periodontal ligament.

### Conclusion

Although autotransplantation has not been established as a traditional means of replacing a missing tooth, the procedure requires more consideration. Recent studies clearly demonstrate that autotransplantation of teeth is as successful as endosseous dental implant placement. Minimum acceptable success rates for endosseous titanium dental implants are 85% after 5 years and 80% after 10 years however the literature reports excellent success rates following tooth transplantation when the appropriate protocol is followed and success rate is found upto 95% and 98% long-term survival rates. For younger patients, autotransplantation may also be considered as a temporary measure. The transplant can replace missing teeth to ensure preservation of bone until growth has ceased and then, if necessary, the patient can become a candidate for implants.

### References

1. Leffingwell CM. Autogenous tooth transplantation: a therapeutic alternative. *Dent Surv* 1980; 56(2):22-3:26.
2. Cohen AS, Shen TC, Pogrel MA. Transplanting teeth successfully: autografts and allografts that work. *J Am Dent Assoc* 1995; 126(4):481-5.
3. Pogrel MA. Evaluation of over 400 autogenous tooth transplants. *J Oral Maxillofac Surg* 1987;45(3):205-11.
4. Hale ML. Autogenous transplants. *Oral Surg Oral Med Oral Pathol* 1956; 9:76-83.
5. Sunil Kumar, C Mohan, B Lakshminarayan. Autogenous tooth transplantation –Two clinical cases. *Endodontology* 2001;13.
6. Nethander G. Periodontal conditions of teeth autogenously transplanted by a two-stage technique. *J Periodontal Res* 1994; 29(4):250-8.
7. Kugelberg R, Tegsjo U, Malmgren O. Autotransplantation of 45 teeth to the upper incisor region in adolescents. *Swed Dent J* 1994; 18(5):165-72.
8. Andreasen JO, Paulsen HU, Yu Z, Bayer T, Schwartz O. A long-term study of 370 autotransplanted premolars. Part II. Tooth survival and pulp healing subsequent to transplantation. *Eur J Orthod* 1990; 12(1):14-24.
9. Kristerson L, Lagerstrom L. Autotransplantation of teeth in cases with agenesis or traumatic loss of maxillary incisors. *Eur J Orthod* 1991; 13(6):486-92.
10. Cameron M.L. Clokie, Deirdre M. Yau, Laura Chano, *Journal de l'Association dentaire canadienne. J Can Dent Assoc* 2001; 67:92-6.
11. B.E. Edetanlen, C.C. Azodo, P.E. Egbor, O. Akpata. Autogenous tooth transplantation in adult orofacial Autogenous tooth transplantton in adult orofacial cleft deformity:A case. *Benin J Postgraduate Med* 2009;11.
12. Lundberg T, Isaksson S. A clinical follow-up study of 278 autotransplanted teeth. *Br J Oral Maxillofac Surg* 1996; 34(2):181-5.
13. Schwartz O, Bergmann P, Klausen B. Autotransplantation of human teeth: a life table analysis of prognostic factors. *Int J Oral Surg* 1985; 14(3):245-58.
14. Robinson PJ, Grossman LI. Tooth Transplantation. In: Robinson PJ, Guernsey LJ, eds. *Clinical transplantation in dental specialties*. St. Louis: C.V. Mosby Co.; 1980. p. 77-88.

Source of support: Nil

Conflict of interest: None declared