

# Original Article

## Clinico- pathological Analysis of 68 cases of Ameloblastoma- A Retrospective Study

Namrata Punit Awasthi<sup>1</sup>, Poonam Singh<sup>2</sup>

<sup>1</sup>Assistant Professor, Department of Pathology, Dr Ram Manohar Lohia Institute of Medical Sciences, Lucknow, U.P.,

<sup>2</sup>Clinical Pathologist, Shriswasti Hospital, Pvt. Ltd., Pilibhit

### Corresponding author:

Dr. Poonam Singh

Clinical Pathologist, Shriswasti  
Hospital, Pvt. Ltd., Pilibhit, U.P.,  
India

**Received:** 20-04-2013

**Revised:** 14-05-2013

**Accepted:** 22-06-2013

### ABSTRACT:

**Background:** The ameloblastoma is a benign odontogenic tumor solely derived from an odontogenic epithelial origin, and it alone accounts for around 23% of odontogenic tumors. The present study was conducted to correlate the recurrence rates of benign ameloblastoma to the inherent nature of different clinic-pathological subtypes. **Materials & Methods:** This retrospective study included 68 treated cases of ameloblastoma. General information such as name, age, gender, anatomic location and histologic subtype were evaluated. Benign ameloblastoma were divided into: unicystic ameloblastoma (UA), solid/multicystic ameloblastoma (SMA), and desmoplastic ameloblastoma based on WHO (2005) classification. This was based on histopathological evaluation of tissue sections stained with hematoxylin and eosin stains. The solid variant was further subdivided into the follicular and plexiform variants. **Results:** Out of 68 cases of ameloblastoma, males were involved in 45 cases and females in 23 cases. The difference was significant ( $P < 0.05$ ). Most commonly seen variety was follicular (24) followed by unicystic (20), plexiform (13) and desmoplastic (11). Most cases were involving right posterior mandible (30) followed by left posterior mandible (19), right & left posterior mandible together (7), anterior mandible (5), posterior maxilla (4) and anterior maxilla (3). The difference was significant ( $P < 0.05$ ). Most common variant seen was follicular which showed recurrence. Most common site was left posterior mandible. Male predominated in recurrence cases. **Conclusion:** Follicular variety was commonly showed recurrence and posterior mandible predominance was seen. Male predominance was observed in this study. **Key words:** Ameloblastoma, Follicular, Plexiform.

This article may be cited as: Awasthi NP, Singh P. Clinico- pathological Analysis of 68 cases of Ameloblastoma- A Retrospective Study. J Adv Med Dent Sci Res 2013;1(1):79-81.

### INTRODUCTION

Ameloblastoma is a rare, benign or cancerous tumor of odontogenic epithelium (ameloblasts, or outside portion, of the teeth during development) much more commonly appearing in the lower jaw than the upper jaw. It was recognized in 1827 by Cusack. This type of odontogenic neoplasm was designated as an adamantinoma in 1885 by the French physician Louis-Charles Malassez. It was finally renamed to the modern name ameloblastoma in 1930 by Ivey and Churchill.<sup>1</sup>

According to the World Health Organization (WHO 2005), the ameloblastoma is a benign odontogenic tumor solely derived from an odontogenic epithelial origin, and it alone accounts for around 23% of odontogenic tumors. Based on these studies, histologically similar and related tumors, namely, the adamantinoma of long bones and the craniopharyngioma are now considered unrelated.<sup>2</sup>

This lesion causes massive expansion of the jaw bones involving both bony cortical plates, resulting in gross asymmetry of the face, occlusal derangement and at times cortical plate perforation and pain due to secondary infection. The treatment of choice follows a radical surgical approach encompassing wide resection procedures of the jaw such as marginal, segmental, and composite resections. Recurrence rates following such morbid surgical procedures have been estimated to be as high as 50% of all surgically treated cases. The reason for such a high rate of recurrence is multifactorial; therefore, it is imperative to evaluate every case for recurrence risk parameters before formulating a surgical treatment plan.<sup>3</sup>

Ameloblastomas are often associated with the presence of unerupted teeth. Symptoms include painless swelling, facial deformity if severe enough, pain if the swelling impinges on other structures, loose teeth, ulcers, and periodontal disease.

Lesions will occur in the mandible and maxilla, although 75% occur in the ascending ramus area and will result in extensive and grotesque deformities of the mandible and maxilla. In the maxilla it can extend into the maxillary sinus and floor of the nose.<sup>4</sup> The present study was conducted to correlate the recurrence rates of benign ameloblastoma to the inherent nature of different clinic-pathological subtypes.

### MATERIALS & METHODS

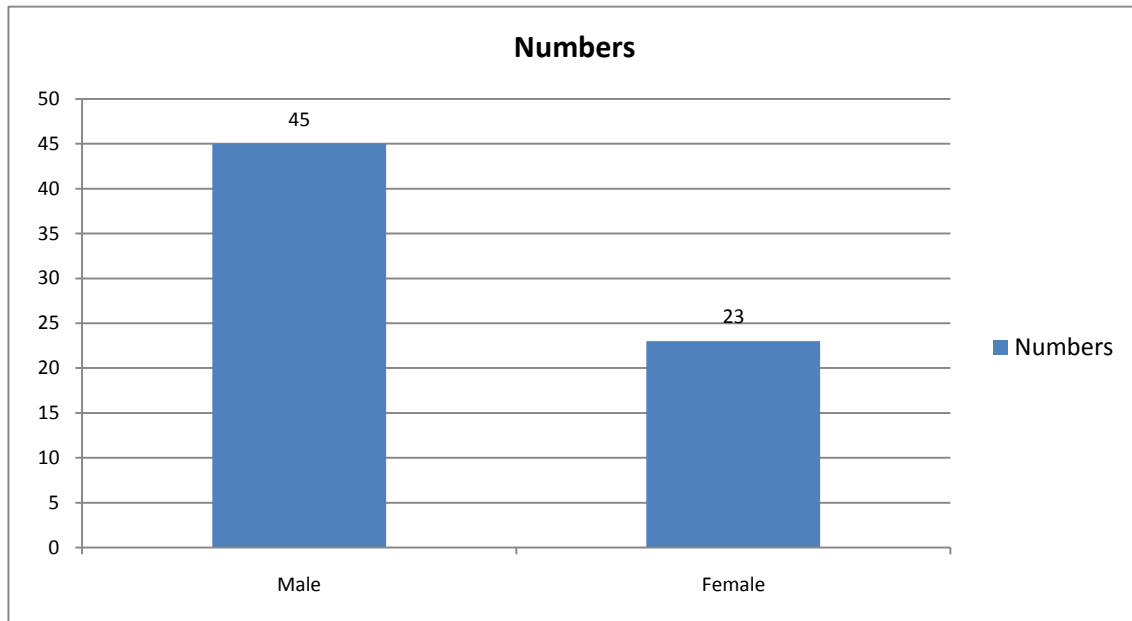
This retrospective study was conducted in the department of general pathology. It included 68 treated cases of ameloblastoma. General information such as name, age, gender, anatomic location and histologic subtype were evaluated.

Benign ameloblastoma were divided into: unicystic ameloblastoma (UA), solid/multicystic ameloblastoma (SMA), and desmoplastic ameloblastoma based on WHO (2005) classification.

This was based on histopathological evaluation of tissue sections stained with hematoxylin and eosin stains. The solid variant was further subdivided into the follicular and plexiform variants. Results were tabulated and subjected to statistical analysis using chi- square test. P value < 0.05 was considered significant.

### RESULTS

**Graph I** Distribution of cases



Graph I shows that out of 68 cases of ameloblastoma, males were involved in 45 cases and females in 23 cases. The difference was significant (P< 0.05).

### DISCUSSION

Ameloblastoma has a tendency to expand the bony cortices because slow growth rate of the lesion allows time for periosteum to develop thin shell of bone ahead of the expanding lesion. This shell of bone cracks when palpated and this phenomenon is referred to as "Egg Shell Cracking" or crepitus, an important diagnostic feature. Ameloblastoma is tentatively diagnosed through radiographic examination and must be confirmed by histological examination. Histopathology will show cells that have the tendency to move the nucleus away from the basement membrane. This process is referred to as "Reverse Polarization".<sup>5</sup> The follicular type will have outer arrangement of columnar or palisaded ameloblast like cells and inner zone of triangular shaped cells resembling stellate reticulum in bell stage. The central cells sometimes degenerate to form central microcysts. The plexiform type has epithelium that proliferates in a "Fish Net Pattern". The plexiform ameloblastoma shows epithelium proliferating in a 'cord like fashion', hence the name 'plexiform'. There are layers of cells in between the proliferating epithelium with a well-formed desmosomal junctions, simulating spindle cell layers.<sup>6</sup> The present study was conducted to correlate the recurrence rates of benign ameloblastoma to the inherent nature of different clinic-pathological subtypes.

**Table I** Distribution of histopathological variant

Subtypes	Ant. Max.	Ant. Mand.	Post. Max.	Rt post. Mand.	Left post. Mand.	Rt & left post. Mand.	P value
Unicystic		2		6	6	6	< 0.05
Follicular		2	1	13	7	1	
Plexiform	2	-	1	7	3		
Desmoplastic	1	1	2	4	3		
<b>Total</b>	<b>3</b>	<b>5</b>	<b>4</b>	<b>30</b>	<b>19</b>	<b>7</b>	

Table I shows that most commonly seen variety was follicular (24) followed by unicystic (20), plexiform (13) and desmoplastic (11). Most cases were involving right posterior mandible (30) followed by left posterior mandible (19), right & left posterior mandible together (7), anterior mandible (5), posterior maxilla (4) and anterior maxilla (3). The difference was significant ( $P < 0.05$ ).

**Table II** Recurrent cases based on clinicopathological parameters

Age/ gender	Variant	Primary site	Site after recurrence
32/f	Unicystic	Ant. Mand.	Ant. Mand.
50/M	Follicular	Left post. mand.	Left post. mand.
36/f	Follicular	Left post. mand.	Right post. Mand.
28/M	Follicular	Left post. mand.	Left post. mand.
60/M	Unicystic	Right post. mand.	Right post. mand.

Table II shows that most common variant seen was follicular which showed recurrence. Most common site was left posterior mandible. Male predominated in recurrence cases.

In this study, out of 68 cases, 45 were seen in males and 23 in females. Our results are in agreement with the results of Kim SG.<sup>7</sup> We found that most commonly seen variety was follicular followed by unicystic, plexiform and desmoplastic. Our results are in accordance to Hasegawa et al.<sup>8</sup> Most cases were involving right posterior mandible followed by left posterior mandible, right & left posterior mandible together, anterior mandible, posterior maxilla and anterior maxilla. Similar finding were seen in study of Shoor.<sup>9</sup>

Most commonly recurrence was observed in follicular type. Most common site was left posterior mandible. Male predominated in recurrence cases. This is in agreement with More C.<sup>10</sup> The high incidence and recurrent rate in the posterior quadrant can be explained by the presence of active odontogenic rests in the third molar region by virtue of it being the last tooth to erupt in both upper and lower jaws. The odontogenic cells rests within a neural crest cell derived ectomesenchyme can get activated due to reciprocal induction by aberrantly activated Sonic hedgehog (Shh) and the Wingless (Wnt) pathways. The third molars are considered rudimentary organs. The latent ligands such as bone morphogenetic protein and transforming growth factor beta (TGF- $\beta$ ) can get activated either due to hindered eruptive forces or inflammation caused due to an impacted third molar.<sup>11</sup>

## CONCLUSION

Male predominance was observed in this study. Follicular variety was commonly showed recurrence and posterior mandible predominance was seen.

## REFERENCES

- Di Cosola M, Turco M, Bizzoca G, Tavoulari K, Capodiferro S, Escudero-Castaño N, *et al.* Ameloblastoma of the jaw and maxillary bone: Clinical study and report of our experience. *Av Odontostomatol.* 2007; 23: 367-73.
- Naik BR. Clinicopathological study of ameloblastomas: Case study in tribal areas. *Int J Head Neck Surg.* 2011; 2: 1-4.
- Martins RH, Andrade Sobrinho J, Rapoport A, Rosa MP. Histopathologic features and management of ameloblastoma: Study of 20 cases. *Sao Paulo Med J.* 1999; 117: 171-4.
- Rastogi V, Pandilwar PK, Maitra S. Ameloblastoma: An evidence based study. *J Maxillofac Oral Surg.* 2010; 9:173-7.
- Deshmukh V, Patwa RS, Chhindam PB, Joshi N. An unusual case of bilateral unicystic ameloblastoma in third molar region. *J Dent Allied Sci.* 2012; 3: 99-101
- Milman T, Ying GS, Pan W, LiVolsi V. Ameloblastoma: 25 year experience at a single institution. *Head Neck Pathol.* 2010; 10:513-20
- Kim SG, Jang HS. Ameloblastoma: A clinical, radiographic, and histopathologic analysis of 71 cases. *Oral Surg Oral Med Oral Pathol Oral Radiol Endod.* 2001; 91: 649-53.
- Hasegawa T, Imai Y, Takeda D, Yasuoka D, Ri S, Shigeta T, *et al.* Retrospective study of ameloblastoma: The possibility of conservative treatment. *Kobe J Med Sci* 2013;59:E112-21.
- Shoor H, Pai KM, Gupta S, Garg A, Sharma H, Kumar N. Clinical, radiographic and histopathologic features of ameloblastoma: A retrospective analysis of 21 cases. *Int J Sci Stud* 2011; 2: 83-8.
- More C, Tailor M, Patel HJ, Asrani M, Thakkar K, Adalja C. Radiographic analysis of ameloblastoma: A retrospective study. *Indian J Dent Res.* 2012; 23:698.
- Hertog D, Bloemena E, Aartman IH, van-der-Waal I. Histopathology of ameloblastoma of the jaws; some critical observations based on a 40 years single institution experience. *Med Oral Patol Oral Cir Bucal.* 2012; 17: 76-82.

Source of support: Nil

Conflict of interest: None declared

This work is licensed under CC BY: *Creative Commons Attribution 3.0 License.*